

## **Microsurgical Approach in a Thoracic Meningioma in Elderly. Case Report**

**A.V. Ciurea, Al. Tascu, C.L. Palade**

University of Medicine and Pharmacy “Carol Davila” Bucharest  
1<sup>st</sup> Neurosurgery Clinic

“Bagdasar-Arseni” Clinical Hospital, 10-12 Berceni Street, 041915, Bucharest

Correspondence to: claudiu\_palade@yahoo.com, rsneurosurgery@gmail.com

### **Abstract**

Improved results in the treatment of intraspinal tumors have followed greater sophistication of diagnostic modalities and surgical techniques. Whereas originally tumors could be diagnosed radiologically only by bone erosion seen on radiographic films, now myelography, computed tomography (CT) and magnetic resonance imaging (MRI) provide precise localization. Indeed, MRI is a stand-alone diagnostic preoperative study for virtually all intradural tumors. With the advent of the operating microscope, microsurgical instruments, bipolar cautery and intraoperative ultrasonography, combined with ultrasonic cavitation devices and other techniques, surgeons can approach these tumors with greater ease.

**Keywords:** intradural spinal tumor, meningioma, neurosurgical results

### **Introduction**

In the literature, spinal meningiomas account for 25-46% of spinal tumors, with 7,5-12,7% of all meningiomas occurring in the spinal canal.

The arachnoid cap cells or immature fibroblasts of the dura are considered to be the tumor precursor cells of meningiomas. Most meningiomas are found entirely intradurally. However, transdural growth or entirely extradural growth is also possible. Invasive growth or hyperostotic reaction of the bone is rare. The tumor attachment is often lateral with a ventral or dorsal extension. Meningiomas are observed predominantly in the cervical (28%) and thoracic spine (64%). Lumbar

meningiomas are rare (8%). They are evenly distributed around the spinal cord and may be located anteriorly (26%), posteriorly (25%), or laterally (48%). In the cervical area, anterior meningiomas are more common than in the thoracic spine (47% and 18%, respectively), whereas most of the thoracic meningiomas are located laterally compared to the cervical area (55% and 38%, respectively). In the lumbar region, 55% were located posteriorly.

The ratio of spinal to intracranial meningiomas is about 1:8; the mean age at presentation is 56 years. Multiple spinal meningiomas are rare. Due to the predilection for the thoracic location and

functional adaptability of the spinal cord, clinical symptoms are very insidious.

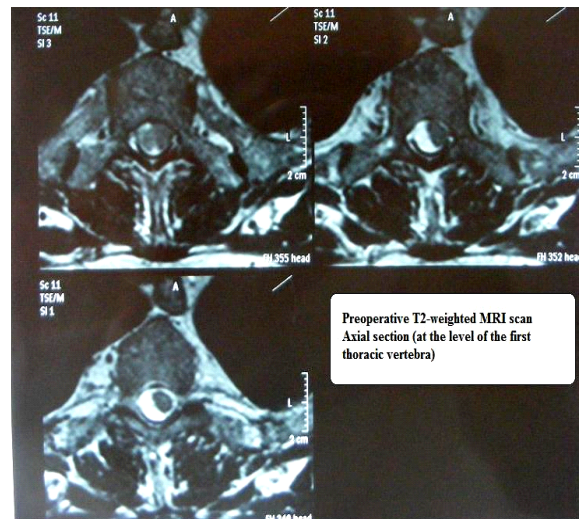
A complete removal of spinal meningiomas is achieved in the vast majority of cases, with a recurrence rate of less than 10%.

**Case Report**

A 74 year old male noticed gait disturbance of gradual onset with motor weakness of the inferior limbs (Frankel score=D) and a sensory impairment below the level of T9, without sphincter disturbances.

Since 3 months previously, he had suffered from progressive thoracic pain. Since 1 month previously the thoracic back pain had worsened associated with paresthesias in both legs, more on the right side.

The MRI scan presented an intradural-extramedullary tumor on the right side at thoracic level T1-T2, with severe compression of the spinal cord.

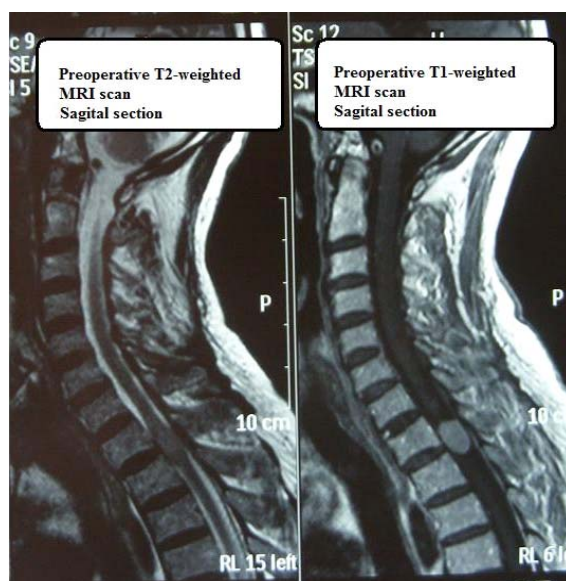

**Figure 1 Preoperative MRI scan (in sagittal and axial incidence) showing intradural extramedullary tumor**

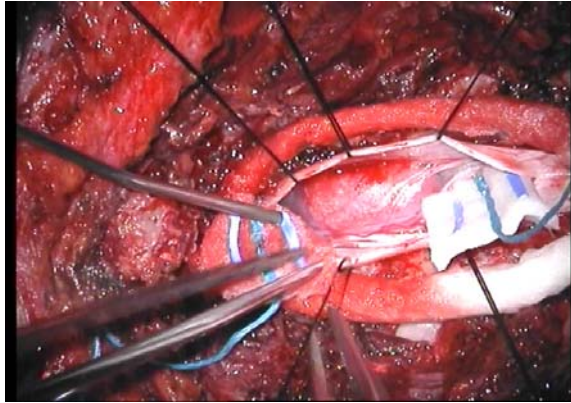
A laminectomy at two levels (T1 and T2) was performed and a meningioma (WHO grade I) was totally removed. The sensory roots at the level were completely preserved.

The operation was performed with general anesthesia. Central venous access and arterial pressure monitoring are helpful. The operation was performed with the patient in the prone position. All pressure points were well-padded. A comfortable head rest is essential. For patients with upper thoracic or cervical tumors, three-point skull fixation with the cervical spine in neutral position is best.

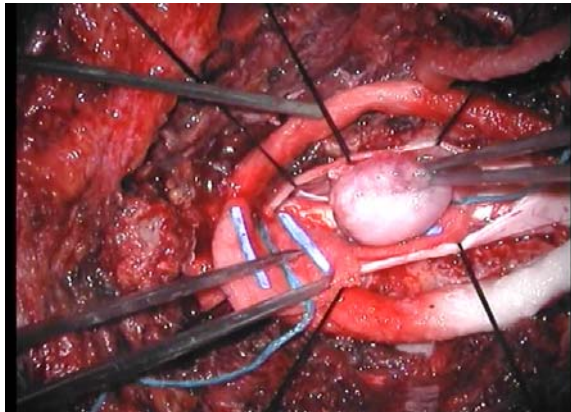
Prior to preparation and draping, anterior-posterior roentgenograms were obtained in this case, in order to best localize the lesion. Alternatively, the patient may be taken to the radiology department prior to surgery, where fluoroscopy can be employed to localize these lesions relative to surface anatomy. Although intraoperative evoked potential



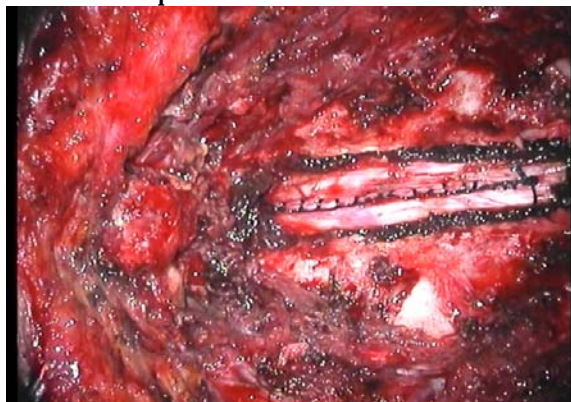monitoring may be beneficial in some cases, intradural extramedullary tumors can be resected safely without this additional monitoring.



**Figure 2 A** Exposure of the posterior medullar surface at T1-T2 level



**Figure 2 B** Tumor dissection and decompression of the medullar stem



**Figure 2 C** Reapproximation of the dura mater after gross total removal

After preparation and draping, a midline incision was employed and the fascia was incised down to the spinous processes. The muscular attachments were stripped bilaterally in the subperiosteal plane, exposing the laminae out to the facet joints. The spinous processes and laminae of the 1<sup>st</sup> and 2<sup>nd</sup> thoracic vertebrae were carefully removed using bone rongeurs. Enough bone was removed both above and below the tumor to permit an adequate dural opening.

At this point, the operating microscope was brought into the field. The dura was opened in the midline, taking care to preserve the arachnoid intact. A microdissector was used to separate the dura and arachnoid. Dural tack-up sutures were placed and cottonoid pledgets were laid over the exposed dura. Tension on the sutures provides better exposure and relative hemostasis from the epidural space. The tumor was already visible beneath the arachnoid.

The arachnoid was carefully opened by sharp dissection. The tumor was dissected within the tumor-cord interface. The plane between the tumor and the spinal cord was well-developed and easy to delineate, allowing circumferential arachnoid dissection and delivery of the tumor capsule.

Meticulous hemostasis is essential prior to dural closure. A watertight closure followed. Muscle, fascia and subcutaneous tissue were closed in anatomic layers. An external drain was used. The skin was finally closed and a sterile gauze was placed above.

Perioperative antibiotic prophylaxis, careful wound closure, and dexamethasone administration lessen the risks of postoperative infection and cerebrospinal fluid leakage.

The drain was discontinued the next day.

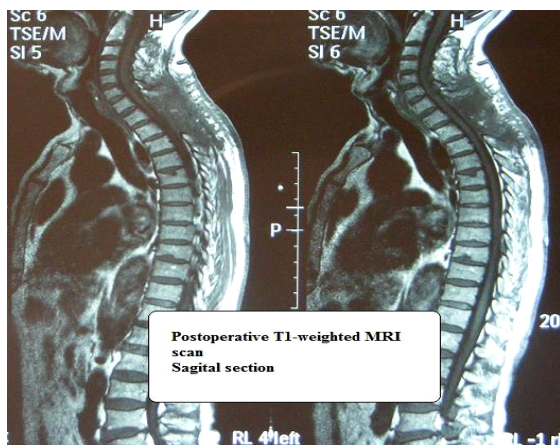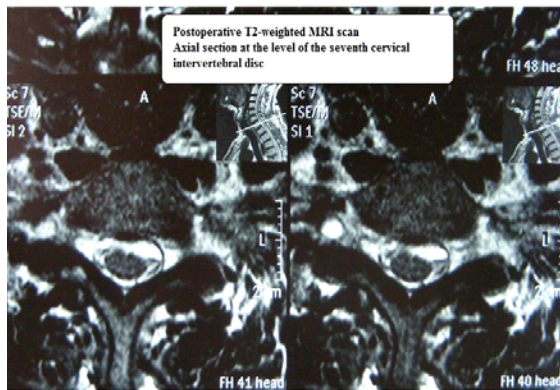

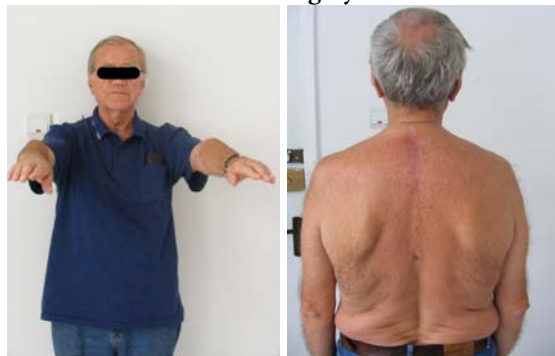
Figure 3 Postoperative MRI scan ,1 month after surgery



The postoperative sagittal MRI scan of the thoracic region demonstrated tumor removal and the contour of the spinal cord without any signs of compression. Two days after surgery the motor weakness of the lower extremity was improved, and the sensory impairment diminished considerably.

### Discussion

The key feature of slowly growing tumors is the long history of signs and symptoms due to the substantial plasticity of the spinal cord. Acute onset with a subarachnoid hemorrhage can also be a rare presentation of spinal cord tumors (such as neurinomas and cavernous angiomas).

The signs and symptoms differ, depending on: level, location, size of tumor and speed of growth

Among patients with meningiomas, four groups can be distinguished

according to the growth pattern and histology of the tumor: encapsulated, en plaque growing, atypical, and malignant meningiomas. With encapsulated meningiomas, the preoperative history is almost twice as long as compared to the remaining groups. Of patients with encapsulated meningiomas, the vast majority (72%) complain about gait and motor deficits as their major concern at the time of surgery. With en plaque growing tumors, the situation is quite different, as pain and disesthesias become more predominant (45%). With atypical meningiomas, 71% are mainly concerned about pain and disesthesias, while 29% are disabled by gait problems. With malignant meningiomas, 50% are troubled by pain, and the other half by gait ataxia.

In general, extramedullary tumors produce radicular and segmental deficits. The above tumors reveal long tract symptoms and signs in their advanced stage. Lateralization or asymmetry of early signs and symptoms reflects the lateral location of a tumor. Hemicord syndrome or Brown-Sequard's syndrome is observed commonly at the advanced stage.

The cardinal symptoms are: progressive local pain, pain during recumbency (nocturnal pain), radicular or mielopathic pain, non-painful sensory disturbances, motor weakness (gait disturbance), clumsiness and ataxia, sphincter disturbances (usually urogenital, less commonly anal)

The pain might be of the radicular type, with radiation often increasing with Valsalva's maneuver and/or spine movement. Segmental or medullary pain (non-radicular, diffuse non-describable pattern) might be present continuously,

radiating into the whole leg or one-half of the body without affection of movement.

A thorough neurological examination is key to the assessment of spinal tumors. Findings on clinical examination include: sensory deficits, motor weakness, gait disturbance, ataxia, bowel and bladder dysfunction, torticollis and spinal deformity (scoliosis and kyphosis)

### **Diagnostic modalities**

1. Magnetic resonance imaging - the golden standard

Magnetic resonance imaging should be performed as the first diagnostic modality when symptoms and signs indicate a spinal tumor should be suspected. The other imaging modalities are second in line.

MRI is the diagnostic imaging procedure of choice. T1W – and T2W-weighted images as well as gadolinium-enhanced T1W images should be systematically obtained. The entire spinal cord must be studied.

At least two different imaging planes should be used in order to locate the tumor properly and to differentiate intramedullary tumors from extramedullary tumors. Coronal sections can demonstrate a tumor in relation to the bony structures in the same view as in the operating room, which can be helpful in planning the extent of laminectomy.

Meningiomas present as isointense with cord on T1W images and T2W images; moderate contrast enhancement with or without association of dural tail; there is no bone destruction; calcification is occasional.

2. CT and Myelo-CT

These are the methods of choice in patients in whom MRI cannot be performed because of contraindications (e.g., pacemaker).

Typical findings are: bony deformation such as destruction, scalloping, widening of the spinal canal and/or the intervertebral foramen, calcification, contrast enhancement, spinal cord compression.

### **Surgical treatment**

The goal of surgery for any benign intradural neoplasm is gross total resection. Recent technological developments such as MRI, ultrasonography, the cavitron ultrasound aspirator (CUSA), and microsurgical technique with intraoperative neurophysiological monitoring have brought about a remarkable improvement in surgical results.

The target level should be marked under the fluoroscope prior to surgery.

Extension of laminectomies should be one more lamina above and below tumor extension. This enables surgical manipulation to be easy and safe and is also appropriate for decompression. If benign extramedullary tumors are found, osteoplastic laminotomy might also be considered to prevent traction damage or kyphosis. Care should be taken at least to maintain the integrity of the facets to preserve spinal stability.

Intraoperative neurophysiological monitoring with somatosensory evoked potentials (SSEPs) is recommended. There is no convincing reliable and useful monitoring system which includes motor evoked potentials at the moment.

Knowledge of standard peri- and intraoperative management such as:

edema prevention, respiratory management in cervical tumors, critical interpretation of neurophysiological monitoring, is key to successful surgery.

Possible surgical complications include: bladder and bowel dysfunction, bleeding or hematoma, CSF leak, infection, chronic pain, neurological deterioration, sexual dysfunction, spinal instability, ventilator dependence, wound dehiscence

In terms of outcome, postoperative neurological morbidity in the surgery of extramedullary tumors is usually less than 15%. Total recurrence rate of meningiomas is 7-15%. Neurological function of a patient after surgical intervention mostly depends on his or her preoperative neurological condition.

Surgical approach for intradural extramedullary tumors

Localization of intradural extramedullary tumors can be classified as: posterior, posterolateral, lateral, anterolateral, anterior.

Although most tumors can be managed by standard laminectomy, the approach can be varied accordingly such as by using: hemilaminectomy and complete laminectomy, costotransversectomy, extracavitary approach, far lateral laminectomy and partial facetectomy, posterolateral approach through the facet joint and pedicle, transthoracic approach, far lateral approach transcondylar approach for tumors at the cervicomedullary junction, ventral corpectomy.

Almost all meningiomas can be completely removed, with excision or coagulation of the dural attachment. The recurrence rate following complete resection is around 7-15%. There is no

clear correlation between the result and the extent of resection of the dural attachment. The surgical approach is usually via a laminectomy for midline dorsal tumors. A hemilaminectomy can sometimes be performed in small tumors more laterally located. For tumors in a lateroventral location, a lateral approach has to be performed.

### Conclusions

1. The use of spinal MR imaging, with extremely accurate details, provides the most useful and dependent diagnostic tool

2. The surgical approach is usually via a laminectomy for midline dorsal tumors. A hemilaminectomy can sometimes be performed in small tumors more laterally located.

3. The modern operating microscope provides an outstanding illumination and magnification of the operating field and allows a very careful and gentle tumor dissection and removal

4. The use of the intraoperative “C-arm” Roentgen equipment is extremely beneficial, allowing a very exact localization of the lesion

5. Knowledge of peri-and intraoperative management such as: edema prevention and respiratory management in cervical tumors is key to succesful surgery.

### References

1. Ciapetta P, Domenicucci M, Raco A (1988) Spinal meningiomas: prognosis and recovery factors in 22 cases with severe motor deficits. *Acta Neurol. Scand* 77:27-30
2. Ciurea AV, Constantinovici A (1998) Tumorile Spinale. In: Ciurea AV, Constantinovici A Ghid practic de neurochirurgie, Editura Medicala, Bucuresti, p 341
3. Cohen-Gadol AA, Zikel OM, Koch CA, Scheitauer BW, Krauss WE (2003) Spinal meningiomas in patients

- younger than 50 years of age: a 21-year experience. *J Neurosurg (Spine3)* 98: 258-263
4. El-Mahdy W, Kane PJ, Powell MP, Crockard HA (1999) Spinal intradural tumours: Part I – extramedullary. *Br J Neurosurg* 13:550-557
5. Feiring EH, Barron K (1962) Late recurrence of spinal cord meningioma. *J Neurosurg* 19:652-656
6. Gamache FW Jr, Wang JC, Deck M, Heise C (2001) Unusual appearance of an en plaque meningioma of the cervical spinal canal: a case report and literature review. *Spine* 26:E87-E89
7. Gambardella G, Gervasio O, Zaccone C (2003) Approaches and surgical results in the treatment of ventral thoracic meningiomas. Review of our experience with a postero-lateral combined transpedicular-transarticular approach. *Acta Neurochir (Wien)* 145:385-392
8. Gezen F, Kahraman S, Canakci Z, Beduk A (2000) Review of 36 cases of spinal cord meningioma. *Spine* 25:727-731
9. Goldhahn WE, Schmidt U (1989) Das spinale Meningiom. *Zentralbl Neurochir* 50:18-23
10. Gottfried ON, Gluf W, Quinones-Hinojosa A, Kan P, Schmidt MH (2003) Spinal meningiomas: surgical management and outcome. *Neurosurg Focus* 14: Article 2
11. Herkowitz H, Garfin S, Eismont F, Bell G, Balderston R (2006). In: Rothman-Simeone *The Spine*, Elsevier
12. Klekamp J, Sammi M (2007) Extramedullary Tumors. In: Klekamp J, Sammi M (eds) *Surgery of Spinal Tumors*, Springer - Verlag, Berlin-Heidelberg, pp 248-260
13. McCormick PC, Post KD, Stein BM (1990) Intradural extramedullary tumors in adults. In: Stein BM, McCormick PC (eds) *Neurosurgery Clinics in North America*. Vol.1 no.3. *Intradural Spinal Surgery*. WB Saunders, Philadelphia, pp591-608
14. McCormick PC, Stein BM (1996) Spinal cord tumours in adults. In : Youmans JR (ed) *Neurological Surgery*, 4th edn. Saunders, Philadelphia, pp 3102-3122
15. Morandi X, Haegelen C, Riffaud L, Amlashi S, Adn M, Brassier G (2004) Results in the operative treatment of elderly patients with spinal meningiomas. *Spine* 29: 2191-2194
16. Schick U, Marquardt G, Lorenz R (2001) Recurrence of benign spinal neoplasms. *Neurosurg Rev* 24: 20-25
17. Solero CL, Fornari M, Giombini S, Lasio G, Oliveri G, Cimino C, Pluchino F (1989) Spinal meningiomas: review of 174 operated cases. *Neurosurgery* 25: 153-160
18. Souweidane MN, Benjamin V (1994) Spinal cord meningiomas. *Neurosurg Clin N Am* 5:283-291
19. Yonekawa Y, Marugg R (2008) Intradural Tumours. In: Boos N, Aebi M (ed) *Spinal Disorders – Fundamentals of Diagnosis and Treatment*, Springer - Verlag, Berlin Heidelberg, pp 997-1019