

Giant atypical posterior fossa meningioma revealed by rhinorrhea

G. Iacob¹, Dana Paula Georgescu², Mihaela Poparda³,
M. Craciun¹, L. Nicolae¹

¹Clinic of Neurosurgery, University Hospital Bucharest Romania

²Clinic of Neuroradiology, University Hospital Bucharest Romania

³Neuropathology Clinic, University Hospital Bucharest Romania

Abstract

Objective and importance: Cerebral supra or infratentorial tumors associated with chronic intracranial hypertension and hydrocephalus may rarely generate spontaneous, non-traumatic rhinorrhea. We report one case of this rare condition with a giant atypical left posterior fossa meningioma and right nostril rhinorrhea.

Clinical presentation: A 55-years-old woman was admitted for a 16-year history of headache, 1-year of right nostril rhinorrhea, which was exacerbated when the patient was standing or when she bent forward, ataxia, astasia-abasia. Spontaneous rhinorrhea (no previous history of head trauma or meningitis) stopped suddenly a few days before admission, while cephalgia increased and her general condition worsened. Native and contrast CT scan disclosed a giant extraaxial tumor: 7/9/8 cm, developed in the left posterior fossa, but also active, internal, supratentorial hydrocephalus. The anterior recess of the third ventricle was dilated; with a small discontinuity of the right sphenoid sinus.

Intervention: The microsurgical resection of the tumor mass was subtotal, as confirmed by postop CT scan, induced by cardiac rhythm fluctuation and tensional oscillations. After the operation the patient

became free of CSF leakage and a direct approach for rhinorrhea was not needed.

Conclusion: A case of non-traumatic spontaneous rhinorrhea generated by a giant atypical left posterior fossa, atypical meningioma is described. Using microsurgical resection, the tumor was subtotally removed, the patient improved and rhinorrhea didn't recur.

Keywords: spontaneous rhinorrhea, posterior fossa meningioma, atypical meningioma

Cerebrospinal fluid rhinorrhea usually occurs after (1-4):

- trauma (fracture the anterior skull base, fracture of the petrous temporal bone in the presence of an intact tympanic membrane; in which CSF in the middle ear drains to the nose),

- developmental defects of the ethmoid, sphenoid, frontal, petrous bones with the formation of a meningocele or meningoencephalocele with intact tympanic membrane

- iatrogenic causes: sequel of skull-base surgery, endoscopic sinus surgery, transsphenoidal pituitary surgery, translabyrinthine acoustic schwannoma and mastoid surgery with intact tympanic membrane,

- destructive skull base lesions including neoplasms both benign and malignant
- empty sella
- radiation therapy.

Spontaneous rhinorrhea is seldom found in brain tumor, before treatment, when the dura and skull base bone are eroded by the tumor directly or by progressive chronic obstructive hydrocephalus induced by tumor development (5-7). In this second condition spontaneous rhinorrhea is generated under chronic high pressure by weakness of the arachnoid sheath accompanying the pituitary gland stalk or by lack of bone support under the diaphragma sellae (5). We present such a case, with a huge meningioma of the left posterior fossa.

Case Report

On January 2, 2010, a 55-years-old woman was admitted to our hospital with a 16-year history of headache, 1-year of right nostril rhinorrhea that was exacerbated when the patient was standing or when she was bending forward, ataxia, astasia-abasia. One year earlier, based on cerebral CT scan, the patient had been diagnosed with a giant left posterior fossa tumor, secondary hydrocephalus and non-traumatic rhinorrhea in another institution, but refused operation. One week before admission spontaneous right nostril rhinorrhea stopped suddenly, cephalgia increased and her general condition worsened. She denied any history of head trauma or meningitis.

Her physical examination showed: an obese - 115 kg woman, light nuchal stiffness, marked ataxia, dysarthria, decreased visual acuity in both eyes, left facial paralysis and hypoacusia, gr. II horizontal nystagmus, bilateral Babinski

sign, no motor deficit. Her mental status was alert. No rhinorrhea was remarked at admission, even when the patient leaned forward. Ophthalmologic examination was normal: visual acuity, campimetry, fundus oculi.

Native and contrast CT scan (Figure 1) revealed a giant extraaxial tumor: 7/9/8 cm, developed in the left posterior fossa which is entirely occupied, in contact with the left mastoid cells, extended over the median line and cranially over the temporal bone, pulling up the tentorium, with severe mass effect on the brain stem. The tumor had important parietal calcifications, even calcar septa; the tissular component didn't enhance much with contrast. In the supratentorial compartment, there was an active internal hydrocephalus with transependymal resorption signs presented to the temporal horns of the ventricular system. The anterior recess of the third ventricle was dilated; with a small discontinuity of the right sphenoid sinus. A median shift of 1 cm to the right at the level of third ventricle was described.

On the 4th hospital day the tumor was operated. A combined middle fossa-retrolabyrinthine approach, with the patient in the supine position, with head turned 45° towards right side was performed. The tumor surface was nodular, with soft consistence, red-grayish, highly vascular.

The left posterior fossa tumor extended from foramen magnum up to the tentorium which was pushed upward. Using microsurgical technique the tumor was subtotally resected, less a tumor remnant adherent to the brainstem and tentorium (Simpson D resection) because of cardiac rhythm fluctuation and tensional oscillations reasons.

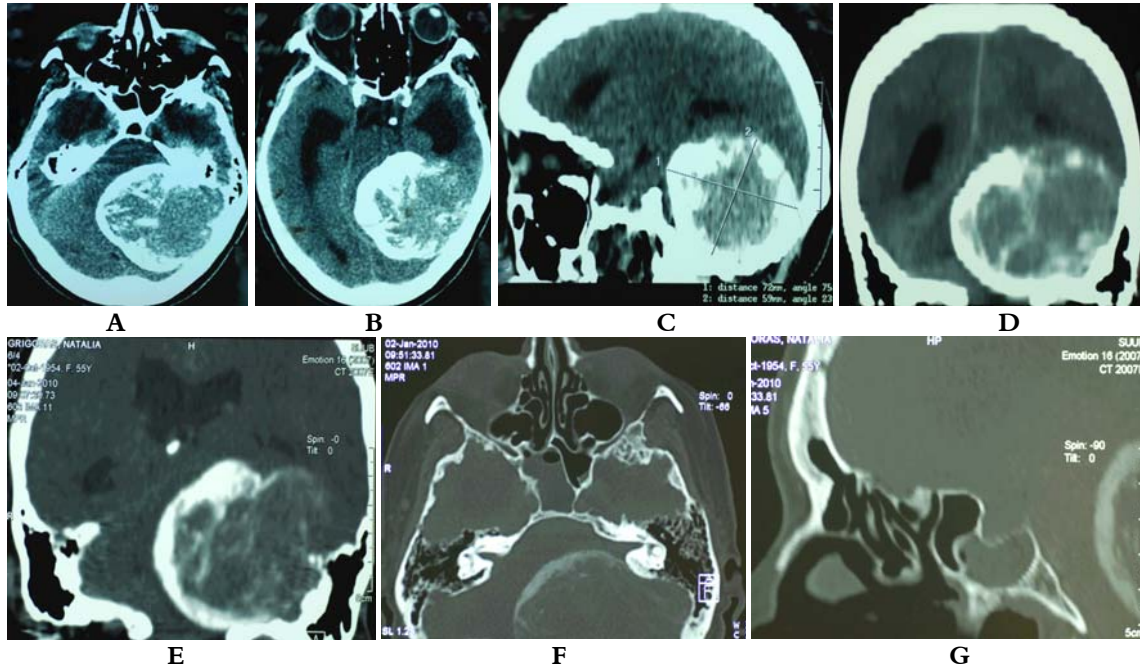


Figure 1 Cerebral CT scan: **A-E** a giant extraaxial tumor: 7/9/8 cm, developed in the left posterior fossa which is entirely occupied, in contact with the left mastoid cells, extended over the median line and cranially over the temporal bone, pulling up the tentorium, with severe mass effect on the brain stem. The tumor is native hyperdense, with important parietal calcifications, even calcar septa; also a large area of implantation on posterior fossa dura; **F-G** a small discontinuity of the right sphenoid sinus was discovered (white arrow) explaining right nostril rhinorrhea, induced by progressive chronic obstructive hydrocephalus liated to tumor development

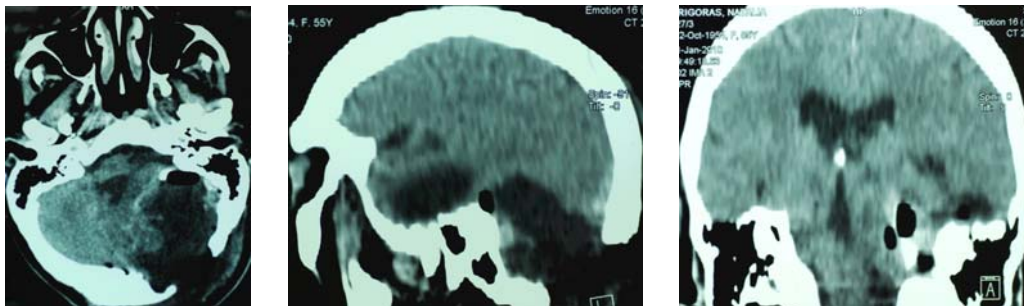


Figure 2 Postoperative CT scan: small tumor remnant, adherent to the brainstem and tentorium

Postoperative evolution was uneventful, without any recurring rhinorrhea, aspect confirmed by postoperative CT scan (Figure 2). The patient was discharged on the 7th postoperative day neurologically improved and without any cerebrospinal fluid leakage.

The pathology of the tumor was atypical meningioma - grade II (Figure 3), diagnosis

sustained on (8): increased mitotic activity - 4 or more mitoses/10 high-power fields (40x) or 3 or more of the following histologic features: increased cellularity, small cells with a high nuclear/cytoplasmic ratio, prominent nucleoli, uninterrupted patternless or sheet-like growth, foci of necrosis. The tumor has also several calcifications.

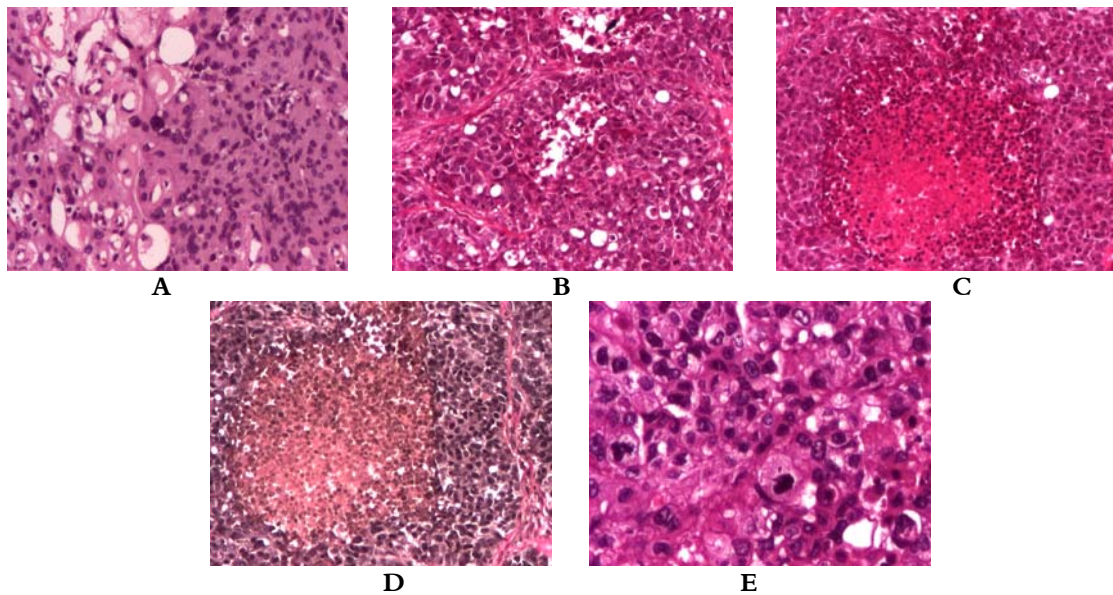


Figure 3 Atypical meningioma - grade II: A cellular atypia (HE×10), B cellular polymorphism (HE×10), C necrosis area (HE×10), D necrosis area (VG×10), E atypical mitosis (HE×40)

4 weeks after operation the patient was alert, with little ataxia. We recommended postoperative radiation therapy for two reasons: tumor pathology - the already mentioned criteria have been shown to correlate with 8-fold higher recurrence rates especially mitose and an elevated MIB-1 index are often present in perinecrotic regions, necrosis usually occurs as small foci, sometimes surrounded by pseudopalisading (9) and the extent of surgical resection.

Discussion

The term “spontaneous” cerebrospinal fluid leak was used as a clinical entity by Miller in 1826 (10), referring to a nontraumatic cerebrospinal fluid fistula. In 1899 Thompson (11) described a similar case. In 1947 Coleman and Trolard - cited by (12) identify 14 cases. O’Connell in 1953 (13) subdivided this condition in “primary spontaneous” or “idiopathic” CSF leak when no cause could be found identifying

over 75 cases in 1964 and “secondary spontaneous” fistula when a cause, usually a tumor was discovered or an anatomical defect which made the cribriform plate particularly vulnerable to the variations in the pressure of CSF.

Later Paillas – cited by (12) made a classification into congenital spontaneous fistula and medical fistula induced by tuberculous meningitis or pituitary adenoma with sella turcica erosion.

Ommaya 1968 (14) on certain 82 cases found in literature suggested that it would be more accurate the term “non-traumatic” cerebrospinal fluid fistula which could be subdivided into high pressure and normal pressure categories.

Rovit 1969 (15) on four cases identified high pressure CSF rhinorrhea due to benign circumscribed mass lesions obstructing CSF flow at the foramen of Monro and obstructive hydrocephalus secondary to a parieto-occipital meningioma.

In 1978 Oblu, Ianovici (12) identified several causes of non traumatic spontaneous cerebrospinal fluid leak:

- congenital: anterior skull base congenital defects especially to lamina cribrosa with or without meningoencephaloceles, craniostenosis (Crouzon disease, oxycephaly), Arnold Chiari syndrome, hydrocephalus by congenital Sylvius aqueduct stenosis

- tumoral: by direct mechanism (bone defect generated by compression or infiltration) or indirect mechanism (intracranial hypertension with internal hydrocephalus): pituitary, fourth ventricle a.s.o.

- infectious - parasitic diseases: sinus infections with osseous osteitis, tuberculous meningitis, osteomyelitis

- vascular: ethmoidal vessels thrombosis
- empty sella syndrome

Spontaneous CSF rhinorrhea are less than 5% (12). Cerebral tumors both supra or infratentorial may generate rhinorrhea as: parieto-occipital meningioma (16), tentorial meningioma (5), posterior falx meningioma (17), exophytic choroid plexus papilloma of the fourth ventricle (18), fourth ventricle ependymoma (19), macroprolactinomas (20), colloid cyst (21) a.s.o.

A remote tumor as in our case a giant, atypical, left, posterior fossa meningioma could be revealed by rhinorrhea. Second most common posterior fossa tumor after acoustic neuroma, posterior fossa meningioma are a very uncommon tumor group as compared to supratentorial meningiomas, representing 9-10% of all intracranial meningiomas (22), with multiple possible topography: cerebellar convexity, cerebello-pontine angle, tentorial, jugular foramen, petroclival,

foramen magnum, IV ventricle, unclassified. The vast majority of these tumors present with an insidious onset of symptoms; for large tumors that compress the brain stem structures or the 4th ventricle, as in our case, ataxia, hydrocephalus or multiple cranial nerve palsies are the most common symptoms. Frequently these tumors are discovered incidentally after brain imaging for other reasons. In our case the patient had a 16-year history of headache, 1-year of right nostril rhinoliquorrhea, without previous head trauma or meningitis. Diagnosis was made on clinical and cerebral CT grounds one year before, in another institution, but the patient refused operation. A giant left posterior fossa tumor with important parietal calcifications, secondary hydrocephalus and non-traumatic rhinorrhea was described. Only when her general condition worsened, with increasing cephalgia as the spontaneous rhinorrhea stopped suddenly the patient accepted emergency operation. The native and contrast CT scan revealed a giant extraxial tumor: 7/9/8 cm, developed in the left posterior fossa which it occupied entirely, in contact with the left mastoid cells, extended over the median line and cranially over the temporal bone, pulling up the tentorium; with severe mass effect on the brain stem. Supratentorial an active internal hydrocephalus with transependymal resorption sign was present to the temporal horns of the ventricular system. The anterior recess of the third ventricle was dilated; with a small discontinuity of the right sphenoid sinus, also air-fluid level. A median shift of 1 cm to the right at the level of third ventricle was described.

Using microsurgical technique the

tumor was subtotally resected because of cardiac rhythm fluctuation and tensional oscillations reasons, less a tumor remnant adherent to the brainstem and tentorium (Simpson D resection), without postoperative complications. In our case with a remote tumor we thought that high pressure cerebrospinal leak associated with focal atrophy on the right sphenoid sinus may explain the symptoms. Tumor removal with or without preoperative shunt may cure rhinorrhea and a direct approach for it was not necessary.

Conclusion

A case of non-traumatic spontaneous right nostril rhinorrhea generated by a giant atypical left posterior fossa, atypical meningioma is described. Using microsurgical resection tumor was subtotally removed, the patient improved and rhinorrhea didn't recur.

References

1. Robertson H.J.F. – Cerebrospinal Fluid Leak, *Emedicine* oct. 26, 2009
2. Snow J.B.Jr., Ballenger J.J. – Complications of skull base surgery, in *Ballenger's Otorhinolaryngology*, 16th ed. Hamilton, Ontario, Decker 2003, 508-36:684-7, 799.
3. Pearson B.W. – Cerebrospinal fluid rhinorrhea, in *Otolaryngology*, 3rd ed. Philadelphia: W.B.Saunders Co. 1991: 1899-909.
4. Sautter N.B., Batra P.S., Citardi M.J. – Endoscopic management of sphenoid sinus cerebrospinal fluid leaks, *Ann Otol.Rhinol.Laryngol* Jan 2008, 117, (1)32-9
5. Guan Jing-yu, Tong Xiao-jie, Wei Xue-zhong – Spontaneous cerebrospinal fluid rhinorrhea in a patient with tentorial meningioma – Case report, *Chinese Medical Journal* 2007, 120(14), 1287-1288
6. Benvenuti D., Lavano A., Corriero G., Irace C., de Divitiis E. – Cerebrospinal rhinorrhea in a patient with a posterior cranial fossa tumor, *Neurosurgery* 1987, 21, 742-744.
7. Obana W.G., Hodes J.E, Weinstein P.R., Wilson C.B – Cerebrospinal fluid rhinorrhea in patients with untreated pituitary adenoma: report of two cases. *Surg. Neurol.* 1990, 33, 336-340
8. Burger P.C., Scheithauer B.W. – Tumors of the Central Nervous System, *Atlas of Tumor Pathology*, ARP Press, 2007
9. WHO Classification of Tumours of the Central Nervous System, 4-th edit., International Agency for Research on Cancer, 2007
10. Miller C. – Case of hydrocephalus chronicus with some unusual symptoms and appearances on dissection, *Trans-med-chir. Soc. Edinb.* 1826, 2:243-248.
11. Thomson St. C. – The cerebrospinal fluid: Its spontaneous escape from the nose. Cited from Cassell: London 1899
12. Oblu N., Ianovici N. – Fistulele lichidului cefalorahinal posttraumatic, *Junimea* 1978, 120-125.
13. O'Connell J.E.A. – The cerebrospinal fluid pressure as an etiological factor in the development of lesions affecting the central nervous system *Brain* 1953, 76: 279-298.
14. Ommaya A.K., DiChiro G., Baldwin H., Pennybacker J.B. – Non-traumatic cerebrospinal fluid rhinorrhea. *J. Neurol.Neurosurg.Psychiat* 1968, 31: 214-225.
15. Rovit R.L., Schechter M.M., Nelson K. – „High Pressure Cerebrospinal Rhinorrhea” Due to lesions Obstructing Flow of Cerebrospinal Fluid, *JNS* 1969, 30, 4.
16. Sang Kun Park, Kyu Chang Lee, Hun Jae Lee – „High Pressure” Cerebrospinal Fluid Rhinorrhea due to Parieto-Occipital Meningioma, a Case Report, *Yonsei Medical Journal*, 1977,18, 2, 160-165
17. Liang C.L. et al. – Non-traumatic cerebrospinal fluid rhinorrhea indirectly caused by remote brain tumor: a case report and review of the literature, *Clin Neurol. Neurosurgery* 2001, 103(2), 83-86.
18. Symms N.P. et al. – Exophytic choroid plexus papilloma of the fourth ventricle presenting with cerebrospinal fluid rhinorrhea: a case report, *Surgical Neurology* 2009, 71, 705-708.
19. Tan S.P. et al. – Rupture of the lateral ventricle secondary to a fourth ventricle tumour resulting in an indirect nontraumatic cerebrospinal fluid fistula, *Neuroradiology* 2003, 45 (1), 53-55.
20. De Lacy P. et al. – Is surgical intervention frequently required for medically managed macroprolactinomas ? A study of spontaneous cerebrospinal fluid rhinorrhea, *Surg.Neurol.* 2009, 72(5), 461-463.
21. Kane P.J. et al. – Cerebrospinal fluid rhinorrhea associated with colloid cyst, *Br. J. Neurosurg.* 1981, 5 (3), 317-320.
22. Kaye A.H. – Posterior fossa meningiomas, in *Marc Sindou – Practical Handbook of Neurosurgery*, Springer – Verlag, 2009, vol. 2, 181-198