

## Giant hyperostosis secondary to a neglected Pott's Puffy Tumour. Surgical repair with CT-assisted cranioplasty Case report

I.St. Florian<sup>1,2</sup>, H. Rotariu<sup>3</sup>, B. Suciu<sup>2</sup>

<sup>1</sup>University of Medicine and Pharmacy "Iuliu Hatieganu" Cluj- Napoca, Romania, Neurosurgical Department

<sup>2</sup>Cluj County Clinical Emergency Hospital, Neurosurgical Department

<sup>3</sup>Cluj County Clinical Emergency Hospital, Cranio-Maxillofacial Department

### Abstract

This paper presents a case with several particularities: severe intracranial hypertension due to a bifronto-parietal hyperostosis secondary to a Pott's puffy tumor previously improperly treated; chronic (18 years) intermittent epidural-cutaneous fistula ; CT- assisted cranioplasty for the largest cranial vault defect ever performed in our department, made with custom made cranial implants (PEMA combined with hydroxyapatite) prepared in a silicone-rubber mould.

**Keywords:** Pott's puffy tumor, Hyperostosis, craniectomy, CT- assisted cranioplasty

### Introduction

Sir Percivall Pott described Pott's puffy tumour in 1768 as a local subperiosteal abscess due to frontal bone suppuration resulting from trauma. Pott reported another case due to frontal sinusitis in 1775. The Pott's puffy tumor is a subperiosteal abscess of the frontal bone associated with an underlying osteomyelitis. The most common cause is frontal sinusitis, with head injury coming on second place (1). The direct spread from erosion of the outer

table can result in a subperiosteal abscess. Similar erosion through the inner table can cause an epidural abscess. Such an abscess could then erode through the dura, and cause a subdural empyema or intraparenchymatous abscess. (1,2). Most of the patients presented with an indolent forehead swelling with or without systemic septic features, which were often mistaken for a 'simple scalp abscess' or 'infected sebaceous cyst'. Simple drainage results in recurrent collection or complications from spreading infection. The Pott's puffy tumor is most often caused by Streptococcus and Staphylococcus species, or by anaerobic organisms. However, multiple organisms are frequently involved simultaneously. In cases involving the intracranial spread of infection, anaerobes are more common (1).

### Material and methods

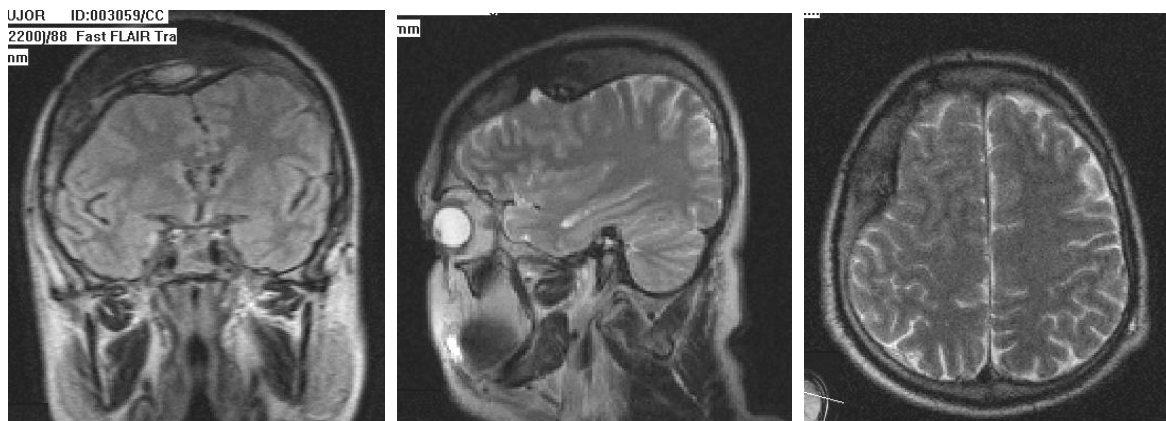
A 47 year-old man was admitted in our department in 1985 with an enlarging mass on his vertex. Physical examination revealed a soft fluctuant, non-tender swelling on the vertex with active signs of inflammation and headache. The patient had a history of severe local trauma several years before admission. Because there was no

intracranial involvement, external drainage of the subperiosteal collection was the treatment of choice, followed by 6 weeks of culture-guided antibiotherapy. Two years later a spontaneous right frontal fistula developed at the site of previous external drainage. Axial CT revealed an enhancing subgaleal mass in the vertex region, associated with an adjacent epidural collection, conducting to a definitive diagnosis of Pott's puffy tumour. At surgery, a small trephination encircling the fistulous channel and epidural drainage of the pus was performed. A 6-week course of intravenously culture-guided antibiotics was administered in postoperative period.

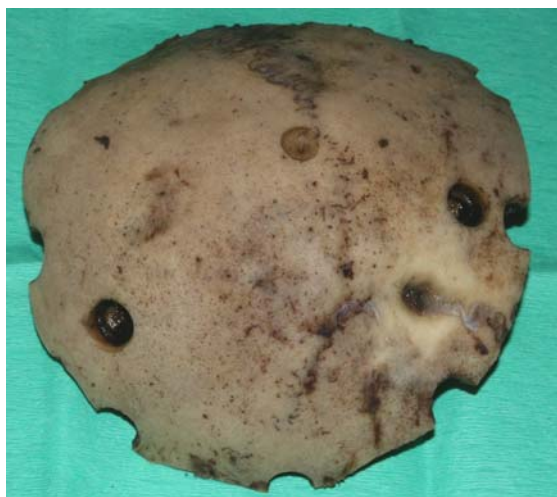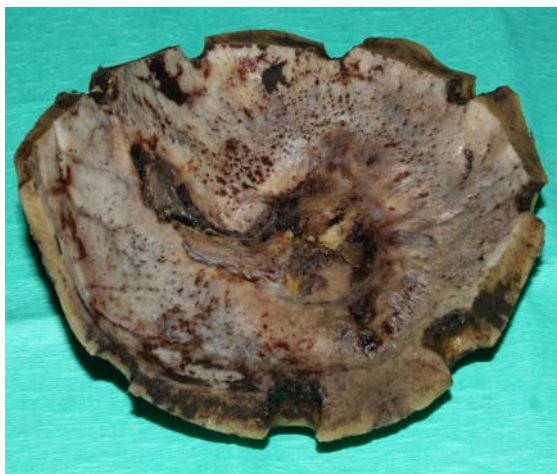
18 year later the patient was readmitted in our department with signs of local infection, intermittent opening of the former fistula and symptoms of increased intracranial pressure. On MRI a massive endocranial bifronto-parietal hyperostosis with mass effect on the adjacent brain was discovered (Figure 1). At surgery, in general anesthesia, large craniectomy was planned by a standard bicoronal skin incision. As the scalp was reflected copious malodorous pus was drained. The scalp in the subgaleal

plane was adherent to the underlying bone secondary to massive amounts of granulation tissue, which formed the puffy tumor. This granulation tissue was removed progressively, and a large bifronto-parietal craniectomy was performed until the normal osseous architecture was met at every border of the craniectomy. The pathological bone was removed in one piece; the endocranial surface presented an important hyperostosis, with an irregular surface (Figure 2). The postoperative course was uneventful and the patient was discharged without any neurological deficit. Follow up controls showed no local signs of infection, the trajectory of the former fistula being completely occluded. After one year the patient presented a mild "trephined syndrome" and, in order to eliminate the drawbacks of a craniectomy status, (Figure 3) a custom made cranioplasty was planned.

The protocol for custom made cranial plates starts with the CT 3D reconstruction based on a spiral CT scan of the head, from Frankfurt horizontal-line to vertex with 0 tilt, and continuous axial slices (2 mm thick).

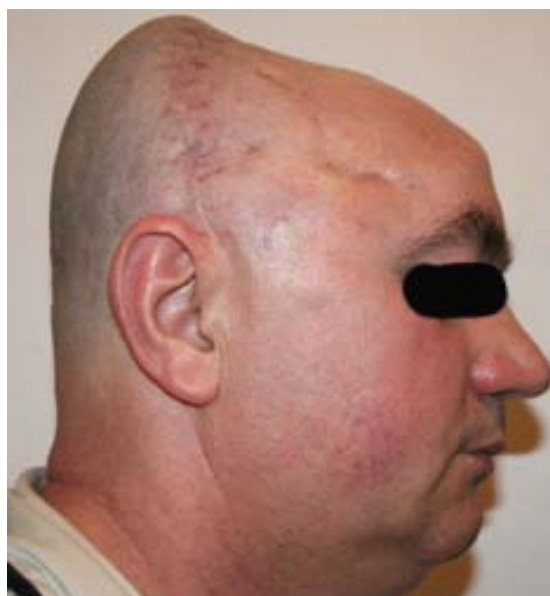
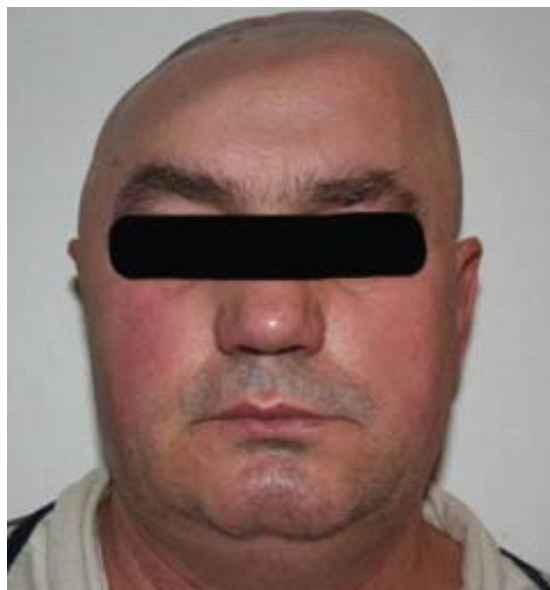
**Figure 1** Cranial MRI: massive endocranial bifrontoparietal hyperostosis with mass effect on the adjacent parenchyma



**Figure 2** One piece craniectomy of the affected bone. Note the thickness irregularities of the inner table

Using mirroring procedures, superimposition, and algebraic Boolean operations a virtual 3D model of the cranioplasty was obtained in order to fit with osseous defect. Using selective laser sintering (SLS) for rapid prototyping, both virtual models (defect and plate) were transformed into real models of polyamide. After a small manual processing, the plate fitted perfectly into the defect (Figure 4). The pattern of the cranioplasty plate made of polyamide (by SLS) was used in order to make a silicone rubber mould.

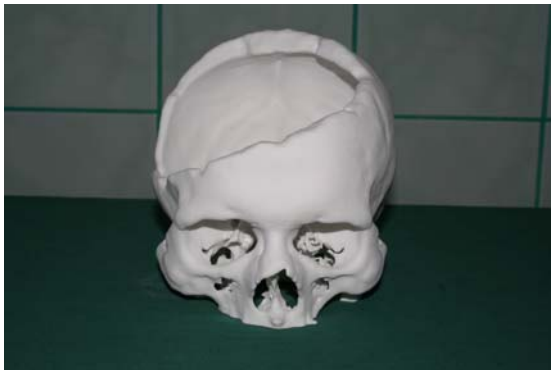

**Figure 3** The cranial aspect after craniectomy

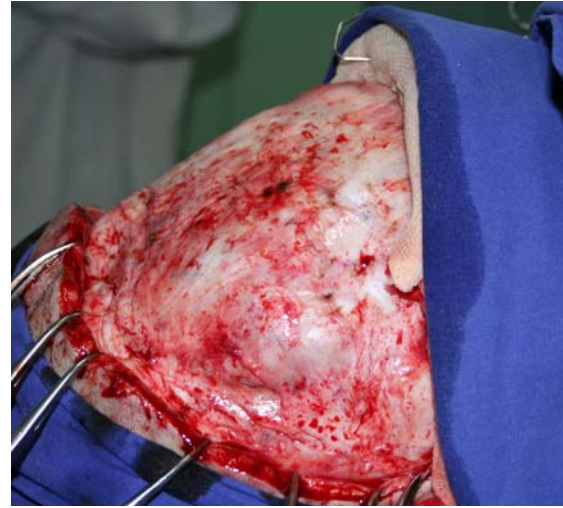The plate was prepared by a radiopaque bone cement of polymethylmethacrylate and polyethylmethacrylate combined with hydroxyapatite, and the paste was casted in the silicone rubber mould and pressed into form (5). After unmoulding, any excess of material was drilled away, and 5 mm diameter holes were placed on the entire surface in order to prevent development of

a postoperative epidural haematoma, and to help fixation. With more than 72 hours before surgery, ethylene-oxide sterilization was applied on the plate.

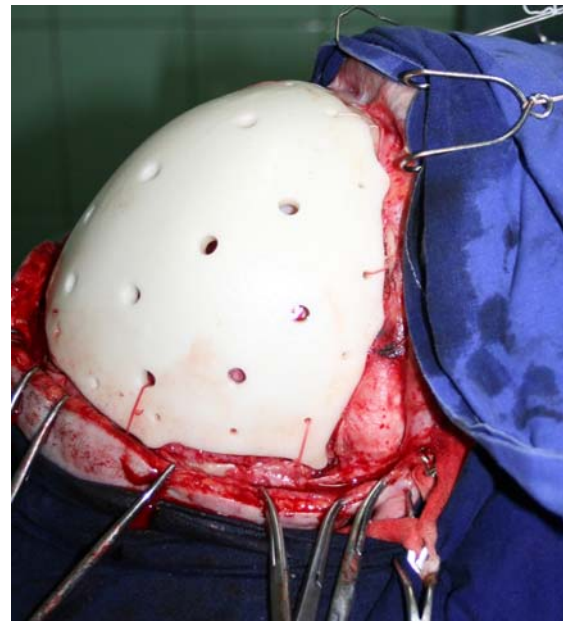
Using the same bicoronal incision in general anesthesia, the patient underwent surgery. During the surgery the most difficult time was the maintenance in the subgaleal plane in a thick scar tissue, in order not to produce any additional lesion on the scalp or on the dura mater. The entire bony defect was exposed, and deperiosteated for fixation. The plate was applied, perfectly fitting at every margin. Using 2.0 silk wires the plate was circumferentially fixed (Figure 5) without any intra- or postoperative complications.



**Figure 4** Using selective laser sintering (SLS) for rapid prototyping, both virtual models (defect and plate) were transformed into real models of polyamide. After a small manual processing, the plate fitted perfectly into the defect



**A**



**B**

**Figure 5** Intraoperative aspects before (A) and after cranioplasty (B)

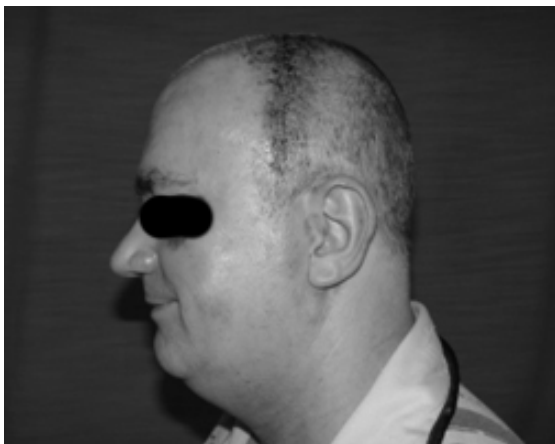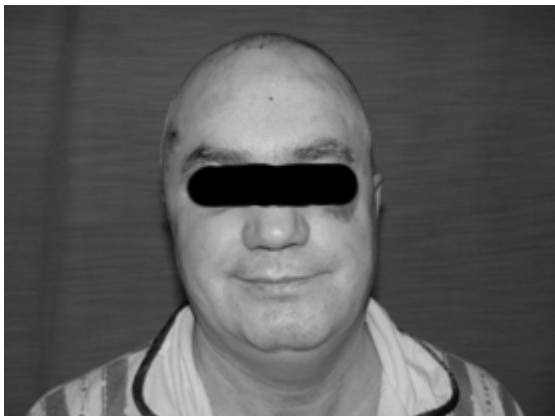The patient was discharged on the eighth postoperative day with a very good functional and esthetic aspect of the cranial vault (Figure 6).

### Discussion

In cases of Pott's puffy tumour most patients are presenting with an indolent

forehead swelling with or without systemic septic features, which were often mistaken for a 'simple scalp abscess' or 'infected sebaceous cyst'. Simple drainage will result in recurrent collection or complications from spreading infection.

The condition requires open drainage with adequate soft tissue and bony debridement. Intracranial complications include extradural empyema, subdural empyema, brain abscess, and venous or sinus thrombosis. *Streptococcus milleri* is the most common organism related to chronic sinusitis reported in the literature. *Staphylococcus*, *Bacteroides* or mixed growth have also been reported.



**Figure 6** Postoperative aspects 7 days after cranioplasty

However, the bacteriology will be different from acute sinusitis (*Streptococcus pneumoniae* or *Haemophilus influenzae*)(14).

The cornerstone of treatment for the Pott puffy tumor is surgery (1). The goals are to drain all associated abscesses, send the fluid for Gram staining and culture, and remove all of the osteomyelitic bone until the limits of craniectomy meets normal osseous architecture. Large cranial defects produce not only aesthetic, but also functional alterations. (6,7).

One very important particularity in this case is the endocranial hyperostosis, reactive to chronic osteomyelitis. Although it is well known that the osteomyelitis is radiologically described as an osteolytic lesion, in this particular case the chronic infection produced an osteogenical reaction probably due to the periosteum capacity to react to different stimuli by producing osseous tissue. Until now no other case with such an osseous reaction was described.

Although the Pott puffy tumor is rarely seen in the era of antibiotics, a delayed or missed diagnosis can lead to such associated complications as epidural abscess, subdural empyema, sinus thrombosis, and intraparenchymal abscess. An optimal outcome is best attained with early diagnosis followed by aggressive treatments. Another particular aspect of the reported case is the 18 years patient's tolerance to a chronic infection on the calvaria without any neurological or general clinical impairment, except the last month before readmission when increased intracranial pressure syndrome developed.

Considering the cranioplasty, the three-dimensional imaging and rapid prototyping techniques associated with the use of

alloplastic materials allow manufacture of a cranioplasty plate preoperatively. The defect is repaired symmetrically even in thickness. Various materials have been used to fill defects in the cranial vault, such as titanium, xenografts, autografts, and allografts (8). A good synthetic material must be: biocompatible, inert, low or even non-thermal conductive, capable of generating no artifacts on CT and MRI, of the same weight as the bone or even lighter, strong enough to resist functional stress, simple to work with and not expensive. Acrylates are fulfilling these demands. Polymethylmethacrylate (PMMA) is one of the most used for material for cranioplasty. Polyethylmethacrylate (PEMA) offers some advantages over PMMA, such as greater elasticity, lower polymerization temperature, easiness in processing. When PEMA is combined with hydroxyapatite the advantages are even better: physical resistance similar to bone, formation of collagen bridges between bone and hydroxyapatite (9,10).

It is difficult to produce a symmetric, accurate implant presurgically, or at the time of surgery when the defect is greater than 50 cm<sup>2</sup> (11). The method presented here used a silicone rubber mould. Compared to plaster, the main advantage of silicone rubber is that it allows preservation of very thin details of the plate (e.g. margins) during unmolding. Preserving the thin margins of the plate provided a better stabilization and there was no need of rigid fixation. The latter could prevent secondary damage to the brain during drilling and screwing (9).

## Conclusion

Surgical intervention is the treatment of choice in Pott's Puffy Tumor. A thorough

debridement of granulation, removal of the infected bone and underlying epidural granulations, drainage of pus are mandatory. To repair large skull defects one can choose either to reconstruct the vaults strictly intra-operatively, or to prepare a so called "custom made cranial implant," prior to the operation. The disadvantages of intra-operative repair are the time-consuming, the increasing risk to the patient, insufficient protection from trauma and infection, often resulting in suboptimal cosmetic result. However, custom made cranioplasty implants have the advantages of a reduced operative time, less invasive surgery, improved cosmetic results, faster recuperation, and reduced costs due to short a operative time (9,12,13).

## References

1. Laurence Davidson, M.D., and J. Gordon Mc Comb, M.D. Epidural-cutaneous fistula in association with the Pott puffy tumor in an adolescent. Case report. *J Neurosurg* (3 Suppl Pediatrics) 105:235-237, 2006.
2. Ramos A, Rayo JI, Martin R, Pardo JL, Gomez JL, del Canizo A. Epidural empyema; a complication of frontal sinusitis. *Acta Otorrinolaringol Esp*. 1989 Nov-Dec;40(6):451-3.
3. Ç. Evliyaoglu; G. Bademci; E. Yucel and S. Keskil. Pott's puffy tumor of the vertex years after trauma in a diabetic patient: case report. *Neurocirugía* vol.16 no.1 Murcia Feb. 2005.
4. Marquardt, G., Schick, U., Moller-Hartmann, W.: Brain abscess decades after a penetrating shrapnel injury. *Br J Neurosurg* 2000; 14: 246-248
5. H. Rotaru, S. Bran, G. Băciuț, M. Băciuț, C. Dinu, H. Stan, H. Chezan, S.G. Kim, D. Munteanu and P. Berce. Silicone-Rubber Moulding of Custom-made Cranioplasty Plates. XVIII Congress of the European Association for Cranio-Maxillo facial Surgery. Barcelona (Spain), September 12-15, 2006 Durand JL, Renier D, Marchac D. The history of cranioplasty. *Ann Chir Plast Esthet*. 1997 Feb;42(1):75-83.
6. Dujovny M, Aviles A, Agner C, Fernandez P, Charbel FT: Cranioplasty: cosmetic or therapeutic? *Surg Neurol* 47: 238-241, 1997.
7. Dujovny M, Agner C, Aviles A.: Syndrome of the trephined: theory and facts. *Crit Rev Neurosurg* 24: 271-278, 1999.



8. Durand JL, Renier D, Marchac D: The history of cranioplasty. *Ann Chir Plast Esthet* 42: 75-83, 1997.
9. Horatiu Rotaru, Mihaela Băciuț, Horatiu Stan, Simion Bran, Horea Chezan, Alexandru Iosif, Mircea Tomescu, Seong-Gon Kim, Alexandru Rotaru, Grigore Băciuț. Silicone rubber mould casted polyethylmethacrylate-hydroxyapatite plate used for repairing a large skull defect. *Journal of Cranio-Maxillofacial Surgery* (2006) 34, 242-246.
10. Florian St, Sima V, Tomescu M: Placa PEM-HA pentru cranioplastie. *Quo Vadis*, 2, :21-22, 1998.
11. Van Putten MC Jr, Yamada S. Alloplastic cranial implants made from computed tomographic scan-generated casts. *J Prosthet Dent*. 1992 Jul;68(1):103-8.
12. Rotaru AH: Avantajele si dezavantajele utilizarii modelelor tridimensionale medicale. In: Rotaru AH: *Reconstructii si Modele Tridimensionale Medicale*. Ed. Casa Cartii de Stiinta, Cluj-Napoca, 2001. Pp. 99-100.
13. Yacubian-Fernandes A, Laronga PR, Coelho RA, Ducati LG, Silva MV. Prototyping as an alternative to cranioplasty using methylmethacrylate: technical note. *Arq Neuropsiquiatr*. 2004 Sep;62(3B):865-8. Epub 2004 Oct 5.
14. Kung SW, Chan DTM, Suen PY, Boet R, Poon WS; Pott's puffy tumour; *Hong Kong Med J* Vol 8 No 5 October 2002.