

Dumitru Bagdasar – rediscovered after 70 years

D. Adam, Ioana Hornea

Emergency “St. Pantelimon” Hospital Bucharest

Abstract

The authors present the case of a female patient with Sturge-Weber disease, who was operated in her childhood by Dr. Bagdasar and who is hospitalized in the Neurosurgery department after 72 years from operation, because of a craniocerebral trauma.

The patient presents Dr. Bagdasar’s hand written documents which reveal the complex medical personality of the one who was the pioneer of modern neurosurgery in Romania.

Keywords: Dumitru Bagdasar, Sturge-Weber disease.

Case presentation

The 84 years old patient was hospitalized for a minor craniocerebral trauma, manifested by headache, dizziness and a vertex plague, which occurred after a fall from the same level.

Following the personal pathologic history, we find that at the age of 13, the patient had attacks of loss of consciousness for which she was admitted to the Neurosurgery department, which was led by Dr. Dumitru Bagdasar who performed a surgery for a brain tumor. Postoperatively, the crises disappeared for a year; they reappeared and continued over the next 18 years, under treatment with luminal and hydantoin.

On the general examination it is discovered the presence of a left frontal

cutaneous hemangioma (Figure 1).

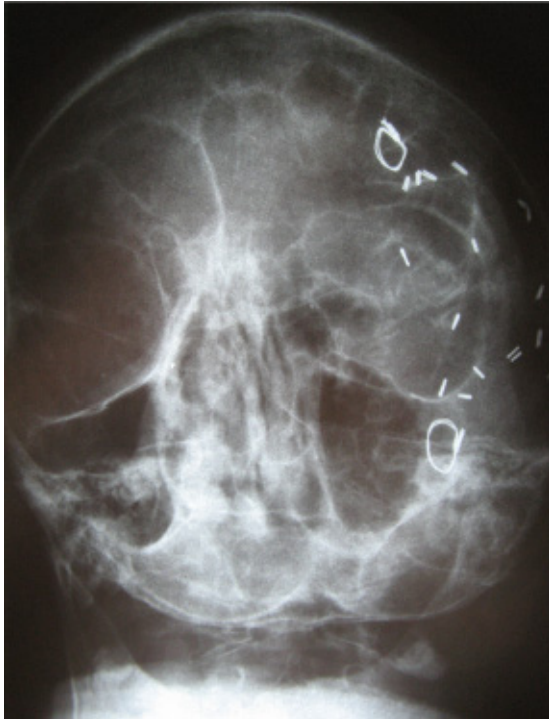
Skull radiography shows multiple clips in the left parietal-occipital region underlying a cranial flap attached to the skull with wire and fully welded (Figure 2).

Brain MRI examination reveals a left parieto-occipital region with T1 weighted hyposignal and T2 weighted hypersignal, with a disabling stroke aspect; on the T2* sequence there are seen the arc shape haemostatic clips and also infracentimetric injuries of no signal with microcalcification aspect, leukoaraiosis aspect in the periventricular white matter, endocranial arteries without flow abnormalities (Figure 3).

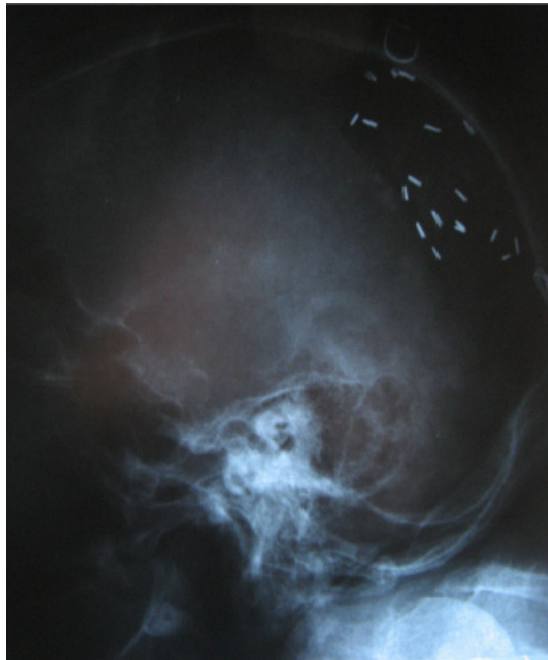
The patient also gives us two original documents signed by Dr. Bagdasar. The first shows that she was operated on 1.IV.1938 for a brain tumor (Figure 4) and the second one contains detailed recommendations on diet (Figure 5).

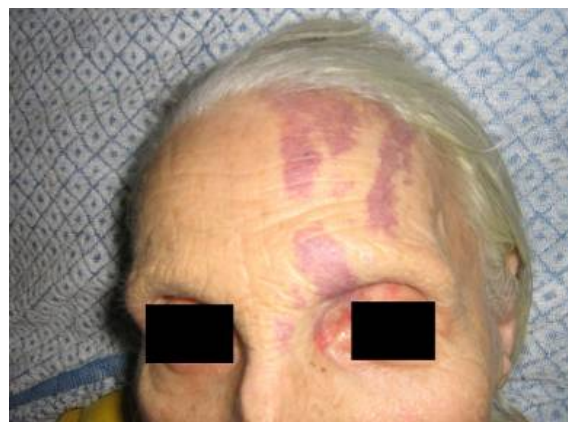

Figure 1 Photograph of the S.O. patient shows a skin hemangioma located in the left frontal region, marker of Sturge-Weber disease

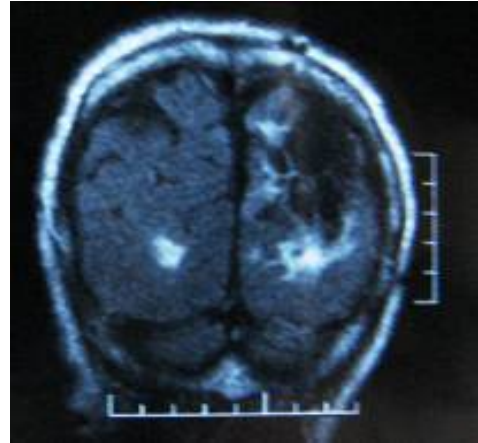


A

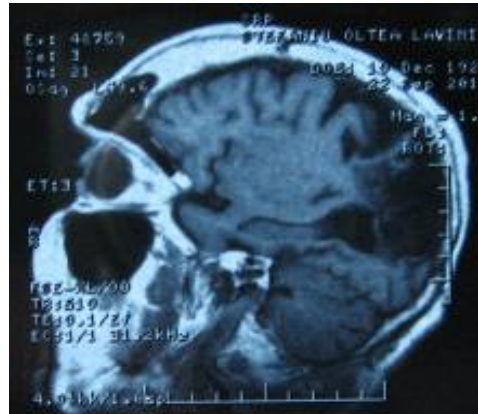

B

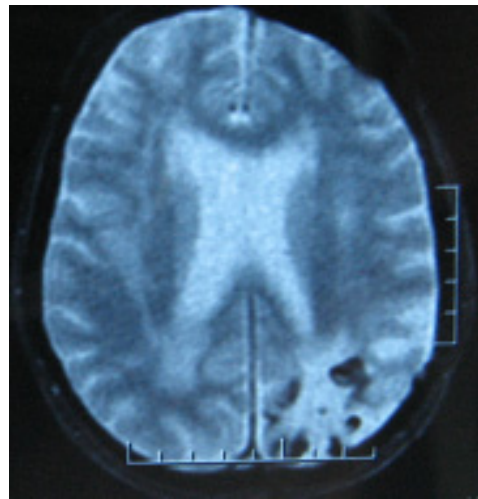
Figure 2 Anterior (a) and lateral (b) radiographs of the cranium show multiple vascular clips



A



B



C

Figure 3 Coronal T1 weighted (a) and sagittal T1 weighted (b) MR images show hypointensity area in P.O. region. Axial T2* MR image (c) shows haemostatic clips and microcalcifications

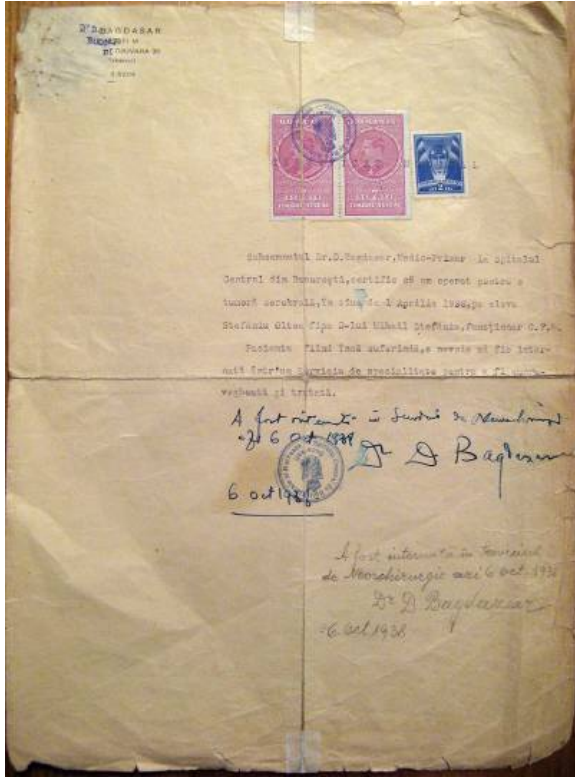

Figure 4

Dr. D. BAGDASAR
 Bucharest VI
 30 Dr. E. Juvara Street
 (former Erbariei)
 Tel: 362-04

Dr. D. Bagdasar, the undersigned, Senior Specialist at the Central Hospital of Bucharest, certify that I performed a surgery for a brain tumor, on April 1, 1938, on Stefaniu Oltea student, daughter of Mr. Michael Stefaniu, official at C.F.R.

Since the patient is still suffering, she needs to be hospitalized in a specialized department to be monitored and treated.

She was admitted to the Neurosurgery department today October 6, 1938.

Dr. D. Bagdasar

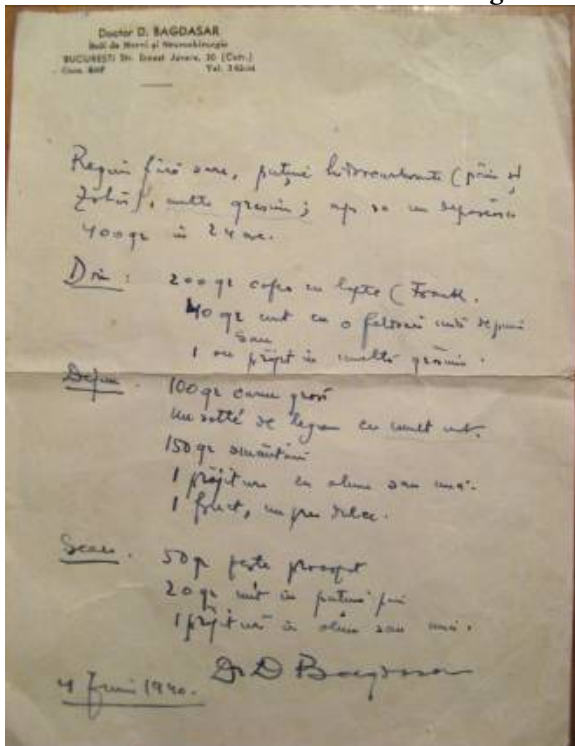


Figure 5

Doctor D. BAGDASAR
 Diseases of Nerves and Neurosurgery,
 Bucharest, 30 Juvara Ernest Street, Tel: 362-04.

Diet without salt, few carbohydrates (bread and sugar), many fats, not to exceed 400gr in 24 hours.

- Breakfast: 200 g coffee with milk, 40 g butter with a small slice of bread or 1 egg fried in a lot of fat.
- Lunch: 100 g fatty meat, a vegetable sauté with a lot of butter, 150g cream, 1 cake with hazelnuts or walnuts, 1 fruit, not too cold.
- Dinner: 50 g of fresh fish, 20 g butter with a little bread, a cake with hazelnuts or walnuts.

June 4, 1940 Dr.D.Bagdasar

Discussions

If the history of the neurosurgery began with the invention of the trepanation of the cranium, modern neurosurgery was recognized as a distinct science in 1921 (1).

After graduating medical studies, Dr. Dumitru Bagdasar followed a postgraduate training in the field of neurology and surgery. Dr. Bagdasar having serious medical knowledge acquired from the Romanian medical education, faced the challenge to study a new science in the United States.

In the 1928-1929s he followed an internship in the U.S., in the clinic of Prof. Cushing, where there were formed over 30 neurosurgeons, pioneers of neurosurgery in Europe and America. (2)

Returning in his country, Dr. Bagdasar worked in hospitals in Jimbolia and Cernăuți.

In 1935, in Bucharest was created the first Neurosurgery department, with 10 beds at the Hospital for Mental Diseases, the future Hospital 9, today Bagdasar-Arseni Hospital (3).

Our case shows that after a limited internship of only two years in America, he

successfully treated rather unusual neurosurgical pathology, such as Sturge-Weber disease.

Dr. Bagdasar was not only a good operator. He was concerned with the complex care for patients, including prescribing a diet, which is quite unusual for today's neurosurgeons.

Along with Dr. Arseni, his collaborator, Dr Bagdasar founded the modern, scientific Romanian neurosurgery. The Neurosurgery Department at the Hospital 9 in Bucharest was the main training center of the Romanian neurosurgeons for the following 50 years.

The followers of this illustrious neurosurgeon and also the patients who still survive, pay him homage.

References

1. Laws ER Jr: Neurosurgery's man of the century: Harvey Cushing. *Neurosurgery* 45: 977-982, 1999.
2. Shillito, John; Black, Peter M.: *The Harvard Neurosurgical Service At the Children's Hospital Boston and Brigham & Women's Hospital, 1912-2007.* *Neurosurgery.* 63(3):579-593, September 2008.
3. Adam, Danil: *Neurochirurgie. Curs universitar.* Editura Didactică și Pedagogică, București, 2005.