



# Traumatic posterior fossa extradural hematoma. A comprehensive analysis of cases from a tertiary care centre in Southwestern Rajasthan

Vibhu Shankar Parashar, Vivek Kumar Kankane,  
Gaurav Jaiswal, Tarun Kumar Gupta

\* Department of Neurosurgery, Rabindra Nath Tagore Medical College & M.B. Groups of Hospital, Udaipur, Rajasthan, INDIA

## ABSTRACT

**Background.** Extradural hematoma of posterior fossa (PFEDH) is less common and there are not many articles about PFEDH. These patients can deteriorate very rapidly due to compression over brainstem. Thus, early identification and immediate intervention can save the lives of these patients.

**Objective.** This study aims to conduct a comprehensive analysis of patients with PFEDH and evaluate the postoperative outcome which may be of help to make further preventive strategies.

**Methods and Materials.** The study included 16 patients admitted with traumatic PFEDH from July 2016 to July 2018 at R.N.T. Medical College & M.B. Groups of Hospital Udaipur, southwestern Rajasthan, India. We have retrospectively reviewed the data. Analysed factors were gender, age, Glasgow Coma Scale (GCS), Noncontrast CT scan findings, associated brain injury, type of intervention, Glasgow Outcome Scale (GOS). GOS was assessed at discharge, at 3 months and 6 months follow-up.

**Results.** Out of a total of 16 patients, 11 were male and 5 were female with age ranging from 05-46 years. 12 patients had GCS 13 -15 at admission and only one of them had GCS < 8. 15 patients underwent surgical intervention. At 6 months follow-up, 12 patients had good recovery GOS is 5.

**Conclusion.** Early detection and immediate evacuation of PFEDHs should be done if causing fourth ventricle, basal cistern or brain stem compression. It may be rapidly fatal due to the expansion of hematoma leading to brainstem compression, tonsillar herniation, and/or obstructive hydrocephalus. Early detection and immediate evacuation lead to a better outcome in these patients.

## INTRODUCTION

PFEDH is an uncommon trauma sequel accounting for only 4% to 12.9% of all EDHs<sup>[1,2]</sup>. In PFEDH clinical progress may be silent and slow, but sudden deterioration may occur without significant warning signs. Because of limited space in posterior fossa, comparatively small volume can cause clinical deterioration. The patient may deteriorate very rapidly due to compression over the brainstem usually without

---

**Keywords**  
posterior fossa,  
extradural hematoma,  
traumatic,  
Glasgow outcome Scale

---



Corresponding author:  
**Vivek Kumar Kankane**

Rabindra Nath Tagore Medical  
College & M.B. Groups of Hospital,  
Udaipur, Rajasthan,  
India

drvarunaggarwal86@gmail.com

**Copyright and usage.** This is an Open Access article, distributed under the terms of the Creative Commons Attribution Non-Commercial No Derivatives License (<https://creativecommons.org/licenses/by-nc-nd/4.0/>) which permits non-commercial re-use, distribution, and reproduction in any medium, provided the original work is unaltered and is properly cited. The written permission of the Romanian Society of Neurosurgery must be obtained for commercial re-use or in order to create a derivative work.

ISSN online 2344-4959  
© Romanian Society of  
Neurosurgery



First published  
June 2019 by  
London Academic Publishing  
[www.lapub.co.uk](http://www.lapub.co.uk)

any prior warning sign. Thus, early intervention before progression to herniation is lifesaving. Early diagnosis by cranial computed tomography and emergent evacuation is vital for a good outcome<sup>[3]</sup>.

#### MATERIAL AND METHODS

In our study, we have retrospectively reviewed the data from July 2016 to July 2018 at tertiary care hospital in R.N.T. Medical College & M.B. Groups of Hospital Udaipur, southwestern Rajasthan. We found 16 cases of traumatic Extradural Hematoma (EDH) which were located in the posterior fossa.

The Data was analysed for clinical presentation, Glasgow Coma Scale (GCS) at admission, mode of injury, radiological findings, any other associated

intracranial traumatic lesion, type of intervention and postoperative outcome. Postoperative scans, within 6-12 hour of surgery were acquired in all cases. Outcomes were assessed on the basis of Glasgow Outcome Score (GOS) divided into good (normal, moderate disability) and poor (severe, vegetative, dead) outcome at 3 months, 6 months of follow-up. We also assessed the prognosis of posterior fossa EDH depending on the compression over the fourth ventricle, basal cistern and brain stem. All patients were divided in two groups. Group A were those who showed isolated PFEDH and in group B were those patients who showed PFEDH associated with brain injury.

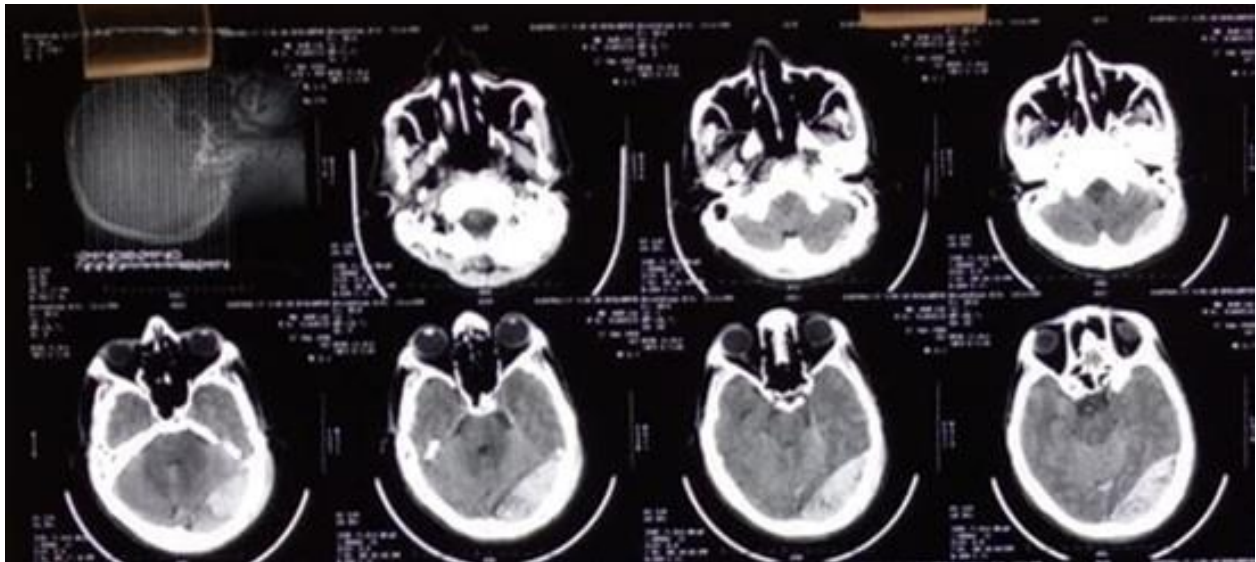
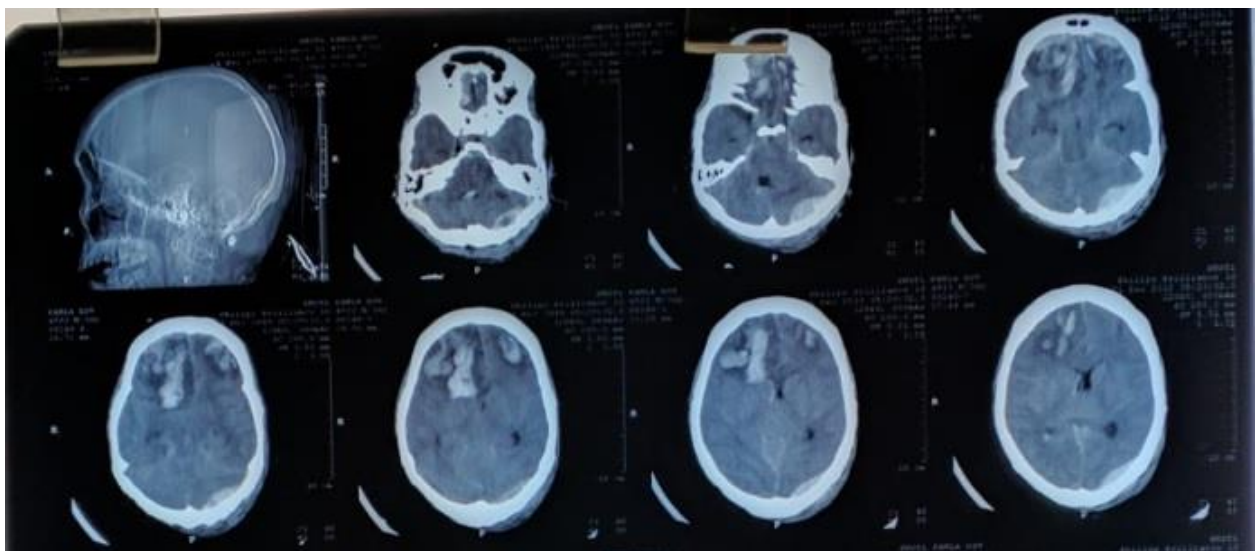


FIGURE 1. NCCT head revealed Left posterior fossa Extradural Hematoma with supratentorial extension

FIGURE 2. NCCT head revealed left posterior fossa Extradural Hematoma with bilateral frontal intracerebral hematoma



## RESULTS

A total of 16 cases of PFEDHs were admitted to our tertiary care centre during 24 months from July 2016- July 2018. The mean age of patients was 28.6 years (range 5-46 years). 3 (18.75%) of them were below 18 years. 5 (31.25%) of them were Females (TABLE 1). Outcome was better in paediatric patients.

Most common mode of injury was road traffic accident (n= 11, 68.75%), rest were either fall from height (n = 04, 25%) or assault (n =1, 6.25%) (TABLE - 2). Most common associated radiological finding is occipital bone fracture followed by supratentorial

extension of EDH and frontal contusions (TABLE 3).

15 patients underwent surgical evacuation. At 6 months follow-up, 12 (75%) patients had good recovery and one patient died (6.25%) (TABLE 4). Patients with PFEDH with associated brain injury had lesser GCS Score on admission with increased volume of EDH, increased hospital stay. Outcome was poor in PFEDH patients with associated intracranial injury as compared to those with isolated PFEDH. (TABLE 5)

TABLE 1. Correlation of Gender and Age and outcome analysis

Total cases	Number. of patients (N=16)	AGE<18 Yrs	AGE>18 yrs	Percentage (%)	Good outcome (GOS 3-5)	Poor outcome (GOS1-2)
<b>Gender</b>						
Male	11	03	08	68.75%	10	01
Female	05	00	05	31.25%	03	02
<b>Age</b>						
Pediatric patients (<18)	03			18.75 %	03	00
Adults	13			81.25%	10	03
<b>Total</b>	16			100%	13	03

TABLE 2. Correlation of mode of injury, GCS at admission and outcome analysis

	No. of patients	Percentage	Good outcome (GOS 3-5)	Poor outcome (GOS 1-2)
<b>Mode of injury</b>				
Road traffic accident	11	68.75%	09	02
Fall from height	04	25%	03	01
Assault	01	6.25%	01	00
<b>GCS at admission</b>				
13-15	12	75%	12	00
9-12	03	18.75%	01	02
3-8	01	6.25%	00	01
<b>Total</b>	16	100%	13	03

TABLE 3. Analysis of clinical presentation and radiological findings

	Number of patients	Percentage
<b>Clinical presentation</b>		
Headache	10	62.5%
Altered sensorium	06	37.5%
Vomiting	08	50%
<b>Radiological findings</b>		
Occipital bone fracture	12	75%
Frontal contusions	01	6.25%
Supratentorial extension of EDH	02	12.5%
Hydrocephalus	01	6.25%
Intraventricular hemorrhage	01	6.25%

TABLE 4. Outcome based on GOS (Glasgow outcome score)

Outcome based on GOS	Discharge	At 3 months	At 6 months
GOS 5	11	12 (75%)	12 (81.25%)
GOS 4	03	01 (6.25%)	No follow up
GOS 3	00	01 (6.25%)	01 (6.25%)
GOS 2	01	01 (6.25%)	01 (6.25%)
GOS 1	01	-	-

TABLE 5. Analysis of patients with isolated PFEDH and those with associated brain injuries

Parameters	Isolated PFEDH (Group A)	PFEDH and associated brain injury (Group B)
<b>Total patients</b>	13(81.25%)	03(18.75%)
<b>Radiological findings</b>		
Occipital bone fracture	10(76.9%)	02(66.7%)
Frontal contusions	-	01(33.3%)
Supratentorial extension of EDH	-	02(66.7%)
Hydrocephalus	-	01(33.3%)
Intraventricular hemorrhage	-	01(33.3%)
<b>GCS (admission)</b>		
15-13	11	01
12-9	02	01
8-3	00	01
<b>Management</b>		
Surgical evacuation	11	03
Conservative	02	00
Failed conservative and operated	01	00
<b>GCS (discharge)</b>		

15-13	13	01
12-9	00	01
8-3	00	01
Good outcome (GOS 3,4,5)	12	01
Poor outcome (GOS1,2)	01	02

## DISCUSSION

Traumatic brain injury is emerging as the most common cause of morbidity and mortality in both developed and developing countries. PFEDHs are reported to constitute 0.1–0.3% of all cranial traumatic conditions. Loss of consciousness and vomiting are the most frequent presenting features of PFEDH which comprises around 10% of EDH. A history of occipital bone fracture combined with these symptoms should raise suspicion of PFEDH. Lucid interval is classically seen in EDH; however, it is uncommon in PFEDH and in children. A rapid deterioration is a feature of these lesions. Thus, all patients need to undergo imaging promptly in order to diagnose the lesions.

Unlike supratentorial EDHs where the source of bleeding is usually the middle meningeal artery in temporo-parietal EDHs and the anterior ethmoidal artery in frontal EDHs.<sup>[4]</sup> PFEDHs have a venous origin in 85% of the cases and develop as a result of injury to the transverse or sigmoid sinuses secondary to occipital bone fracture.<sup>[5]</sup> However, an extradural hematoma can develop without fracture. Since most of the PFEDHs are of venous origin and expand slowly, it takes longer for the clinical picture to develop in PFEDH and it is of vital importance to use imaging methods for early diagnosis. Currently, NCCT scan is the imaging of choice in brain trauma.

In the literature it has been reported that PFEDHs are most commonly encountered in the first decade.<sup>[6,7]</sup> In our study, 03 (18.75%) cases were paediatric patients. Male gender dominated in our group, which is in line with data in the literature. This fact is explained by greater liability to trauma at work, road accidents and alcoholism in men. A leading cause of PFEDHs in our series were road traffic accidents, although in paediatric patients the most common mode of injury was falls. In all the female patients, the reason for traumatic PFEDH was attributed to sitting on vehicles as pillion riders and indicating the lack of support in the vehicles.

The majority of PFEDHs were unilateral with prevalence on the left side (93.75%). In one patient

(6.25 %) the PFEDH was bilateral and similar observation was reported by Karasu *et al.* Fracture of occipital bone is a common feature (in 58-95% of PFEDH) even though not all of them are visible on plain X-rays of the skull .75% of our patients had fracture of occipital bone, or parietal bones in occipital region on the side of extradural hematoma.

Whereas some authors reported the occurrence of coexisting lesions in 23 - 50% of cases. We also observed them in three of our patients. The most common associated intradural lesion was supratentorial extension of EDH, brain contusion followed by a subdural collection and acute hydrocephalus.

Bozbuga *et al.* reported 73 cases in 1999, the largest series on PFEDH till now. Out of 73, they operated 53 cases<sup>[6]</sup>. 89% of operated patients had a good recovery, and 5.4% died. Malik *et al.* published another series of 61 patients in 2007<sup>[8]</sup>. Of these 48 were managed surgically, 36 (59%) had a good recovery and 15% died. Roka *et al.*<sup>[9]</sup> reported 43 patients in 2008, of these 33 were operated and were followed up for 79 months with 81.8% good recovery in the operated patients and 3% overall mortality<sup>[9]</sup>.

In our study 15 patients underwent surgical evacuation. During 6 months follow-up, 12(75%) patients had good recovery and one patient died (6.25%). This was similar to study by Jang *et al.*<sup>[10]</sup> and Balik *et al.*<sup>[11]</sup>. Jang *et al.*, in 2011, published the review of 34 patients with 96 months follow-up<sup>[10]</sup>. Nineteen patients underwent surgical evacuation with 73.7% having a good recovery and 5.3% mortality.

Three series comprised paediatric cases only., Gupta *et al.* in 2002<sup>[12]</sup>, Sencer *et al.*, in 2012<sup>[13]</sup> Prasad *et al.* in 2015<sup>[14]</sup>, and published paediatric series with 18,40 and 18 cases, respectively. Sencer reported good recovery in all cases. Prasad's series had 94.4% patients with good recovery. Both these series showed better outcomes in paediatric age group. Outcome was better in paediatric patients in our study.

Admission GCS is the single most important

factor that determined the immediate and long-term outcomes. Patients with additional intracranial findings had relatively poor GCS at admission and categorically much poor outcomes. Patients with mass effect over brainstem had lesser GCS Score on admission with increased volume of EDH, increased hospital stay and increased mortality<sup>[15]</sup>. Nonsurgical management is a viable option in select patients with low EDH volumes, but option should be kept for surgical evacuation in such patients for better outcome.

### CONCLUSION

PFEDH is a rare entity and posterior fossa is an unfavorable location. They are usually associated with occipital bone fractures. Early diagnosis and emergent evacuation lead to good outcome.

PFEDH may be rapidly fatal due to the expansion of hematoma and compromise of the posterior cranial fossa space leading to brainstem compression, tonsillar herniation, and/or obstructive hydrocephalus which are associated with worse outcome.

### REFERENCES

1. Ammirati M, Tomita T. Posterior fossa epidural hematoma during childhood. *Neurosurgery* 1984; 14: 541-44.
2. Asanin B. Traumatic epidural hematomas in posterior cranial fossa. *Acta Clin Croat.* 2009;48:27-30.
3. Berker M, Cataltepe O, Ozcan OE. Traumatic epidural haematoma of the posterior fossa in childhood: 16 new cases and a review of the literature. *Br J Neurosurg.*2003;17:226-9.
4. Samudrala S, Cooper PR. Traumatic intracranial hematomas. In: Wilkins RH, Rengachary SS, editors *Neurosurgery*. 2nd ed. New York: McGraw-Hill; 1996. pp. 2797-807.
5. Garza-Mercado R. Extradural hematoma of the posterior cranial fossa. Report of seven cases with survival. *J Neurosurg.* 1983;59:664-72.
6. Bozbuga M, Izgi N, Polat G, Gürel I. Posterior fossa epidural hematomas: Observations on a series of 73 cases. *Neurosurg Rev.*1999;22:34-40
7. Peter JC, Domingo Z. Subacute traumatic extradural haematomas of the posterior fossa: A clinicopathological entity of the 5- to 10-year-old child. *Childs Nerv Syst.* 1990;6:135-8.
8. Malik NK, Makhdoomi R, Indira B, Shankar S, Sastry K. Posterior fossa extradural hematoma: Our experience and review of the literature. *Surg Neurol.* 2007;68:155-8.
9. Roka YB, Kumar P, Bista P, Sharma GR, Adhikari P. Traumatic posterior fossa extradural hematoma. *JNMA J Nepal Med Assoc.* 2008;47:174-8.
10. Jang JW, Lee JK, Seo BR, Kim SH. Traumatic epidural haematoma of the posterior cranial fossa. *Br J Neurosurg.* 2011;25:55-61
11. Balik V, Lehto H, Hoza D, Sulla I, Hernesniemi J. Posterior fossa extradural haematomas. *Cent EurNeurosurg.* 2010;71:167-72.
12. Gupta PK, Mahapatra AK, Lad SD. Posterior fossa extradural hematoma. *Indian J Pediatr.*2002;69:489-94.
13. Sencer A, Aras Y, Akcakaya MO, Goker B, Kiris T, Canbolat AT. Posterior fossa epidural hematomas in children: Clinical experience with 40 cases. *J NeurosurgPediater.* 2012;9:139-43.
14. Prasad GL, Gupta DK, Sharma BS, Mahapatra AK. Traumatic pediatric posterior fossa extradural hematomas: A tertiary-care trauma center experience from India. *PediatrNeurosurg.* 2015;50:250-6.
15. Pateriya A, Bansal R, Mittal R. Factors affecting outcome in posterior fossa EDH: an analytical study at tertiary referral hospital. *Romanian Neurosurgery* .2016; XXX 2: 267-71.