

Update on the natural history of infratentorial cavernous malformations

M. Gorgan, Angela Neacsu, Narcisa Bucur, V. Pruna, A. Giovani, Aura Sandu, Adriana Dediu

First Neurosurgical Clinic, Fourth Neurosurgical Department, Clinic Emergency Hospital "Bagdasar-Arseni", Bucharest

Abstract

Infratentorial cavernous malformations are still a source of serious controversies in neurosurgery and their natural history and treatment are intensely debated in literature. Recent studies suggest that symptomatic infratentorial cavernous malformations have a more aggressive clinical outcome than the supratentorial ones (the risk of hemorrhage is approximately 30 times that of the supratentorial cavernomas). The optimal therapeutic approach of infratentorial cavernomas need a good understanding of the natural history and also the characteristics that may influence the associated neurological risk, like the patient status at admission, the localization and the genetics of the malformation. Many studies have been published in the last decades to enlight the clinical aspects and the natural history of these vascular malformations. The purpose of this analysis is to make a literature review of the morbidity risk associated to cavernous malformations and their influence on the treatment plan.

Keywords: natural history, infratentorial cavernomas, risk of hemorrhage

Introduction

Even if the first account of cavernoma surgery dates back to 1928 when Dandy

evacuated a brain stem hemorrhage, resulted from a ruptured cavernoma studies on the natural history and management of these lesions appeared after 1980.

Cavernous malformations are composed of a compact mass of sinusoidal-type vessels immediately in apposition to each other without any recognizable intervening neural parenchyma, delimited only by a row of endothelial cells surrounded by conjunctive tissue. They may reach a considerable size and usually are round or lobulated. They can be classified on various criteria: number, location, type of development, MRI aspect, etc. The most used classification is: sporadic form, with unique lesions and familial form characterized by multiple lesions and a family history.

The familial type of disease is found in 20-30% of the patients with cavernous malformations. According to the time of appearance cavernomas can be congenital, present at birth (all cavernomas were considered congenital till 1990) and de novo, developed after birth, spontaneous or postirradiation.

According to localization infratentorial cavernomas are classified in cerebellar (Figure 2) and brainstem cavernomas (Figure 1), this classification being extremely important in the therapeutic planning.

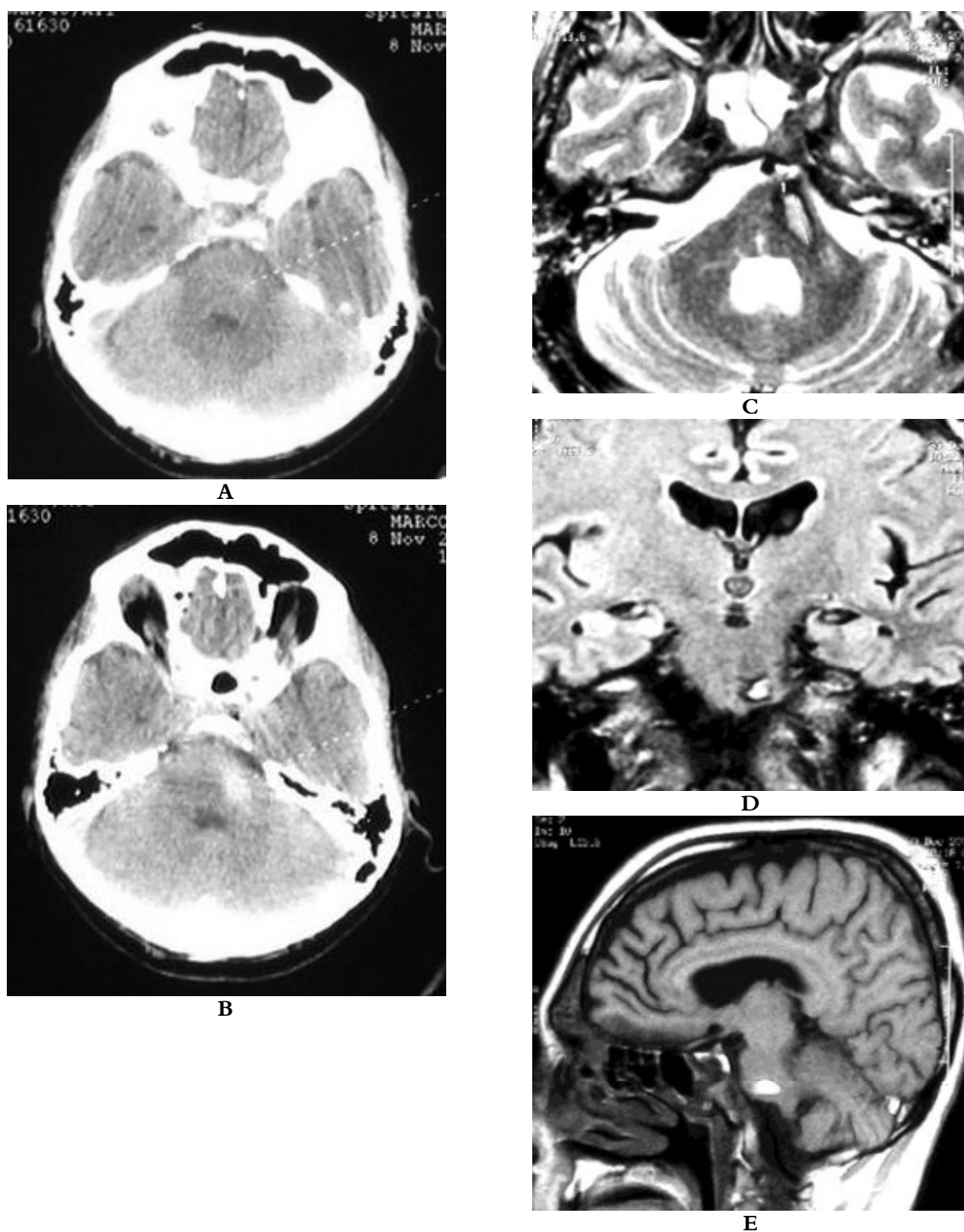


Figure 1 Pontin cavernoma, unverified operator in a patient found incidentally 35 years after a car accident: **A, B** – CT scan; **C, D, E** - MRI T2 axial section, T1 sagittal and T1 coronary section in the same patient with pontin cavernoma (PDS).

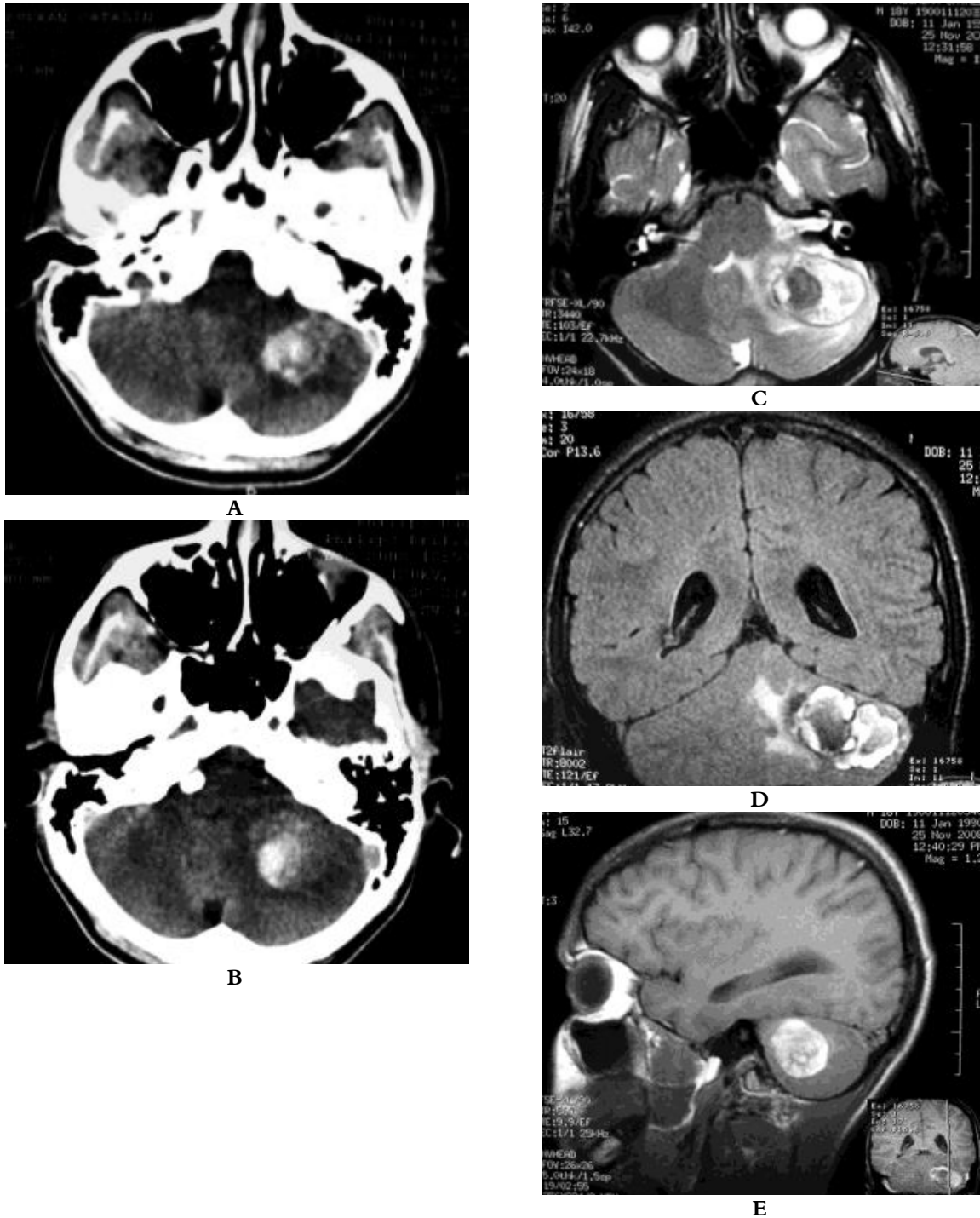
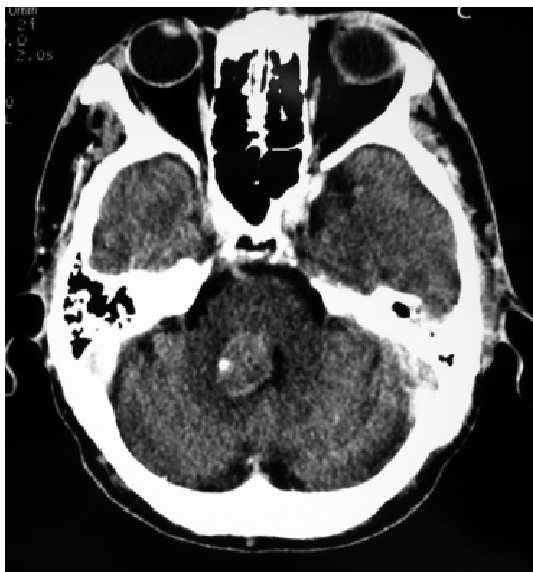

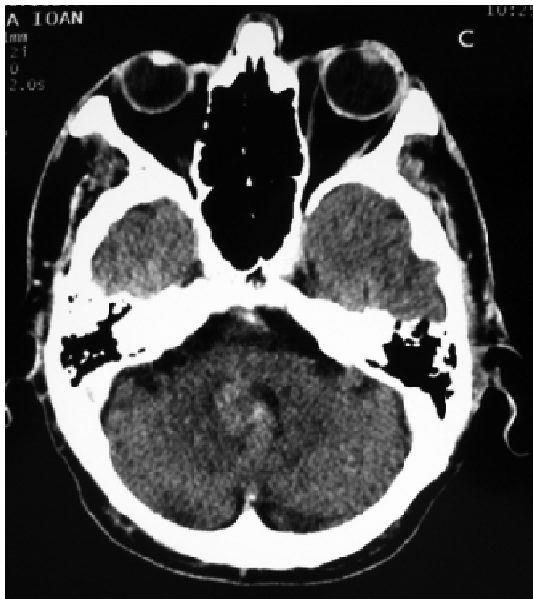Figure 2 Left cerebellar cavernoma (P.C., men, 18 years old): **A, B** – CT scan; **C, D, E** – MRI T2 axial section, T1 coronary and T1 sagittal section.

Brainstem cavernomas are considered a special pathology given the risk of hemorrhage that is 30 times that of cavernomas elsewhere located, and the neurological deficits associated to hemorrhage.

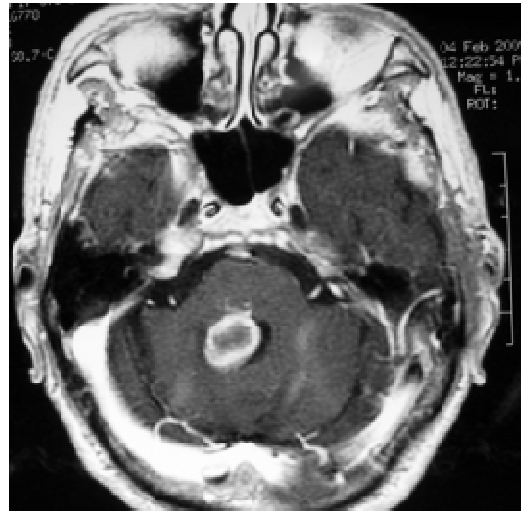Intraventricular cavernomas (Figure 3) was reported in literature to account for 2,5 to 10,8% of brain cavernomas.



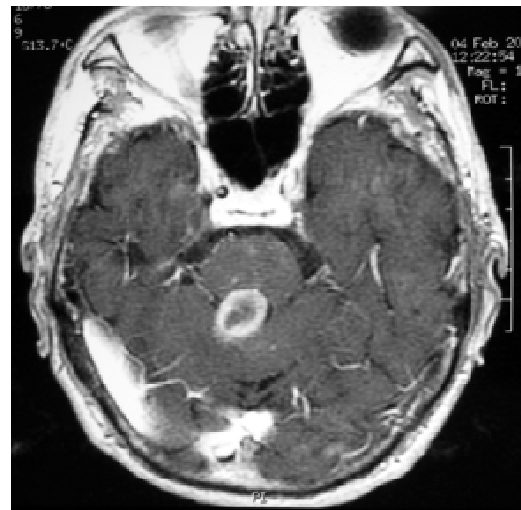
A



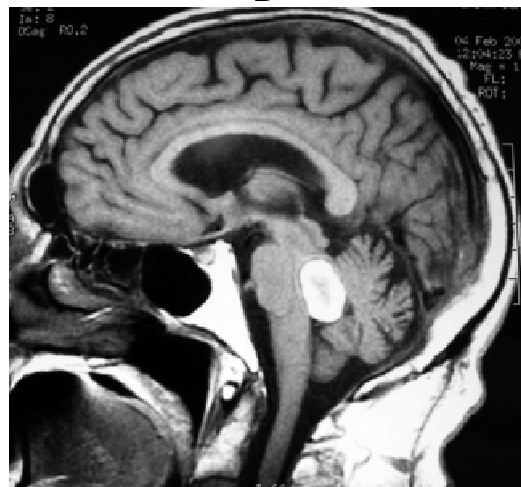B



C



D



E

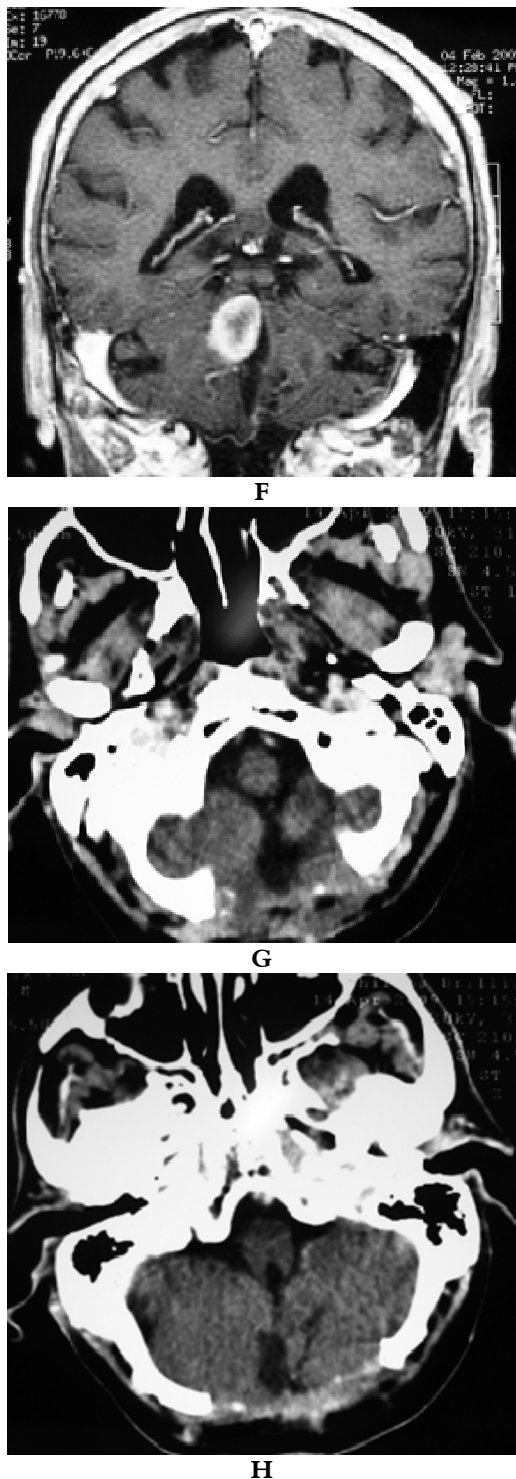


Figure 3 IV ventricle cavernoma operated (63 years old, sex M): **A, B** – CT scan; **C, D, E, F** – brain MRI (N+K); **G, H** – postoperative CT scan

Even small changes in brainstem cavernomas silent on MRI can cause major neurological deficits (23, 39). In the natural history of brainstem cavernomas contradicting characteristics have been reported. Some studies reported a benign tumor behavior (24), with a bleeding rate of 2.46% per year and a rebleeding rate of 5.1% per year, while other studies (40) reported a malignant natural history with a rate of rebleeding of 5% per year, and a rebleeding rate of 30%. The correct clinical evaluation and treatment of infratentorial cavernomas is based on hemorrhagic and neurological associated risk understanding, and also the factors that influence this risk. This study is aimed to review the knowledge on the natural history of infratentorial cavernomas and to make it ready usable for the neurosurgeon in treating these patients.

Methods

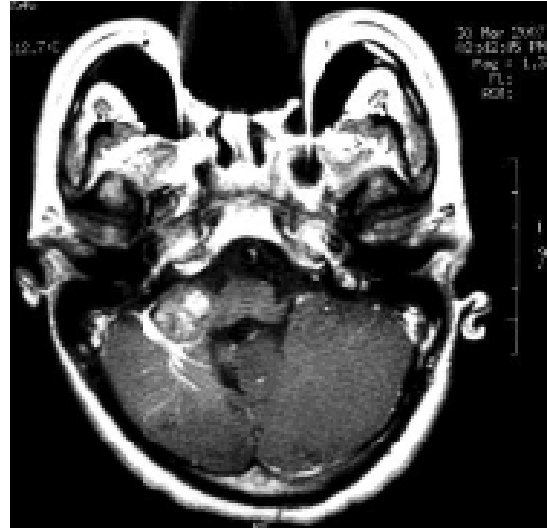The literature data was selected and sorted from PubMed, using the keywords “natural history”, “cavernous malformation”, “cavernoma”, “cavernous angioma”, “cavernous hemangioma”, “hemorrhagic risk”, “neurologic risk”. This review was limited to studies published in English. The studies that provided information regarding the clinical presentation, risk of hemorrhage and prognostic factors (age, sex, dimension, and genetics) were investigated.

Epidemiology

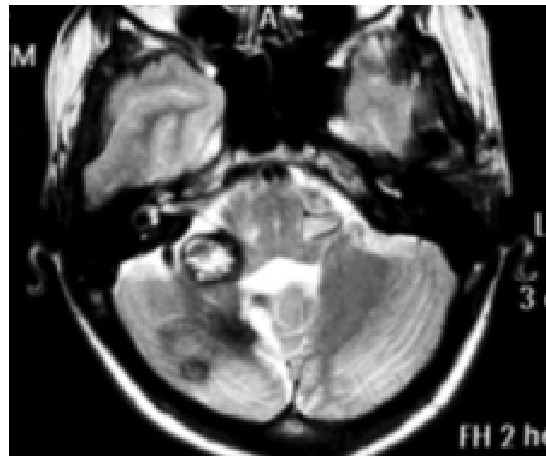
There is no reliable study to offer precise information about the incidence and the prevalence of cavernomas. Based on cadaveric studies and IRM images, the prevalence was estimated 0.5% - 0.7% (15, 43). The incidence of cavernomas was

estimated to 0,4% and 0,9%, accounting for 8% - 15% of all intracranial vascular malformations. (15, 22, 32, 39). There is no gender difference even if some studies showed a small difference in favor of women (1, 23, 35, 40, 44, 48, 49). Up to 25% of cavernomas appear in pediatric population. More than 60% are superficial, 30% are profound (brainstem, cerebellar nuclei basal ganglia and thalamus) and 3% are located in spinal medulla. Multiple cavernomas appear in 90% of familial forms and in approx. 25% of sporadic forms (12, 26). In average, 20% of cavernomas appear in posterior cranian fossa and 80% are supratentorial. The frequency of brainstem cavernoma is reported to be somewhere between 9% - 35% (24, 40). The average size of cavernomas is between 15 - 19 mm (22, 43). Only 10% of lesions remain unmodified in time; 35% grow and 55% shrink (12). This dynamic is related to recurrent bleeding and resorbtion of blood products or to changes in osmotic pressure (52). More and more authors agree to the presence of a subgroup of *de novo* cavernomas. (36).

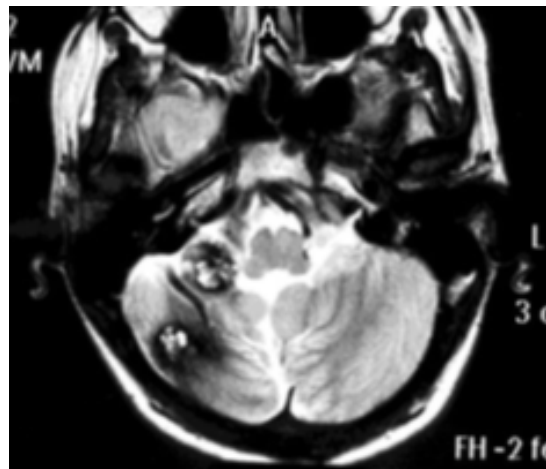
They can be frequently associated with venous angiomas (Figure 4), this relationship is more frequent in infratentorial types (18, 40). The large percent of associated lesions determined some authors to consider that the venous anomaly determines the cavernoma formation. (the affected venous drainage can take to capillary channels dilation). This theory is sustained by a rare observation: the cavernoma recurrence post resection was not reached in patients with associated DVA. (51).



A



B



C

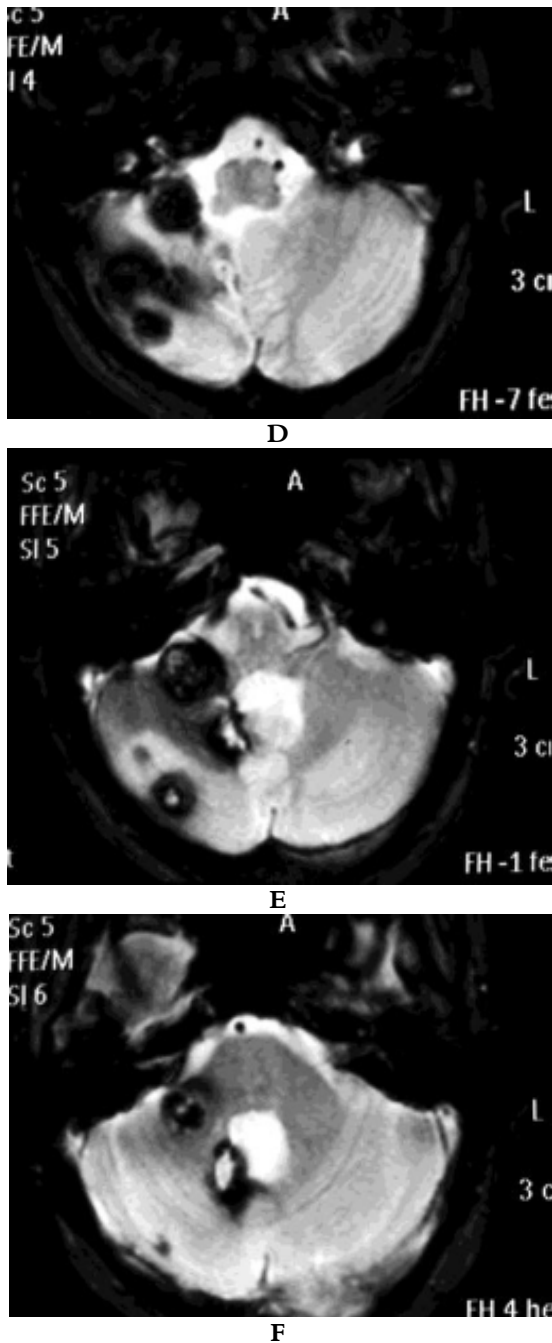


Figure 4 Appearance MRI on three years after total resection of a cavernoma of the vermis and highlighting the marked increase in size of the three right cerebellar hemisphere cavernomas, placed around the venous angioma. Cavernomas was resected surgical and the angioma was treated conservatively: **A** – T1 axial section, **B, C, D, E**, - T2 gradient echo axial section.

Pathophysiology

Cavernomas pathophysiology stands in a slow degradation of blood in cerebral parenchyma resulting in a hemosiderin ring, and perilezional gliosis. Almost all cavernous malformations have signs of recent hemorrhage. In contrast with a spontaneous intracerebral hemorrhage associated with hypertension, little is known about the physiopathology of cavernoma bleeding.

Most of the microhemorrhages appear intralezional and this is the cavernomas growth mechanism, usually this microhemorrhage is asymptomatic. The situation of extralezional bleeding from a cavernoma is rare, it is cause for a intraparenchimal hematoma, usually being nonfatal, given the diminished blood flow and pressure inside the cavernoma. (46). Infratentorial cavernomas have a bleeding rate bigger than the supratentorial ones but the cause. Mechanisms of cavernomas volume growth (11):

- Acute massive hemorrhage with sudden volume growth and mass effect or repeated small bleedings and thrombosis taking to a growing cystic lesion (41);

- Chronic hemorrhage from thin walled vessels, with repeated reendotelisation, of the bleeding cavity, angiogenesis inside the developed hematoma, and perilezional matrix growth (30, 45);

- Intraluminal thrombosis with recanalization and organization (42);

- Angiogenesis proliferation with new capillaries as a phenomenon of reactive angiogenesis and consecutive neovascularization by coalescence (30);

- Hemorrhage by adjacent cerebral parenchymal vessels erosion (33);

- Immunohistochemical demonstrated proliferation (37,47);

- Nidus growth by new caverns formation (17, 27);
- Vascular smooth muscle proliferation (3);

Presentation

Patients with cavernomas have a rich symptomatology with onset between 30 - 50 years old. Bleeding inside the cavernoma and the compressive effect according to localization and dimensions are the mechanisms of clinical signs. The hemorrhage determines neurologic deficits depending on the location of the lesion, for example a bleeding from a brainstem cavernoma can result in cranial nerve deficits, like diplopia, facial palsy, vertigo, ophthalmoplegia, tinnitus, hearing loss, dysarthria and dysphagia. Brainstem syndromes even as a consequence of ischemic lesions can be elicited also by cavernomas, according to their localization: Wallenberg syndrome, Millard-Gubler syndrome, Weber syndrome, Benedikt syndrome or Parinaud syndrome. Cerebellar hemorrhages in cerebral peduncles or on cerebellar can result in ataxia or nistagmus, but also cerebellar mutism was described. Cerebellar hemorrhage can also result in IVth ventricle obstruction and hydrocephalus. Important hemorrhage in brainstem or pons cause loss of consciousness, coma and eventually death. The pons is a well-known site of fatal intracranial hemorrhage. All these neurological deficits can result from cavernomas through their compressive effect without bleeding, having a slowly progressive course that can lead to diagnostic confusion, without a complete imaging they mimic a clinical setting of multiple sclerosis or pontine glioma (34). Headache is a usual but nonspecific sign in infratentorial cavernomas. It is a very rare

situation for the brainstem cavernomas to produce seizures. The frequency of asymptomatic cavernomas is not precisely defined but according to Zabramski (52) and Brunereau (9, 10) it seems to be even more than 40%.

Natural history

At the beginning of 1990 (once the MRI became widely available) the hemorrhagic risk associated with brain cavernoma, was more and more accepted. (15).

The hemorrhagic pattern presents a great variability with many terms that define the hemorrhagic event in literature (1, 2, 6, 15, 16, 23, 38, 41, 43, 44, 54). Hemorrhage is the main problem also from a clinical and a therapeutic point of view. Even if this problem seems facile some hypothesis are wrong. The problem starts with a definition for hemorrhage and ends in particular responses for every patient. On one side, the hemorrhage can be defined based on clinical status: de novo or sudden onset of new symptoms in a cavernoma patient, resulted from a rebleeding episode. There are many descriptions and many terms used in literature to define a hemorrhage associated with cavernoma: clinical significant cavernoma; symptomatic hemorrhage, important hemorrhage, microhemorrhage, intralezional diapedesis, or perilezional clinical significant hemorrhage, subclinical hemorrhage, etc. (1, 20, 23, 8). Still the problem of hemorrhage in cavernomas is a reason for debate regarding the risk of hemorrhage and the rate of rebleeding in patients with cavernomas. Most of the estimates take into account the fact that cavernomas are present at birth and they base the appreciation of the risk of hemorrhage and risk of rebleeding on this supposition.

Del Curling et al. (15) and de Robinson et al. (43) were the first to calculate the annual rate of hemorrhage, between 0,25% and 0,7% / year.

Hemorrhage risk factors

Hemorrhagic onset (hemorrhagic presentation) has a negative impact on the natural history of cavernoma. Patients with a hemorrhagic onset have a higher risk of rebleeding than patients with some other symptomatic onset or accidentally diagnosed, 22,9 per year, compared to 0,39% per year (1, 23). Other studies (31, 35) did not recognize the presence of hemorrhage as an independent risk factor, but observed that patients with hemorrhagic or non-hemorrhagic onset associated with focal neurological deficit had higher rebleeding rates than those without neurological deficits. (8,9% compared to 0,4% /patient-year). A spontaneous drop off of the rebleeding risk after approximately 2 years after a hemorrhagic episode was remarked, the so called “temporal clustering” phenomenon (5,50).

Anatomic location. A higher rate of symptomatic recurrent hemorrhage was reported related to infratentorial location than in supratentorial location (39), 3,8%/patient/year compared to 0,4%/patient/year, also a higher incidence of invalidant neurological deficits in infratentorial location compared to supratentorial ones (44). Patients with supratentorial cavernomas have a low probability of fatal hemorrhage, most of the patients having a complete or almost complete recovery after the first hemorrhagic episode, but this situation is not true for infratentorial location where a hemorrhage, especially in pons can be fatal. In Fritschi's (17), series of 139 brainstem

cavernomas a high rate of symptomatic hemorrhage of 2,7% /patient/year and 21% /patient/year rebleeding rate was encountered.

In the series published by Porter (40), the symptomatic hemorrhage rate and the symptomatic rebleeding rate are even higher 5%/patient/year respectively 30%/patient/year.

Female sex. Some authors (4, 40, 43) reported a significant growth of the hemorrhage rate in women, but in most of them the gender difference wasn't significant. (17, 23, 39).

De novo development. Initially all cavernomas were thought to be congenital. There are many proofs of de novo cavernoma development. Radiotherapy is one of the factors in favor of de novo cavernoma formation (36), along with genetic factors, viruses, hormonal influences during pregnancy, and local dissemination at biopsy. De novo cavernoma formation was recently confirmed based on MRI studies in patients with familial form. Even more studies counted the de novo cavernoma formation incidence between 0,1 and 0,6 new lesions /patients/year (21, 25, 52). This phenomenon is much more frequent in familial than in sporadic form, respectively 27,5%-30% of the patients with familial form have de novo cavernomas while only 4,1% of patients with sporadic form develop de novo cavernomas with time (25, 26,41).

Size Dynamics. De novo cavernoma formation isn't the sole dynamic aspect of cavernomas, they can also report important growth with time. The best study to prove the dynamics of cavernomas is that of Clatterbuck (12), who observed 68 patients with 114 cavernomas, on MRI on an average period of 3,7 years. He concluded

that 22% of lesions were stable, 43% reported growth and 35% shrinkage. There is no study so far to associate the growth of cavernomas with the risk of hemorrhage.

Inherited form. Even if most of the cavernomas are considered to be sporadic, more and more familial cases were observed in the last two decades. These cases have an autosomal dominant inheritance, and are most common in hispanic population. Recent studies showed at least 3 distinct genes related to the familial form of disease, two of them being precisely located.

The first gene is CCM1 (cavernous cerebral malformation 1) and is located on chromosomal 7 at 7q11.2-q21 locus. Another known gene is KRIT1, named after the corresponding protein Gene CCM1 is present in 40% of familial cavernomas. The precise function of KRIT1 is unknown it is probably a tumor suppressor (13, 14, 19, 28, 53). The second gene is CCM2. This is located at 7p15-p13 and it codifies the protein malcaverin. About 20% of familial forms may be related to a mutation in CCM2. The third gene identified is CCM3, located on chromosome 3 at 3q. The function of this gene and its association with cavernoma is still under research. All the 3 genes seem to have implications in angiogenesis. As from 2004 January tests for CCM 1 mutations are available and in short time tests for CCM 2 will be available. Recent studies suggest the presence of another gene (7, 29). Also genetic etiologies were demonstrated in familial forms in 70% of cases the genetic influence is yet to be established in sporadic forms. Sporadic forms can be caused by a loss of function of CCM1 in heterozygotes. The familial form may influence the risk of hemorrhage; given the multiple cavernomas and the high

de novo formation rate, in spite of the fact that no higher hemorrhagic rate has been identified per lesion.

Analyzing the literature data on hemorrhage related to brainstem cavernoma we can conclude:

- patients with brainstem cavernoma have a significantly higher risk of hemorrhage of 5%/year (40), even if some authors found smaller rates (24), of only 2.46%/year;
- the rate of rebleeding after a symptomatic hemorrhage is 30% per year (40);
- the rate of bleeding is not related with patients gender (1,35,43);
- young age (under 35 years) seems to be related to a higher rate of bleeding (24);
- cavernomas with dimensions of at least 10 mm have a higher risk of bleeding (24)
- morbidity rate in brainstem cavernomas is 8% (24).

Conclusions

Decision making in infratentorial cavernomas treatment is strictly related to the surgical morbidity and the risks in the natural history of the disease. Prospective data in literature to predict the evolution for every individual patients are lacking so far. A metaanalysis over a long period of time is required to elucidate the natural history of brainstem cavernomas and to identify the cavernomas with high potential of neurologic deficits. A good understanding of the natural history provides the surgeon the ability to evaluate the relative risk associated to every treatment method. For infratentorial cavernomas, the analysis of the relative risk is very difficult given the sparse cases reported in literature and the statistical analysis that limits any. In addition, any reported case has an

individual variability like the clinical and neurological status, age, associated disease, accessibility according to location. Moreover the experience that the neurosurgeon has in treating these lesions is what matters.

References

1. Aiba T, Tanaka R, Koike T, Kameyama S, Takeda N, Komata T: Natural history of intracranial cavernous malformations. *J Neurosurg* 1995, 83:56–59
2. Awad IA: Cavernous malformations and epilepsy, in Awad IA, Barrow DL (eds): *Cavernous Malformations*. Park Ridge, AANS, 1993, 49–63
3. Awad IA, Robinson JR, Mohanty S, Esters ML: Mixed vascular malformations of the brain: clinical and pathogenetic considerations. *Neurosurgery* 1993, 33:179–188
4. Awad I, Jabbour P: Cerebral cavernous malformations and epilepsy. *Neurosurg Focus* 2006, 21:1e7
5. Barker FG II, Amin-Hanjani S, Butler WE, Lyons S, Ojemann RG, Chapman PH, et al.: Temporal clustering of hemorrhages from untreated cavernous malformations of the central nervous system. *Neurosurgery* 2001, 49:15–25
6. Barrow DL, Krisht A: Cavernous malformations and hemorrhage, in Awad IA, Barrow DL (eds): *Cavernous Malformations*. Park Ridge, AANS, 1993, 65–80
7. Bergametti F, Denier C, Labauge P, Arnoult M, Boetto S, Clanet M, et al.: Mutations within the programmed cell death 10 gene cause cerebral cavernous malformations. *Am J Hum Genet* 2005, 76:42–51
8. Biller J, Toffol GJ, Shea JF, Fine M, Azar-Kia B: Cerebellar venous angiomas. *Arch Neurol* 1985, 42:367–370
9. Brunereau L, Labauge P, Tournier Lasserre E, Laberge S, Levy C, Houtteville J: Familial form of intracranial cavernous angioma: MR imaging findings in 51 families. *French Society of Neurosurgery. Radiology* 2000a, 214:209–216
10. Brunereau L, Levy C, Laberge S, Houtteville J, Labauge P: De novo lesions in familial form of cerebral cavernous malformations: clinical and MR features in 29 non-Hispanic families. *Surg Neurol* 2000b, 53(5):475–482
11. Ciurea A.V., Coman T.C., Gambardella G.: *Actualități în cavernoamele intracraniene*, Editura Universtară “Carol Davila”, București, 2005, 41–46
12. Clatterbuck RE, Moriarity JL, Elmaci I, Lee RR, Breiter SN, Rigamonti D: Dynamic nature of cavernous malformations: a prospective magnetic resonance imaging study with volumetric analyses. *J Neurosurg* 2000, 93:981–986
13. Craig HD, Gunel M, Cepeda O, et al. Multilocus linkage identifies two new loci for a mendelian form of stroke, cerebral cavernous malformation, at 7p15-13 and 3q25.2-27. *Hum Mol Genet*. Nov 1998, 7(12):1851-8.
14. Davenport WJ, Siegel AM, Dichgans J, Drigo P, Mammi I, Pereda P, Wood NW, Rouleau GA: CCM1 gene mutations in families segregating cerebral cavernous malformations. *Neurology* 2001, 56:540–543
15. Del Curling O, Kelly DL, Elster AD, Craven TE: An analysis of the natural history of cavernous angiomas. *J Neurosurg* 1991, 75:702–708
16. Ferroli P, Sinisi M, Franzini A, Giombini S, Solero CL, Broggi G: Brainstem cavernomas: long-term results of microsurgical resection in 52 patients. *Neurosurgery* 2005, 56:1203–1214
17. Fritschi JA, Reulen HJ, Spetzler RF, Zebramski JM: Cavernous malformations of the brainstem. A review of 139 cases. *Acta Neurochir* 1994, 130:35–46
18. Forsting M, Wanke I: *Developmental Venous Anomalies, IN: Intracranial Vascular Malformations and Aneurysms*, Springer 2007, 1–18
19. Gaetzner S, Stahl S, Sürücü O et al: CCM1 gene deletion identified by MLPA in cerebral cavernous malformation. *Neurosurgical Review*, 2007, 30(2):155–160
20. Karlsson B, Kihlstrom L, Lindquist C, Ericson K, Steiner L: Radiosurgery for cavernous malformations. *J Neurosurg* 1998, 88:293–297
21. Kattapong VJ, Hart BL, Davis LE: Familial cerebral cavernous angiomas: clinical and radiologic studies. *Neurology* 1995, 45:492–497,
22. Kim DG, Park YG, Choi JU, Chung SS, Lee KC: An analysis of the natural history of cavernous malformations. *Surg Neurol* 1997, 48:9–18
23. Kondziolka D, Lunsford LD, Kestle JR: The natural history of cerebral cavernous malformations. *J Neurosurg* 1995, 83:820–824
24. Kupersmith MJ, Kalish H, Epstein F, Yu G, Berenstein A, Woo H, Jafar J, Mandel G, De Lara F: Natural history of brainstem cavernous malformations. *Neurosurgery* 2001, 48:47–53
25. Labauge P, Brunereau L, Levy C, Laberge S, Houtteville JP: The natural history of familial cerebral cavernomas: a retrospective MRI study of 40 patients. *Neuroradiology* 2000, 42:327–332
26. Labauge P, Brunereau L, Laberge S, Houtteville JP: Prospective follow-up of 33 asymptomatic patients with familial cerebral cavernous malformations. *Neurology* 2001, 57:1825–1828
27. Little JR, Awad IA, Jones SC, Ebrahim ZY: Vascular pressure and cortical blood flow in cavernous angiomas of the brain. *J Neurosurg* 1990, 73:555–559

28. Liquori CL, Berg MJ, Siegel AM, et al. Mutations in a gene encoding a novel protein containing a phosphotyrosine-binding domain cause type 2 cerebral cavernous malformations. *Am J Hum Genet.* Dec 2003, 73(6):1459-64.
29. Liquori CL, Berg MJ, Squitieri F, Ottenbacher M, Sorlie M, Leedom TP, et al.: Low frequency of PDCD10 mutations in a panel of CCM3 probands: potential for a fourth CCM locus. *Hum Mutat* 2006, 27:118
30. Maraire JN, Abdulrauf SI, Berger S, Knisely J, Awad IA: De novo development of a cavernous malformations of the spinal cord following spinal axis radiation. Case report. *J Neurosurg* 1999, 90:234-238
31. Mathiesen T, Edner G, Kihlström L: Deep and brainstem cavernomas: a consecutive 8-year series. *J Neurosurg* 2003, 99:31-37
32. McCormick WF, Nofzinger JD: "Cryptic" vascular malformations of the central nervous system. *J Neurosurg* 1966, 24:865-875
33. Michelson WJ: Conservative treatment. In: Awad IA, Barrow DL (eds): *Cavernous malformations*. AANS, Park Ridge, 1993, 81-85
34. Ming X, Gonzales C, Burrows D, Lastra C, Antunes N: Cavernous angioma of the brain stem simulating diffuse pontine glioma. *J Child Neurol.* 2001, 16:614-615
35. Moriarity JL, Wetzel M, Clatterbuck RE, Javedan S, Sheppard JM, Hoening-Rigamonti K, et al.: The natural history of cavernous malformations: a prospective study of 68 patients. *Neurosurgery* 1999, 44:1166-1173
36. Nimjee SM, Powers CJ, Bulsara KR: Review of the literature on de novo formation of cavernous malformations of the central nervous system after radiation therapy. *Neurosurg Focus* 2006, 21(1)
37. Notelet L, Houtville JP, Khoury S, Lechevalier B, Chapon F: Proliferating cell nuclear antigen (PCNA) in cerebral cavernomas: an immunocytochemical study of 42 cases. *Surg Neurol* 1997, 47:364-70
38. Otten P, Pizzolato GP, Rilliet B: 131 cases of cavernous angiomas (cavernomas) of the CNS, discovered by retrospective analysis of 24,535 autopsies. *Neurochirurgie* 1989, 35:82-83
39. Porter PJ, Willinsky RA, Harper W, Wallace MC: Cerebral cavernous malformations: Natural history and prognosis after clinical deterioration with or without hemorrhage. *J Neurosurg* 1997, 87:190-197
40. Porter RW, Detwiler PW, Spetzler RF, Lawton MT, Baskin JJ, Derksen PT et al.: Cavernous malformations of the brainstem: experience with 100 patients. *J Neurosurg* 1999, 90:50-58
41. Pozzati E, Acciarri N, Tognetti F, Marliani F, Giangaspero F: Growth, subsequent bleeding, and de novo appearance of cerebral cavernous angiomas. *Neurosurgery* 1996, 38:662-670
42. Rigamonti D, Hadley MN, Drayer BP, Johnson PC, Hoening-Rigamonti K, Knight JT, Spetzler RF: Cerebral cavernous malformations. Incidence and familial occurrence. *N Engl Med* 1998, 319:343-347
43. Robinson JR, Awad IA, Little JR: Natural history of the cavernous angioma. *J Neurosurg* 1991, 75:709-714
44. Robinson JR, Awad IA, Magdinec M, Paranandi L: Factors predisposing to clinical disability in patients with cavernous malformations of the brain. *Neurosurgery* 1993, 32:730-736
45. Scott BB, Seeger JF, Schneider RC: Successful evacuation of a pontine hematoma secondary to rupture of a pathologically diagnosed "cryptic" vascular malformation. Case report. *J Neurosurg* 1973, 39:104-108
46. Shiu-Jau Chen et al: Cavernoma of the Central Nervous System: Surgical experience in the magnetic resonance imaging era; *Acta Neurol Taiwan* 1997, 6:171-178
47. Sure U, Butz N, Schlegel J, Siegel A, Mennel HD, Bien S, Bertalanffy H: Endothelial proliferation, neuroangiogenesis and potential de novo generation of cerebral vascular malformations. *J Neurosurg* 2001, 94:972-977
48. Vaquero J, Leunda G, Martínez R, Bravo G: Cavernomas of the brain. *Neurosurgery* 1983, 12:208-210
49. Voigt K, Yasargil MG: Cerebral cavernous haemangiomas or cavernomas. Incidence, pathology, localization, diagnosis, clinical features and treatment. Review of the literature and report of an unusual case. *Neurochirurgia (Stuttg)* 1976, 19:59-68
50. Wang CC, Liu A, Zhang JT, Sun B, Zhao YL: Surgical management of brain-stem cavernous malformations: report of 137 cases. *Surg Neurol* 2003, 59:444-454
51. Wurm G, Schnizer M, Nussbaumer K, Wies W, Holl K: Recurrent cryptic vascular malformation associated with a developmental venous anomaly. *Br J Neurosurg* 2003, 17(2):188-195
52. Zabramski JM, Wascher TM, Spetzler RF, Johnson B, Golfinos J, Drayer BP, Brown B, Rigamonti D, Brown G: The natural history of familial cavernous malformation: results of an ongoing study. *J Neurosurg* 1994, 80:422-432
53. Zhang J, Clatterbuck RE, Rigamonti D, Dietz HC: Mutations in KRIT1 in familial cerebral cavernous malformations. *Neurosurgery* 2000, 46:1272-1277
54. Zimmerman RS, Spetzler RF, Lee KS, Zabramski JM, Hargraves RW: Cavernous malformations of the brain stem. *J Neurosurg* 1991, 75:32-39