

## Pituitary apoplexy with intraventricular hemorrhage: clinical presentation, treatment and outcome, case report

Adriana Dediu<sup>1</sup>, Ligia Tataranu<sup>2</sup>, Mircea Radu Gorgan<sup>2</sup>

<sup>1</sup>PhD Student in Neurosurgery, "Carol Davila" UMPH Bucharest

Faculty of Medicine, Department of Neurosurgery

<sup>2</sup>First Neurosurgical Clinic, Fourth Department of Neurosurgery

Emergency Clinical Hospital Bagdasar-Arseni, Bucharest

### Abstract

*Background:* Pituitary tumor apoplexy is a clinical syndrome characterized by abrupt onset of a severe headache, nausea, vertigo, meningismus, and/or decreased level of consciousness.

*Case report:* we report a case of a 56-year old man presented to medical attention with sudden severe headache, nausea, vomiting, dizziness, diplopia and blurring of vision. Computer tomography and contrast-enhanced magnetic resonance imaging of the head proved a large sellar tumor with extension to the sphenoid sinus, suprasellar region and both cavernous sinuses, predominantly on the right side with intratumoral hemorrhagic zones and the hemorrhagic accumulation in the posterior horns of the lateral ventricles.

The treatment of choice was transsphenoidal approach and the patient was discharged in a good condition, completely oriented, without other neurological signs.

*Conclusions:* Pituitary apoplexy remains a potentially life-threatening disease. Its presentation may vary from relatively benign symptoms to major neurological deficits and even death. Its early recognition and treatment are vital.

**Keywords:** pituitary apoplexy,

intraventricular hemorrhage, infarction, hemorrhage

### Background

Pituitary tumor apoplexy is an uncommon but well-described clinical syndrome characterized by a constellation of severe signs and symptoms like: sudden headache, visual impairment, restriction of visual fields, paresis of ocular muscles, impaired consciousness. Clinical syndrome is generally consequent to the following: subarachnoid extravasation of blood and dural irritation, cranial nerve and hemispheric compression from lateral or superior extension of necrotic and/or hemorrhagic material, endocrine abnormalities from acute pituitary dysfunction. (9, 11)

Clinical presentation of pituitary apoplexy varies from a clinically relatively benign event to a catastrophic episode with severe neurological deficit, endocrine failure, or even death. (9)

Computer tomography scans may reveal the hyperdensity of acute hemorrhage if obtained within 3 or 4 days after the event or demonstrate the mixed density of acute blood and necrotic tissue. The greater sensitivity, precision, and tissue definition of MR imaging usually reveal the

heterogeneous intensity of hemorrhage, edematous pituitary gland, and necrotic tissue, leading more readily to a diagnosis.(9)

The transsphenoidal approach is safe and efficient choice for treating pituitary apoplexy. The vulnerable optic pathway, which is severely compressed and which becomes edematous during the acute stage should not be directly manipulated through the transcranial approach but should be decompressed by transsphenoidal surgery.(1)

### **Case report**

This 56-year old man presented to medical attention with sudden severe headache, nausea, vomiting, dizziness, diplopia and blurring of vision. One day later the patient was admitted to the neurosurgical department of our institution.

Examination On examination the patient was confused, sometimes excited, and disoriented as to place, time, and situation, the symptoms of intracranial hypertension was also present. Blood pressure was 120/80 mmHg, and the pulse rate 110 beats/min. Ophthalmological examination revealed that there was ptosis on the right eyelid, the right eye was deviated outward and slightly downward. We also found a dilated nonreactive pupil and paresis of accommodation on the right eye. The visual acuity of both eyes was reduced; there was no visual field defects. The funduscopic examination was normal.

Neurological examination showed positive meningeal symptoms. The remainder of the physical examination was normal.

Emergent computer tomography (Figure 1) and contrast-enhanced magnetic

resonance imaging (Figure 2) of the head was performed and demonstrated a large sellar tumor with extension to the sphenoid sinus, suprasellar region and both cavernous sinuses, predominantly on the right side. We noted the intratumoral hemorrhagic zones and the hemorrhagic accumulation in the posterior horns of the lateral ventricles. The CT and IRM scans showed a right temporal arachnoid cyst.

The endocrinological testing was also performed and did not reveal any abnormalities.

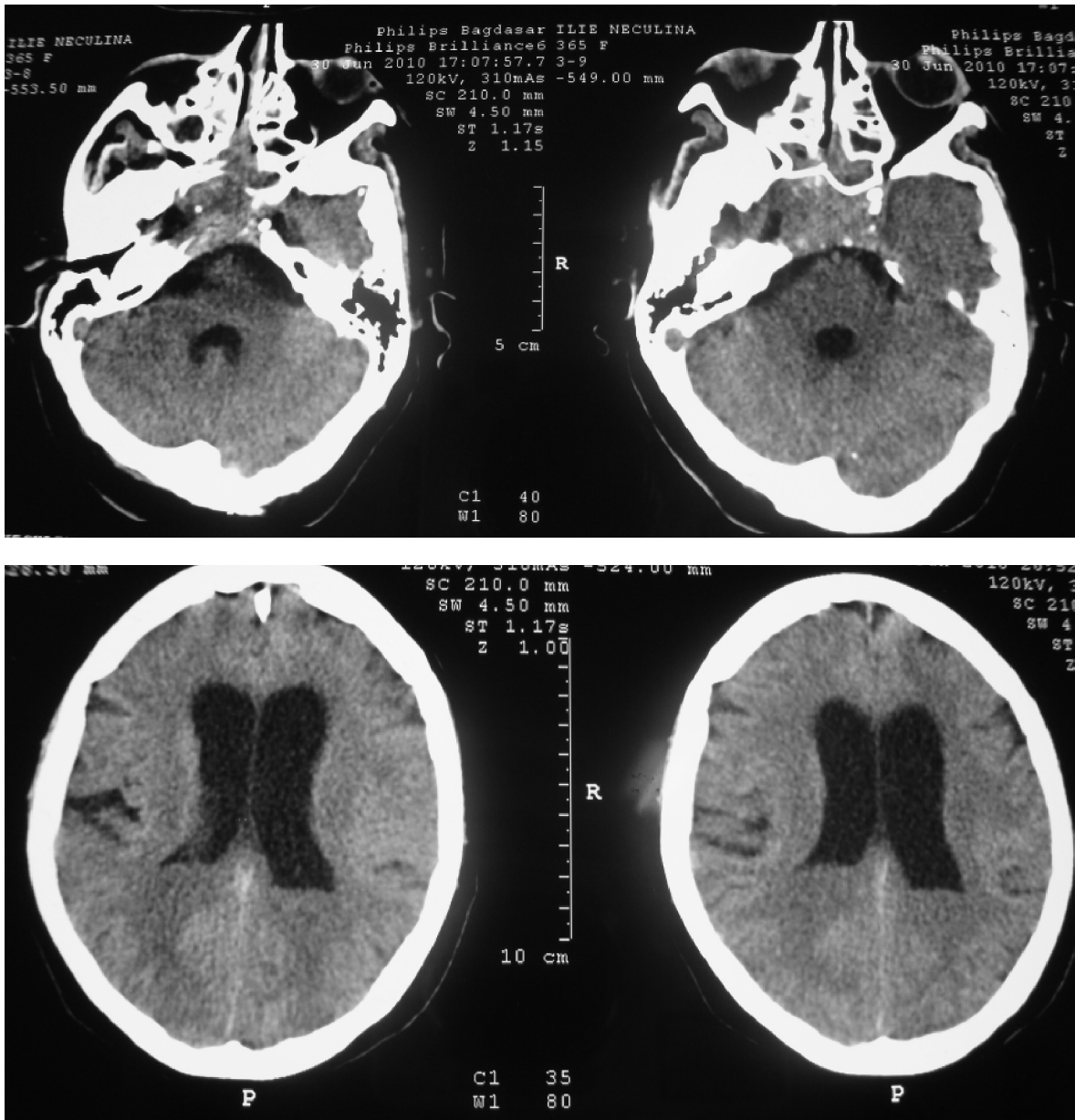
### ***Surgical approach***

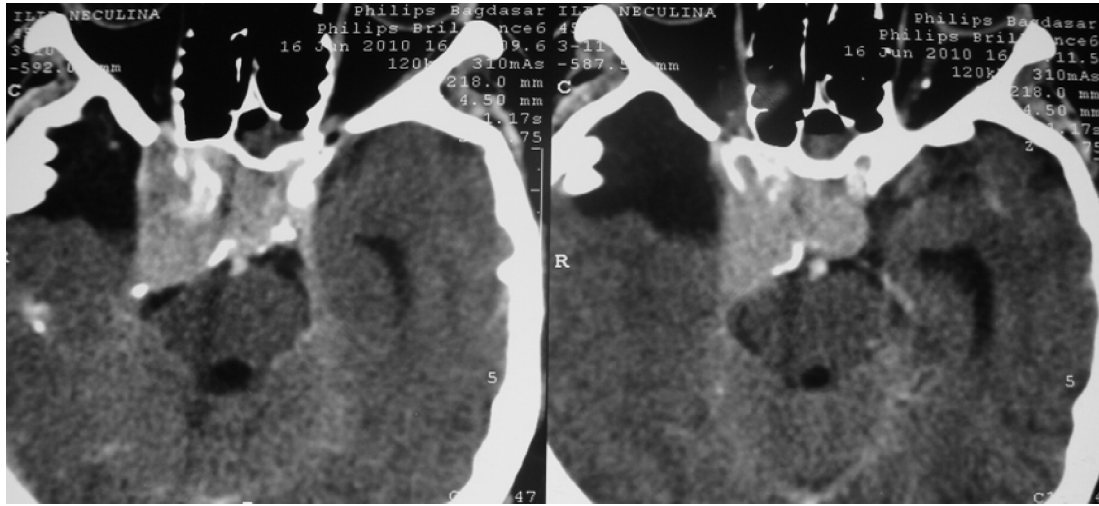
The surgery was performed promptly. In this case we chose the emergent transnasal transsphenoidal approach combined with steroid treatment. The transsphenoidal surgery was carried out under general anesthesia and oral endotracheal intubation. Prior to operation the nasal mucosa was infiltrated with saline solution in order to lessen bleeding and to facilitate dissection of the mucosa from the septum. Under microscopic magnification, using a nasal speculum the septal mucosa was incised in a superoinferior direction.

Dissection was carried out posteriorly along the septum until the sphenoid prow was identified. The cartilaginous septum is fractured toward the contralateral side. In this stage we identified the anterior wall of the sphenoid sinus which was resected. After the anterior sphenoidotomy was performed and the sphenoid mucosa was removed we saw the entire cavity of the sinus filled with tumor – a heterogeneous, reddish mass with hemorrhagic parts and fluid texture. After this portion of tumor was removed we moved to the intrasellar part of the tumor. First we removed the inferior part of the intrasellar tumor, then the lateral part was resected beginning on

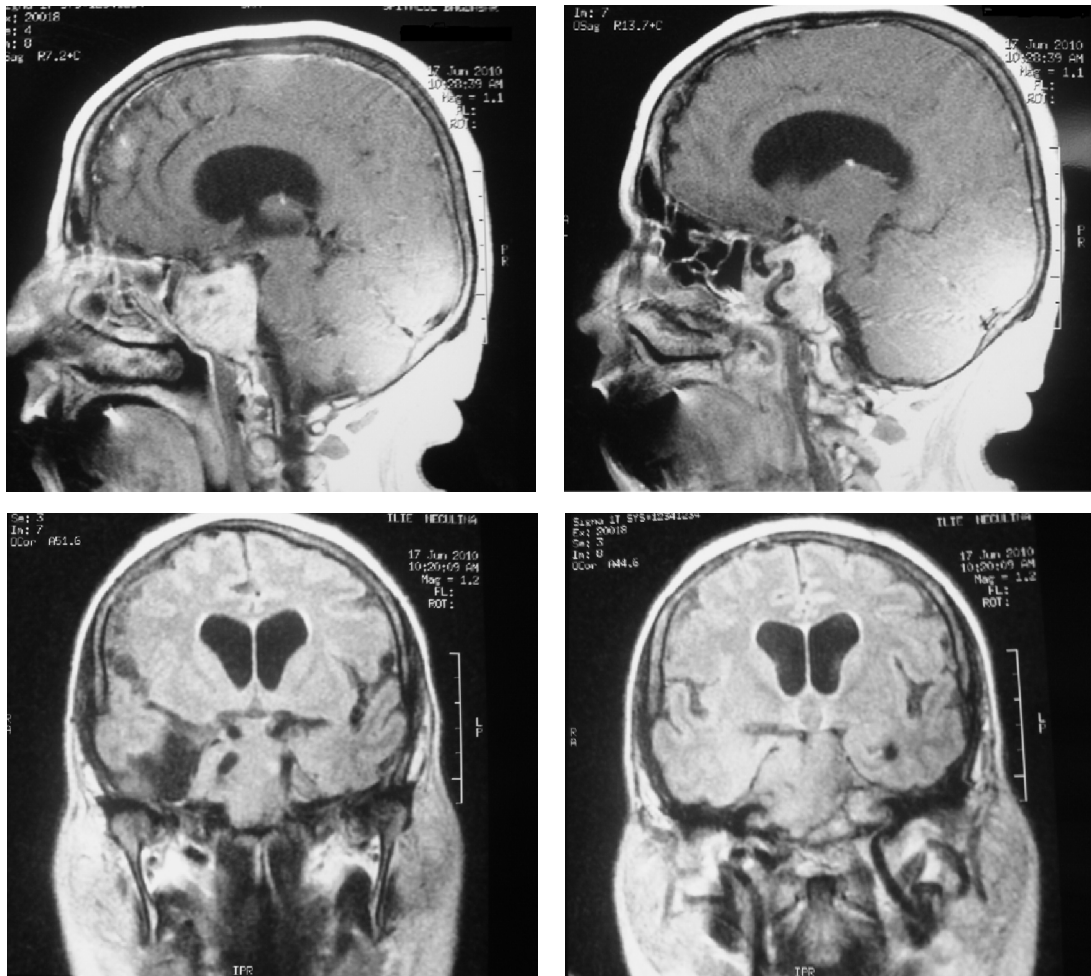
the site opposite the suspected location of the normal pituitary gland. In this stage attention must be paid not to harm the structures of the cavernous sinus. The last part resected was the superior part. As the tumor was removed superiorly the

diaphragm of the sella prolapsed into the operative field. Following tumor removal the sellar defect must be reconstructed to prevent the prolapse of the suprasellar structures and to prevent CSF leakage.





**Figure 1** Cerebral CT scans: large sellar tumor with extension to the sphenoid sinus, suprasellar region and both cavernous sinuses, predominantly on the right side, intraventricular hemorrhage



**Figure 2** Cerebral MR: sellar/suprasellar tumor expanding the sella nad encasing both carotid arteries

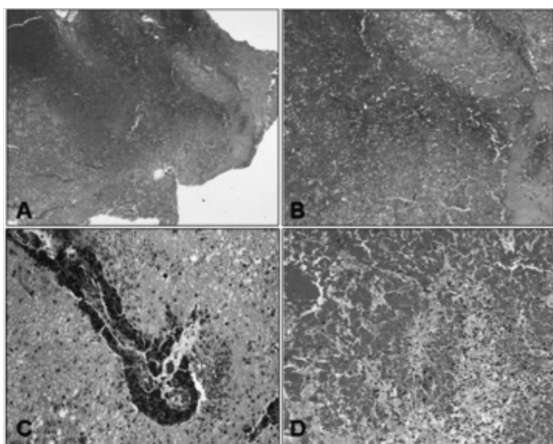
The defect was filled with surgical and gelspon. The nasal septum was returned to the midline position and a tampon consisting of vaseline impregnated gauze was inserted into both nasal cavities and removed 24 hours later.

Histological examination revealed mixt pituitary adenoma most of the tumoral fragments were represented by necrotic tissue highly suggestive for pituitary apoplexy. (Figure 3)

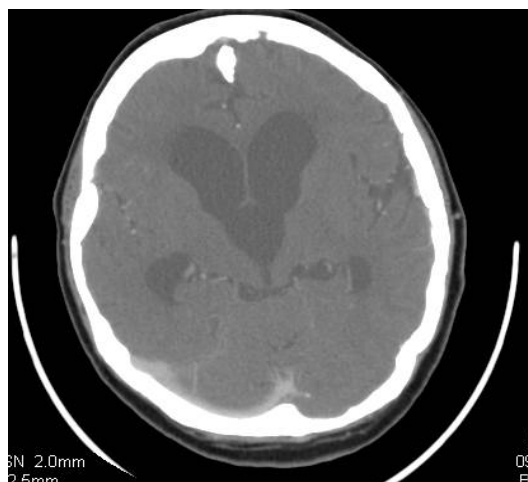
**Postoperative course**

Immediately after the operation the patient noted the improvement of the visual acuity on both eyes. 48 hours later the third nerve palsy had completely resolved. Patient had transient diabetes insipidus but she was discharged from hospital in good condition; she was completely oriented and she had no other neurological signs.

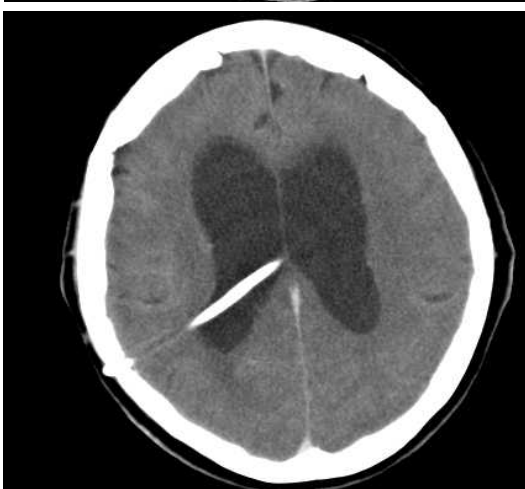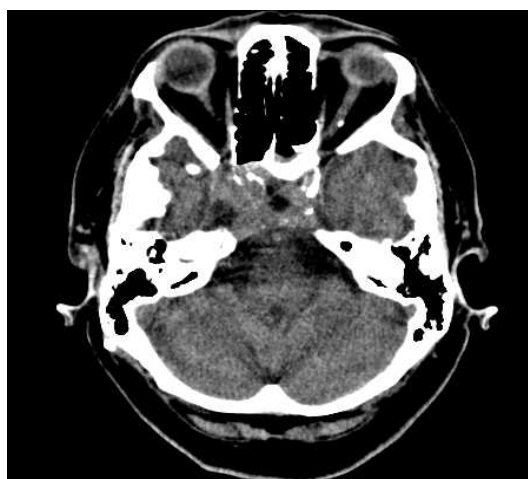One month later the patient presents to our clinic with headache, dizziness, vomiting. CT scans revealed increase in size of ventricular system. (Figure 4) The patient was diagnosed with posthemorrhagic hydrocephalus and a ventriculo-peritoneal shunt was made with symptoms relief. (Figure 5) The endocrinological evaluation revealed normal values.



**Figure 3** Histopathological features of pituitary apoplexy



**Figure 4** Cerebral CT scan: posthemorrhagic hydrocephalus



**Figure 5** Cerebral CT scan: postoperative status, 6 month after surgery

## Discussion

Pituitary apoplexy is a clinical syndrome determined by the rapid expansion of an infarcted and/or hemorrhagic pituitary adenoma that extends laterally to the cavernous sinus or superiorly to displace the chiasm or optic nerves. The clinical syndrome is characterized by sudden onset of a severe headache, nausea, vertigo, meningismus, decreased level of consciousness, ophthalmoplegia, restriction of visual field, decreased visual acuity. (7, 11)

Bailey described the first case of pituitary tumor associated with hemorrhage in 1898; in 1950, Brougham and colleagues called the signs and symptoms due to necrosis and / or hemorrhage "pituitary apoplexy – the second syllable of the suffix "plexy" means "to have a stroke" and comes from Greek language.(11)

Pituitary adenoma represents approximately 10% of intracranial tumors; the reported incidence of pituitary apoplexy in these lesions is 2-7%. (2)

All types of tumor have the same risk to develop apoplexy. Approximately 50% of apoplectic events occur in patients who were not previously known to have pituitary tumors, consequently the diagnosis is delayed. The age range of affected patients stretches from the first to the eighth decade, with the most cases in the fifth and sixth decade. Men are affected more commonly than the women in most series. Wakai, et al., found in their retrospective review that 16.6% of patients with pituitary adenoma had degenerated blood or intratumoral hematoma and only 6.8% experienced an apoplectic event. (12) Deb noted that hemorrhage was observed during surgical intervention in 17.1% and only 5.4% had clinically signs and symptoms. (12)

### The most frequent signs and

**symptoms of pituitary tumor apoplexy are** headache (frontal or retroorbital), restriction of visual field, decrease in visual acuity, ophthalmoplegia, nausea, vomiting, vertigo, meningismus, decreased level of consciousness, facial pain or altered or impaired facial sensation, fever, hemiparesis, horner syndrome, seizure. (7)

**Hormonal abnormalities** are frequently found in pituitary apoplexy. Hypopituitarism, with variably decreased levels of all hormones is due to increased intrasellar pressure, destruction of the gland or preexisting deficits from an adenoma. Vedhuis and Hammond observed that after an episode of pituitary apoplexy, 88% of patients lacked sufficient growth hormone, 76% adequate amounts of lutenizing hormone, 67% sufficient prolactin, and 66% enough adrenocorticotrophic hormone, and that 33% of patients experienced deficiencies in estradiol. (11)

Diabetes insipidus is an uncommon sequela to pituitary apoplexy and occurs as a result of impingement on the intracavernous portion of the inferior hypophysial artery, causing diminished perfusion to the posterior lobe. Another cause of diabetes insipidus is the compression of the infundibulum by the edematous, hemorrhagic material which impedes transit antidiuretic hormone from the preoptic and paraventricular nuclei of the hypothalamus. Verrees and Baha noted that diabetes insipidus occurred in only 2% to 3% of patients examined for this disorder. (11)

**Precipitating factors** have been identified in approximately 50% of cases of pituitary apoplexy. The most frequent factors incriminated in the occurrence of pituitary apoplexy are: head trauma, bromocriptine administration or withdrawal, anticoagulation, pregnancy, cardiac bypass, bowel or other general surgery, atherosclerosis, diabetic

ketoacidosis, estrogen therapy, radiation therapy, hypertension or hypotension. In our case none of these factors was the cause of the sudden onset of the symptoms. (11)

An important number of publications have reported that necrosis and hemorrhage are more frequent in voluminous tumors due to the discrepancy between the rate of neoplastic progression and the availability of circulatory input. Nevertheless small tumors also hemorrhage. Biousse and associates reported increased demand on the pituitary coupled with blood pressure fluctuations as an inciting factor in the generation of pituitary tumor apoplexy. Ebersold, et al., have emphasized vascular stasis and subsequent thrombosis as the likely mechanism eliciting necrosis and subsequent bleeding. (3)

Pituitary adenoma represents 10% of intracranial tumors but pituitary adenomas constitute a greater proportion of tumor related hemorrhage. Glass and Abbott reported that only 25% of intracranial hemorrhage originated secondary to adenomas compared with 50% instigated by gliomas, which are five times more common. Wakai, et al., discovered that adenomas are 5.4 times more likely to bleed. (4)

**Computerized tomography** scans may reveal the hyperdensity of acute hemorrhage if obtained within 3 to 4 days after the acute event or show the mixed density of acute blood and hypodense necrotic tissue. subarachnoid hemorrhage can be evident if blood has invaded the basal cisterns. (10)

**Magnetic resonance imaging** is the most effective neuroimaging method for diagnosing pituitary apoplexy. Pötter, et al., in their series, in which MR imaging studies were obtained in 11 patients with pituitary apoplexy, concluded that this disease may present with varying MR imaging features, including

nonhemorrhagic and hemorrhagic changes on T1-weighted images. The greater sensitivity, precision, and tissue definition of MR imaging reveal the heterogeneous intensity of hemorrhage, edematous pituitary gland, and necrotic tumor leading to diagnosis. The multiplanar capability of this imaging investigation allows characterization of the extent of necrosis and/or hemorrhage and evaluations of the relationship of hemorrhage and surrounding neurovascular structures. K. Arita, et al., noted a series of changes of the parasellar dura mater. These changes are caused by congestion of the dural blood flow, probably because of the increased pressure in the cavernous or circular sinus. He also noted a thickening of the sphenoid sinus mucosa due to venous congestion caused by obstruction of transsellar venous flow. Another cause may be the inflammatory reaction of the sphenoid sinus mucosa; the inflammatory substances produced by the necrotic adenoma tissue intermingled with blood clots during pituitary apoplexy. These inflammatory substances reach the sphenoid sinus by diffusion or by venous flow through an eroded sellar floor. (6, 8)

It is important to recognize apoplexy on CT scans because the CT scans are obtained initially when patients present to the emergency room with nonspecific neurological signs and symptoms. (10)

**Differential diagnosis of pituitary apoplexy** must be made with: SAH from aneurysmal rupture, viral or bacterial meningitis, spontaneous hemorrhage (hypertensive or amyloid bleeding or from a metastatic tumor or primary lesion), cavernous sinus thrombosis, carotid-cavernous fistula, transtentorial herniation, vertebrobasilar insufficiency, optic neuritis, diabetic oculomotor palsy, migraine, temporal arteritis. (5, 12)

**Standard therapy** of pituitary apoplexy

includes: high-dose steroid treatment, which can improve symptoms in a few days, and surgical decompression via transsphenoidal route, if symptoms are severe or rapidly progressive.

The pituitary gland is capable of secreting adequate amounts of hormones when as little as 10% of the gland remains; insufficient secretion of hormones can lead to adrenal crisis. Intravenous steroid administration should start immediately, one hundred milligrams of hydrocortisone can be administered until the correct diagnosis is established. (10)

The definitive therapy for pituitary apoplexy is surgery for decompression of compressed cavernous sinus or suprasellar structures, especially when the visual acuity or field defects, decreased level of consciousness are present, or when the symptoms are progressive. The transsphenoidal approach is a safe and efficient treatment of pituitary apoplexy because the optic pathway which is severely compressed and becomes edematous during the acute stage of pituitary apoplexy is not directly manipulated. (9)

An intracranial approach may be recommended when there is an important hemispheric extension of hemorrhage, the presence of hemorrhage and/or necrosis extending distal to constricted diaphragma sella, or the existence of a poorly aerated sphenoid sinus. (11)

### Conclusions

Pituitary apoplexy remains a potentially life-threatening disease. Its presentation may vary from relatively benign symptoms to major neurological deficits and even death.

Its early recognition and treatment are vital. (2, 11)

### Abbreviation

SAH - subarachnoid hemorrhage

CT – computerized tomography

MR – magnetic resonance

### Correspondence to

*Adriana Dediu, address: Emergency Clinical Hospital Bagdasar – Arseni, No. 10-12, Berceni Street, Sector 4, Bucharest;*

*e-mail: adriana\_ded@yahoo.com*

### References

1. Arita K, Kurisu K, Tominaga A, Sugiyama K, Ikawa F, Yoshioka H, Sumida M, Kanou Y, Yajin K, Ogawa R: Thickening of sphenoid sinus mucosa during the acute stage of pituitary apoplexy. *J Neurosurg* 95:897-901, 2001.
2. Bills DC, Meyer FB, Laws ER, Jr., Davis DH, Ebersold MJ, Scheithauer BW, Ilstrup DM, Abboud CF: A retrospective analysis of pituitary apoplexy. *Neurosurgery* 33:602-608; discussion 608-609, 1993.
3. Biousse V, Newman NJ, Oyesiku NM: Precipitating factors in pituitary apoplexy. *J Neurol Neurosurg Psychiatry* 71:542-545, 2001.
4. Dulipsingh L, Lassman MN: Images in clinical medicine. Pituitary apoplexy. *N Engl J Med* 342:550, 2000.
5. Glendenning P, Pullan PT, Knuckey NW: Pituitary apoplexy: the importance of citing the differential diagnosis. *Med J Aust* 173:548-549, 2000.
6. Hiroyuki F, Tomohide Y, Kazunori O: Efficacy and safety of Touchi extract, an alpha-glucosidase inhibitor derived from fermented soybeans, in non-insulin-dependent diabetic mellitus. *J Nutr Biochem* 12:351-356, 2001.
7. Inamasu J, Hori S, Sekine K, Aikawa N: Pituitary apoplexy without ocular/visual symptoms. *Am J Emerg Med* 19:88-90, 2001.
8. Piotin M, Tampieri D, Rufenacht DA, Mohr G, Garant M, Del Carpio R, Robert F, Delavelle J, Melanson D: The various MRI patterns of pituitary apoplexy. *Eur Radiol* 9:918-923, 1999.
9. Semple PL, De Villiers JC, Bowen RM, Lopes MB, Laws ER, Jr.: Pituitary apoplexy: do histological features influence the clinical presentation and outcome? *J Neurosurg* 104:931-937, 2006.
10. Semple PL, Webb MK, de Villiers JC, Laws ER, Jr.: Pituitary apoplexy. *Neurosurgery* 56:65-72; discussion 72-63, 2005.
11. Verrees M, Arafah BM, Selman WR: Pituitary tumor apoplexy: characteristics, treatment, and outcomes. *Neurosurg Focus* 16:E6, 2004.
12. Wakai S, Fukushima T, Teramoto A, Sano K: Pituitary apoplexy: its incidence and clinical significance. *J Neurosurg* 55:187-193, 1981.