

Frontal brain metastasis of amelanotic malignant melanoma – case presentation

V. Prună¹, V. Munteanu, M. Gorgan

“Bagdasar-Arseni” Clinic Emergency Hospital, Bucharest, Romania

¹Ph.D Student in Neurosurgery “Carol Davila” UMPH Bucharest

Faculty of Medicine, Department of Neurosurgery

Abstract

Amelanotic melanoma is met only in 2-8% of cases with malignant melanoma. The incidence of brain metastases in patients with malignant melanoma ranges from 6-43% of cases. Brain metastases are frequently associated with malignant melanoma after the intratumoral hemorrhage. We choose to present the case of 58-years-old men with a frontal brain metastasis of amelanotic malignant melanoma.

Keywords: amelanotic malignant melanoma, brain metastasis, MRI

Introduction

Cutaneous melanoma is one of the most common tumors that metastasized in the brain after lung cancer, breast cancer and unspecified origin. Most common location of malignant melanoma is the skin, retina, brain and nail bed. In about 14% of cases the location of the primary tumor remains unknown. The incidence of brain metastases in patients with malignant melanoma ranges from 6-43% of cases. In this article we present a patient with metastatic amelanotic malignant melanoma.

Case presentation

A 58-years-old man, operated about two years ago for a right latero-cervical tumor (histopathology: amelanotic malignant

melanoma) was admitted in the Neurosurgery Clinic Emergency Hospital "Bagdasar-Arseni" Bucharest, for seizures and intracranial hypertension syndrome.

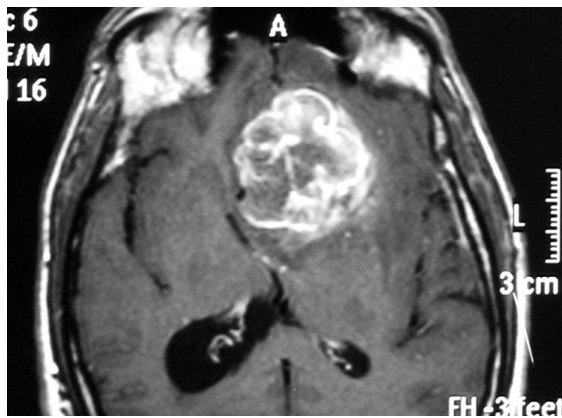
Personal history of pathologic: amelanotic malignant melanoma, duodenal ulcer.

Cranial MRI (native and contrast) highlights a left fronto-basal tumor, with high signal intensity on T1 weighted images (T1WI) and high signal intensity on T2 weighted images (T2WI), polycystic, about 54/46/50 mm in size, with perilesional edema and mass effect that moves the midline to the right (Figure 1A, 1B, 1C). MRAngiography (MRA) reveals a shift to the right ACA (Figure 1D).

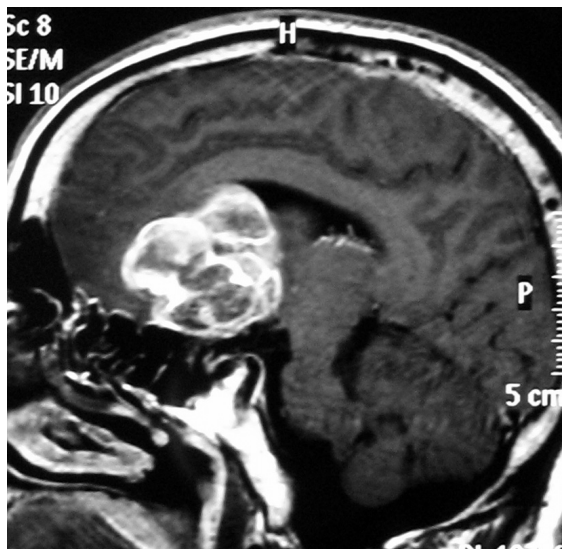Thoracic and abdominal CT showed no evidence of space replacement processes (Figure 2).

The patient underwent surgery: a left fronto-basal bone flap was performed showing a yellow-gray tumor, bleeding, with multiple areas of intratumoral necrosis. Tumor ablation under optical magnification was completely at once, with a safety zone of about 1 cm peritumoral.

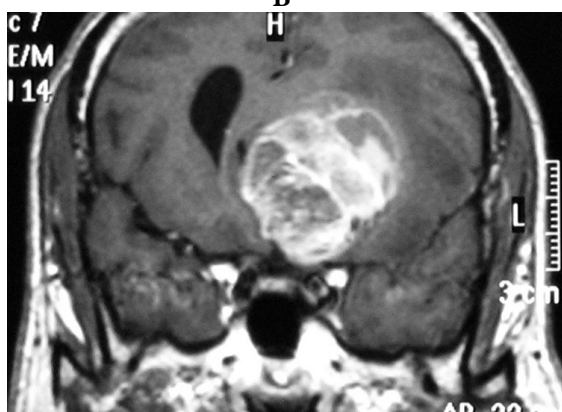
Histological examination (Figure 3) diagnosed the tumor probably germ cells or metastasis of malignant amelanotic melanoma, therefore recommend immunohistochemical examination. The result of immunohistochemical examination was amelanotic malignant melanoma.



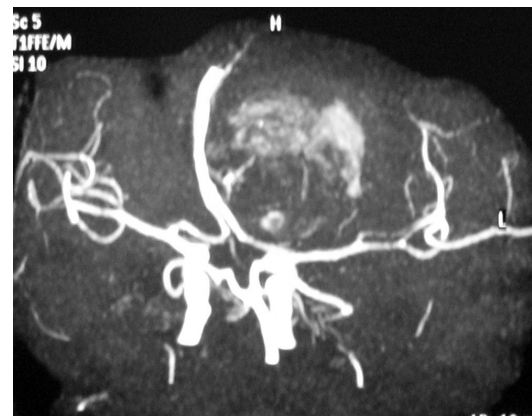
A



B



C



D

Figure 1 Preoperative MRI: **A** Axial section;
B Sagittal section; **C** Coronal section;
D MR Angiography

Postoperatively the patient is aware, cooperative, and without superadded motor deficits. Drain was suppress about 24 hours after surgery and the patient starts recovering. Postoperative CT scan show no tumor remains, preserved median line and left frontobasal flap bone (Figure 4).

During hospitalization the patient has melena, so abdominal ultrasound and upper gastrointestinal endoscopy was performed. No pathological process was found.

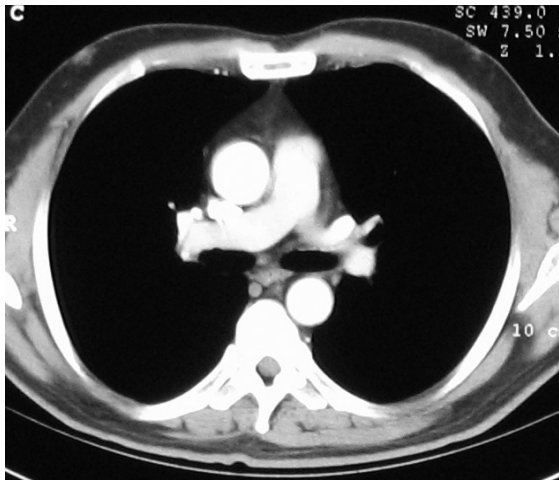
Surgically cured patient is discharged with the recommendation of expert advice in clinical oncology and neurosurgical control over 2 months.

Discussion

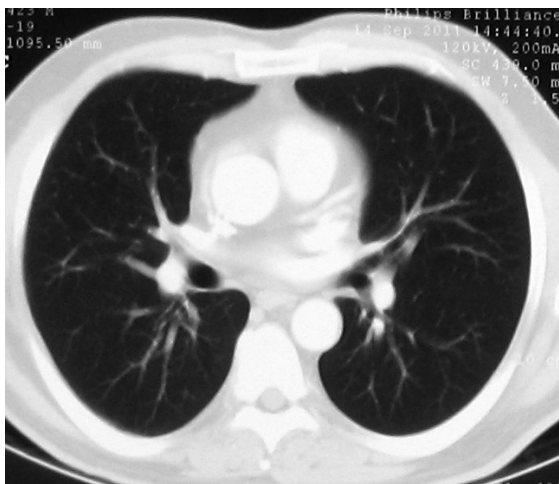
Amelanotic melanoma is met only in 2-8% of cases with malignant melanoma. It is a skin lesion which appears as small abnormal pigmented, reddish or pink lesions, of irregular shape. Many times these lesions can be confused with other tumors (basal cell carcinoma) or inflammatory processes.

Risk factors for the occurrence of brain metastases include:

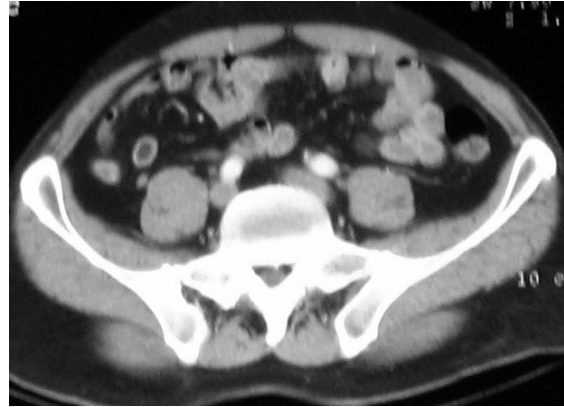
- Location in the head or neck
- High Breslow index (IB > 1 mm) (4)
- Index Clark IV and V(2)
- Protruding or ulcerated skin lesions(7)



A



B



C

Figure 2 **A** Thoracic CT scan without intravenous contrast; **B** Thoracic CT scan with intravenous contrast; **C** Abdominal CT scan

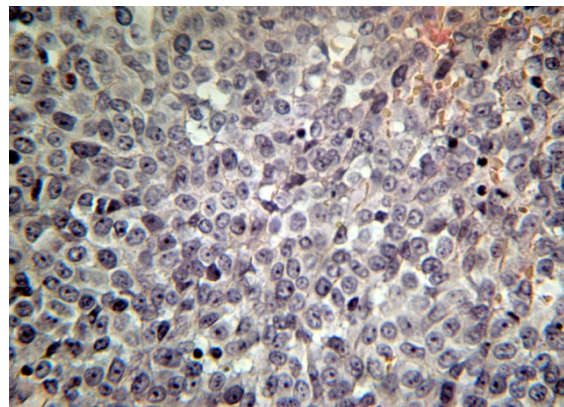
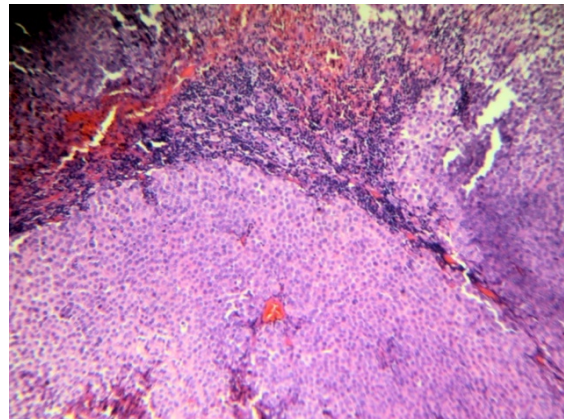


Figure 3 Conventional histological examination

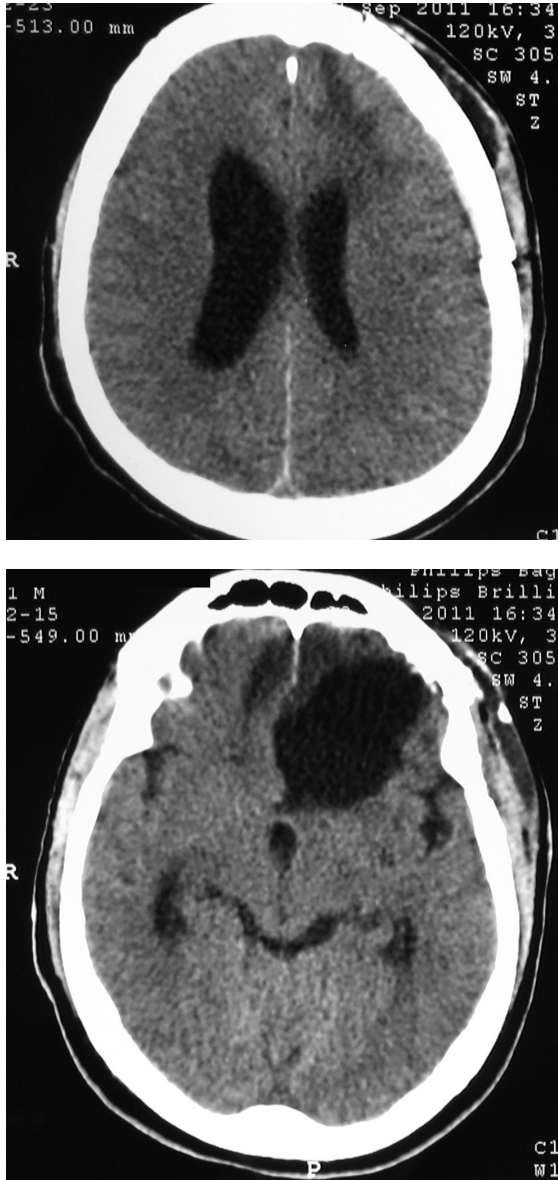


Figure 4 Postoperative CT scan

Brain metastases are frequently associated with malignant melanoma after the intratumoral hemorrhage, and clinical appearance may mimic a stroke or even a subdural hematoma.

The current treatment includes:

- Surgery
- Radiosurgery (Gamma-Knife or LINAC)

- Radiotherapy WBRT
- Chemotherapy
- Immunotherapy
- Multimodal

The goal of treatment is to stabilize disease and improve quality of life(6).

Surgery is the treatment of choice for tumors with a volume of more than 3 cm³. Tumor resection is preferred to be in block(5), and complete resection with a safety peritumoral margin about 0.5 cm(10). It was found that block tumor resection improved survival and local recurrence also decreases. If the tumor resection was radical, all clinical trials have shown that adjuvant therapy may be optional. This rule is applied only in completely resected tumors, otherwise “Whole-Brain” radiation therapy must continue or stereotactic radiosurgery (Gamma-Knife or LINAC).

Stereotactic radiosurgery (Gamma-Knife or LINAC) is a therapeutic alternative(3, 8, 11).

The advantages of radiosurgery are(9):

- Low morbidity
- Low toxicity
- Reduces the duration of hospitalization

The role of whole-brain radiation therapy remains controversial because of low sensitivity and high risk of developing dementia in younger patients(1). The prognosis of patients with brain metastases after malignant melanoma is usually infaust.

Conclusions

A melanotic melanoma is a rare malignant skin lesion which often provides diagnostic problems. Surgery and radiation Gamma-Knife Stereotactic type or LINAC remain the main methods of treatment for brain metastasis from amelanotic malignant

melanoma. An early and correct diagnosis of skin lesion followed by appropriate treatment reduces the risk of developing brain metastasis and increases quality of life. Patients with metastases after this type of injury usually have a poor prognosis.

References

1. Bindal AK, Bindal RK, Hess KR, Shiu A, Hassenbusch SJ, Shi WM, Sawaya R: Surgery versus radiosurgery in the treatment of brain metastasis. *J Neurosurg* 84:748-754, 1996.
2. Breslow A: Thickness, cross-sectional areas and depth of invasion in the prognosis of cutaneous melanoma. *Ann Surg* 172:902-908, 1970.
3. Buchsbaum JC, Suh JH, Lee SY, Chidel MA, Greskovich JF, Barnett GH: Survival by radiation therapy oncology group recursive partitioning analysis class and treatment modality in patients with brain metastases from malignant melanoma: a retrospective study. *Cancer* 94:2265-2272, 2002.
4. Clark WH, Jr., From L, Bernardino EA, Mihm MC: The histogenesis and biologic behavior of primary human malignant melanomas of the skin. *Cancer Res* 29:705-727, 1969.
5. Patel AJ, Suki D, Hatiboglu MA, Abouassi H, Shi W, Wildrick DM, Lang FF, Sawaya R: Factors influencing the risk of local recurrence after resection of a single brain metastasis. *J Neurosurg* 113:181-189, 2010.
6. Raizer JJ, Hwu WJ, Panageas KS, Wilton A, Baldwin DE, Bailey E, von Althann C, Lamb LA, Alvarado G, Bilsky MH, Gutin PH: Brain and leptomeningeal metastases from cutaneous melanoma: survival outcomes based on clinical features. *Neuro Oncol* 10:199-207, 2008.
7. Sampson JH, Carter JH, Jr., Friedman AH, Seigler HF: Demographics, prognosis, and therapy in 702 patients with brain metastases from malignant melanoma. *J Neurosurg* 88:11-20, 1998.
8. Sawaya R, Ligon BL, Bindal AK, Bindal RK, Hess KR: Surgical treatment of metastatic brain tumors. *J Neurooncol* 27:269-277, 1996.
9. Sloan AE, Nock CJ, Einstein DB: Diagnosis and treatment of melanoma brain metastasis: a literature review. *Cancer Control* 16:248-255, 2009.
10. Yoo H, Kim YZ, Nam BH, Shin SH, Yang HS, Lee JS, Zo JI, Lee SH: Reduced local recurrence of a single brain metastasis through microscopic total resection. *J Neurosurg* 110:730-736, 2009.
11. Zacest AC, Besser M, Stevens G, Thompson JF, McCarthy WH, Culjak G: Surgical management of cerebral metastases from melanoma: outcome in 147 patients treated at a single institution over two decades. *J Neurosurg* 96:552-558, 2002.