

## Subarachnoid hemorrhage in a young patient with a factor V Leiden thrombophilia: case report and literature review

Dana Turliuc, R.A. Sorete, N. Dobrin, A. Chiriac, Natalia Ermalai

Clinic of Neurosurgery

“Grigore T. Popa” University of Medicine and Pharmacy Iasi, Romania

### Abstract

*Introduction:* Cerebral venous thrombosis, including thrombosis of cerebral veins and major dural sinuses, is an uncommon disorder in the general population. However, it has a higher frequency among patients younger than 40 years old, patients with thrombophilia, and women who are pregnant or receiving hormonal contraception. The annual incidence is estimated to be 3 to 4 cases per million. Coexisting cerebral vein thrombosis and aneurysmal disease in the setting of acute subarachnoid hemorrhage is exceedingly rare. These rare situations put difficult problems of diagnosis and treatment.

*Case Report:* We present the case of a 42-year-old man patient who was diagnosed with thrombophilia of heterozygous factor V Leiden mutation and right ischemic stroke internal carotid cerebral artery four years ago. The patient presented with nausea, vomiting, a progressive severe headache that had lasted for a few days, followed by a rapid deterioration in the level of consciousness. On admission, the patient was in a comatose state, GCS score 5, mydriasis with bilaterally preservation of fotomotor reflex, stiff neck, acute respiratory failure and vegetative disorder. Cerebral CT scan showed a acute tetraventricular hydrocephalus and subarachnoid hemorrhage and cerebral four

vessels angiography showed an left posterior communicating artery aneurysms and complete occlusion of right internal carotid artery. The aneurysm was managed with endovascular coiling with 100% occlusion achieved and acute hydrocephalus was treated first with external ventricular drainage and in a second time with ventriculoperitoneal shunt. The immediate and late outcome of patient has been addicted to several complications: acute bacterial meningitis, left hemiparesis, bronchopneumonia, urinary infection, malfunction of external ventricular drainage end swallowing disorders.

*Conclusion:* In this report, the authors discuss the case of a coexistence ruptured aneurysm of the left posterior communicating artery in one patient known with factor V Leiden thrombophilia and proximal right ICA occlusion. This associated is more rare and dangerous, but curable disease. The case clearly illustrates both the difficulty in establishing the cause of subarachnoid hemorrhage in the presence of both aneurysmal and CVST disease as well as the initiation of post-endovascular coil embolization anticoagulation therapy. Endovascular coil embolization of the aneurysm was thus undertaken, with subsequent heparin anticoagulation to attempt to prevent

thrombus propagation. This neurosurgical strategy for treatment of a patient conducted to excellent results.

**Key words:** thrombophilia, factor V Leiden mutation, subarachnoid hemorrhage, cerebral aneurysms.

## Introduction

Coexisting cerebral vein thrombosis and aneurysmal disease in the setting of acute subarachnoid hemorrhage is very rare. Clinical management of the patient is such an instance is difficult (11). The evolution of noninvasive diagnostic imaging methodologies such as CT angiography and venography, as well as MR imaging, angiography, and venography (16), cultivated our knowledge regarding the full clinical spectrum of CVST (1). Cerebral venous sinus thrombosis justifies for 0.5% of all stroke cases (5). The incidence of CVST, in adults has been estimated to be as 3–4 cases per million people (1). One of the causes of these disorders is factor V Leiden. Factor V Leiden thrombophilia is an hereditary disorder, mutation, of the mechanisms of blood clotting. The frequency of factor V Leiden and its prevalence in thromboembolic disease emphasize the need for nursing professionals to better understand the consequences of the factor V Leiden mutation (14).

Determining the aetiology of the subarachnoid bleed is important for determines the treatment strategy; especially the initiation of anticoagulation therapy balancing the risk of thromboembolism with further hemorrhage (7). The morbidity and mortality in such cases may be predictably high.

We describe a case and discuss the basis of the management strategy in a patient

who presents in this setting. Proximal right ICA occlusion shows abnormal collateral vascular networks from posterior circulation and accompanying saccular aneurysms. The left posterior communicating artery aneurysm associated with proximal right ICA occlusion in one patient with factor V Leiden thrombophilia is more rare and dangerous, but curable disease. Endovascular embolization for such aneurysms is safe and available.

## Case report

M.G.E., 42 y.o. man, was admitted into the Neurosurgical Department, Intensive Care Department from the Emergency Clinical Hospital “Prof. Dr. N. Oblu” Iasi, Romania. At admission the patient was comatose, GCS (Glasgow Coma Scale) score 5, mydriasis with bilaterally preservation of fotomotor reflex, stiffness neck, acute respiratory failure and vegetative disorder. Family reported that the last 24 hours the patient had headache, nausea and vomiting. He had a history of hypertension that was not being treated, smoking and also the patient was diagnosed with thrombophilia of heterozygous factor V Leiden mutation, right ischemic stroke internal carotid cerebral artery four years ago. The patient subsequently made an unremarkable recovery with no neurological deficit. The past three years the patient did not follow any treatment.

In our institution he was evaluated after admission with cerebral computed tomography scan (CT scan) (figures 1, 2, 3 and 4), cerebral computed tomography angiography (CTA) and basic evaluation for general health problems blood (tests, EKG, chest x-ray, cardiologic evaluation).

Neurological exam on admission revealed comatose state, GCS score 5, left hemiparesis, flexion of right limbs on

noxious stimuli, Babinsky's sign at the right foot and absent cutaneous plantar response at the right foot, neck stiffness.

A coagulopathy screen was negative. The prothrombin time (PT) was 14.0/sec, international normalized ratio (INR) was 1.1 and Platelets (PLT)=265.000/mm. Brain computed tomography (figures 1, 2, 3 and 4) shows a acute tetraventricular hydrocephalus and subarachnoid hemorrhage.

The cerebral computed tomography angiography (CTA) shows acute tetraventricular hydrocephalus and subarachnoid hemorrhage, without viewing right internal jugular vein in the jugular foramen, right transverse sinus and sigmoid, right ICA thrombosis, right segment M1 amputated of 1 cm from the origin, segmental thrombosis of the left ICA supracavernos segment, then visualize hypoplastic left A1 segment.

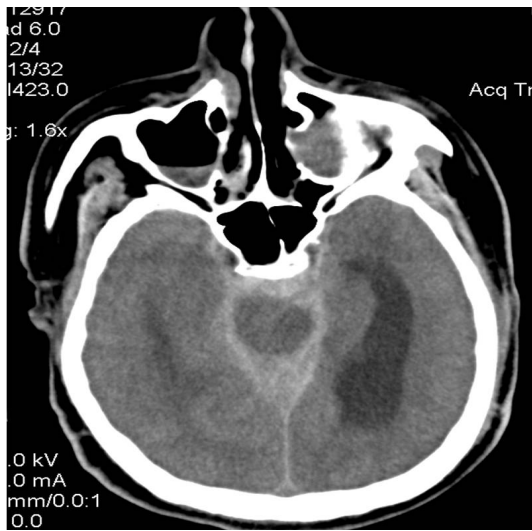


Figure 1

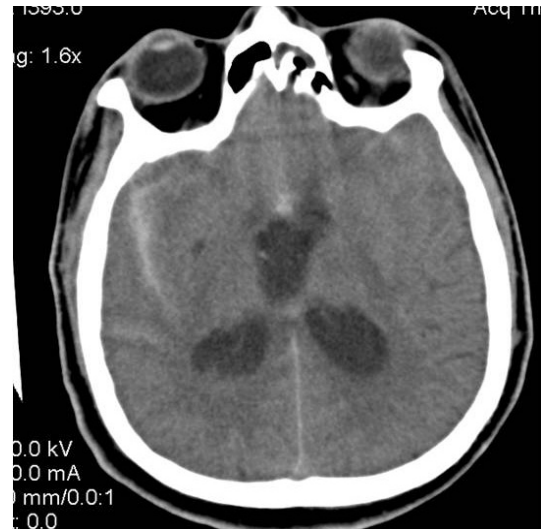


Figure 3

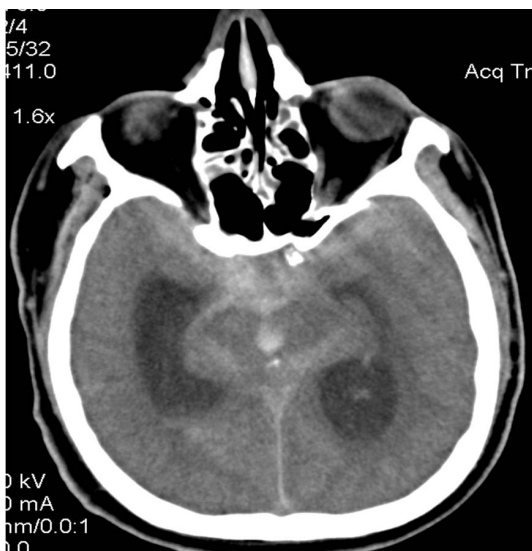


Figure 2

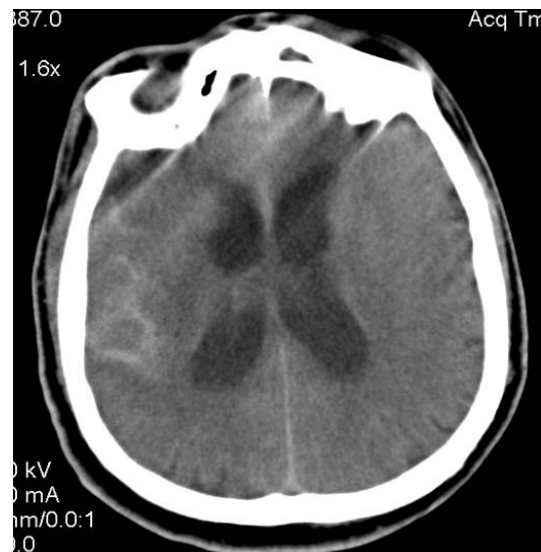

Figure 4

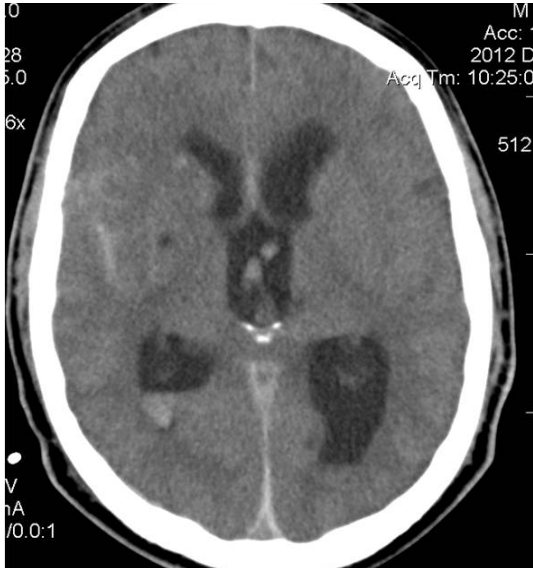


Figure 5

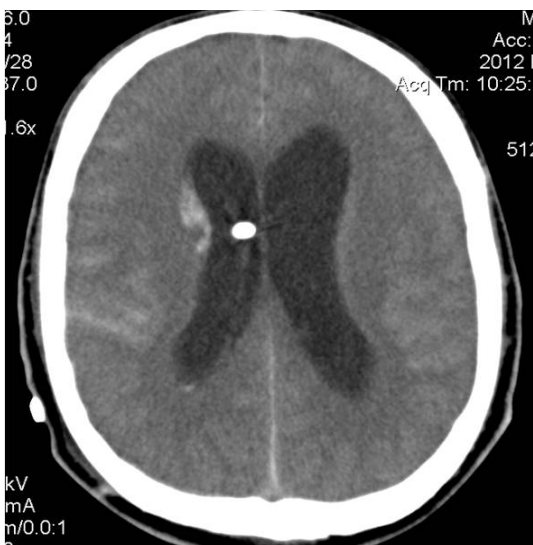

Figure 6

In emergency was insert a external ventricular drainage (figures 5 and 6).

The patient's evolution has been very difficult with multiple complications: acute bacterial meningitis, left hemiparesis, bronchopneumonia, urinary infection, malfunction of external ventricular drainage end swallowing disorders.

In the tenth day postoperative the patient had fever 37, 8 C, and examination of cerebrospinal fluid showed 6830 leukocytes and 4270 erythrocytes. The etiology of bacterial meningitis was *Staphylococcus aureus* and we started the treatment with antibiotics.

After 14 days with antibiotics the examination of cerebrospinal fluid showed 11 leukocyte and the patient don't have fever. Because of many complications the ventriculoperitoneal (VP) shunt was inserted after 27 days of admission in hospital.

Treatment was following the directions of identifying and eliminating the precipitating factor, anticoagulation administration, and aggressive intracranial hypertension management and anticonvulsive treatment.

The cerebral four vessels angiography showed an left posterior communicating artery aneurysm (figure 7) and complete occlusion of right internal carotid artery (figure 9) with no anterograde flow across of this occlusion (figure 10).

The procedure was perform with the patient under general anesthesia. The femoral access was with a 5F vascular sheath and femoral catheterization was done with a 5F guiding catheter. A 5F guiding catheter was introduce into the proximal parent artery at which the target aneurysmal lesion was locate. Excelsior SL 10 microcatheter was ascend on miccroguiding. Have been introduced and detached two spiral coils GDC -10 and one spiral Axium, which achieved a sufficient compaction aneurysm occlusion without filling the residual. Figure 11 and figure 12 show the alimentation to the system anterior cerebral and right medium cerebral from vertebrobasilar system.

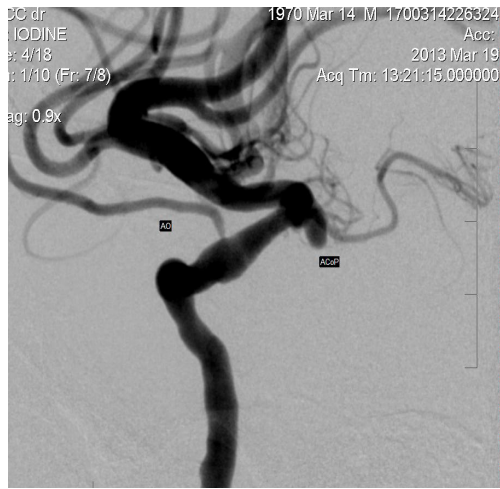

Figure 7

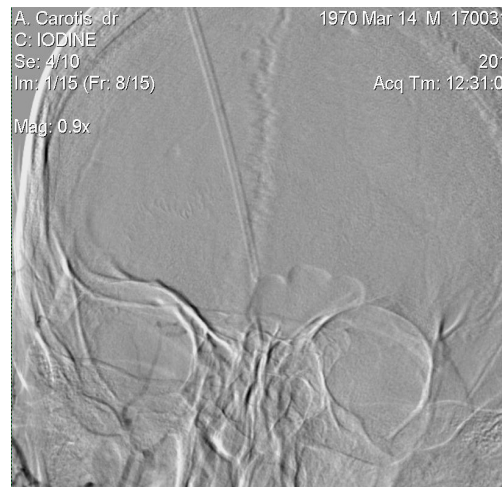


Figure 10

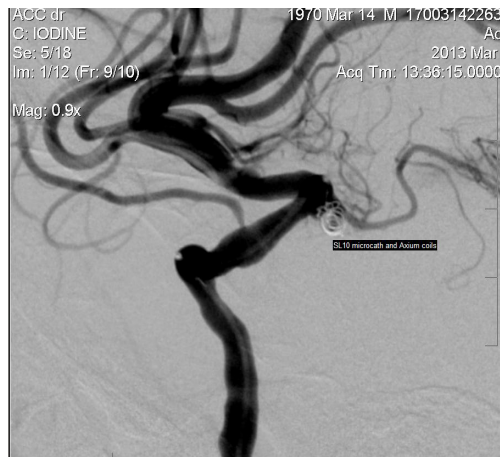

Figure 8

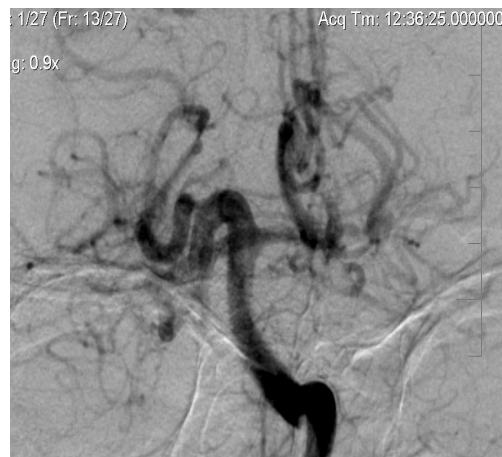

Figure 11

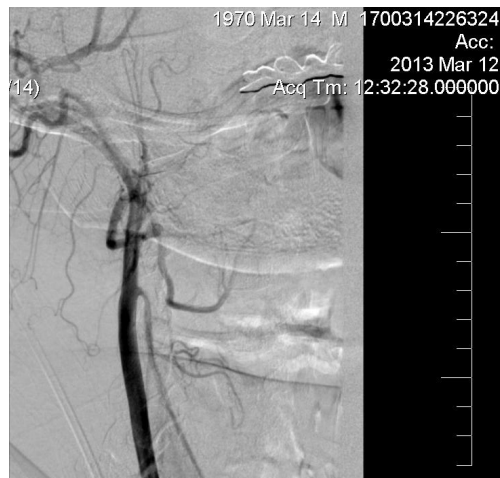

Figure 9

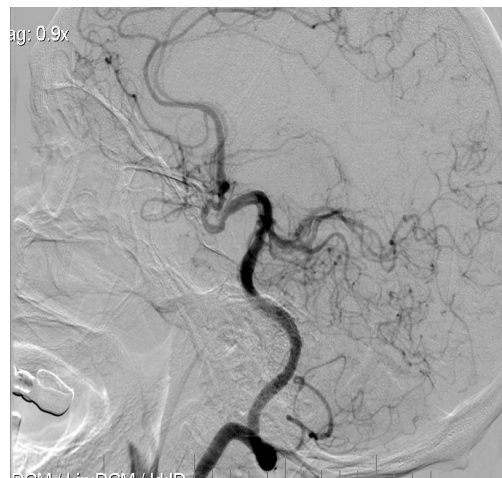


Figure 12

Endovascular coil embolization of the aneurysm was thus undertaken (figure 7: preembolization and figure 8: post-embolization) with subsequent heparin anticoagulation to attempt to prevent thrombus propagation. The optimal treatment of CVST remains controversial partly due to the variable nature of disease progression, further complicating the management of such patients(16). Heparinisation was reversed after our patient acutely deteriorated, but subsequently made an uneventful recovery.

## Discussion

Both intracranial aneurysms and cerebral venous sinus thrombosis are acknowledged causes of subarachnoid hemorrhage (SAH) (32). Spontaneous SAH is related to a ruptured aneurysm in 85% of cases. All the same, SAH can even present as the initial manifestation of cerebral venous sinus thrombosis (CVST). In most of such cases the distribution of SAH is over the cortical surface of the brain, typically associated with a cortical venous infarction which may or may not be hemorrhagic. The venous hemorrhagic infarction is responsible for the production of SAH by secondary rupture into the subarachnoid space and the mechanism of CVST with secondary venous hypertension resulting in the rupture of fragile, thin-walled cortical veins has been proposed (5). It is important to look for the presence of venous thrombosis on a CTA, particularly if the SAH is over the cortical surface.

When intracranial aneurysms and cerebral venous sinus thrombosis coexist in an acute SAH, the established cause will determine firstly the necessity and urgency in treating the aneurysm and secondly, treatment of the venous thrombosis by

anticoagulation to prevent clot propagation or rarely clot thrombolysis (7). Despite both the aneurysm and CVST occurring on the same side as the bleed, the pattern of distribution of blood made acute aneurysm rupture most likely in our patient. Thrombophilia with a factor V Leiden mutation was a possible risk factor for developing CVST in our patient. In factor V Leiden, patients have a point mutation in the factor V gene that produces a mutated factor V. The factor V Leiden is inactivated, on the clotting level, about 10 times slower than normal factor V and persists longer in the circulation, resulting in increased generation of thrombin and a hypercoagulable state (thrombophilia). In a factor V Leiden the INR and PTT are normal, because the patient with factor V Leiden makes fibrin at the same rate as a person with normal factor V.

Two distinct pathophysiological theories have been developed for explaining the clinical presentation of CVST (24). The first theory postulates that the thrombosis of the cerebral veins or sinuses can result in increased venular and capillary pressure who contributes to parenchymal hemorrhage, vasogenic and cytotoxic edema; and the second pathophysiological mechanism theory relies on the direct thrombosis of major cerebral venous sinuses (24). The resulting higher pressure of the thrombosed sinuses impedes the absorption and the circulation of the cerebrospinal fluid (CSF) from the subarachnoid space to the cerebral venous circulation via the arachnoid villi structures and the impairment of CSF absorption conducts to the development of intracranial hypertension. The raised intracranial pressure resulting from venous thrombosis has been postulated to cause venous

dilatation with subsequent rupture or aneurysmal rupture (4); the latter remains a possible aetiological factor in our patient.

It is known that the most important etiological factor for intracranial saccular aneurysm is hemodynamic stress. The occlusion of one or more feeding vessels may enhance the possibility of aneurysm formation at large arterial forks subjected to increased hemodynamic stress associated with collateral flow(18). Formation of new aneurysms is a potential complication in the management of patients following ICA occlusion and the data reviewed here suggest that “de novo aneurysm formation occurs in 4.3% of patients undergoing vessel occlusion at an average of 9 years following the occlusion” (25). The pathogenesis is not clear, one hypothesis relates to hemodynamic stress. Like in our case the vessels are subject to increased blood flow to supply the contralateral circulation, following ICA occlusion. This may give rise to degeneration of the endothelial basement membranes and subendothelial connective tissue of the arterial wall. Besides, previous literature suggests that the risk factors predictive of initial aneurysm formation likely correlate with de novo formation. The factors predictive include history of arterial hypertension, cigarette smoking, female gender, age, history of multiple and familial forms of intracranial aneurysms, and hereditary connective tissue diseases (15, 17, 19). The location of de novo aneurysms observed is likely multifactorial due to an underlying diathesis of the vessel to aneurysm formation as well as changes in flow. The patients with ICA occlusion should receive continued radiographic follow-up imaging, such as CTA and MRA and this follow-up is especially important in

the first decade (25).

Symptomatic formation and/or enlargement of aneurysms as a late complication of internal carotid artery occlusion has been slightly reported (23). A review of the literature in 1989 by Dyste and Beck reported an incidence of symptomatic aneurysm formation between 4% and 10%(6). On of the role in the formation and/or enlargement of these aneurysms plays a hemodynamic case (6, 8, 13).

The extensive collateral networks as well as the already compromised cerebral blood flow and high internal blood pressure makes the direct clipping for these aneurysms to be difficult and the morbidity is high (28). With endovascular techniques, the aneurysms that are difficult to reach by craniotomy can now be treated with excellent results. Conservative management for these aneurysms can lead to dismal results and aggressive treatments should be considered. We chose this procedure and endovascular coil embolization of the aneurysm was thus undertaken, with subsequent heparin anticoagulation to attempt to prevent thrombus propagation.

The treatment of patients with CVST should follow 4 directions to provide a complete treatment plan and maximize the chance of favorable outcome. All stages should be include to identify and appropriately manage the predisposing and precipitating factors, administer antithrombotic therapy, lower and normalize the elevated ICP, and provide symptomatic treatment for seizures, headache, and visual disturbances (31).

Treatment of CVST with anticoagulation (AC) is recommended, even if the evidence for its benefit is not substantial (29). For all that, AC for CVST

continues to be beneficial even in the presence of ICH (18), the optimum time to start such a treatment option has not been clearly defined. We report a case of CVST with SAH, who responded favorably to AC. The most neurologists currently start treatment with heparin as soon as the diagnosis is confirmed, even in the presence of hemorrhagic complications (29). Heparin treatment has been shown to be beneficial rather than dangerous when CVST is associated with ICH. In 43 patients with CVST and ICH, Einhüpl et al. (10) reported a mortality of 15% in heparin-treated patients compared to 69% that in those who did not receive heparin. In our case, AC therapy was associated with a favorable outcome. The safety of immediate AC with cases of SAH and CVST upon presentation needs further clarification as in most of the reported cases of CVST with ICH, heparin treatment was delayed (10, 21). Oppenheim et al. suggested performing magnetic resonance angiography or digital subtraction angiography, to rule out intracranial aneurysm before AC in cases of CVST with SAH (21). The mean delay between the onset of symptoms and heparin treatment was 33 days in the study by Einhüpl et al. (10). To evaluate the time interval when enlargement of venous intracerebral hemorrhages is more likely to occur, no studies were found. In general, active bleeding into the brain is usually confined to the first 6 h following ICH, with 10–15% of patients showing hematoma enlargement between 6 and 24 h from the onset of spontaneous ICH (12).

Evidence suggests that the hemodynamic changes secondary to occlusion of feeding arteries, like was in our case, may lead to compensatory changes in the blood flow

through anastomotic vessels (22, 26). The formation of an aneurysm starts with the increase in blood flow and change in velocity, through these smaller vessels can increase the pressure on the arterial wall, facilitate weakening and promote remodeling (27, 30).

In our review of the literature, we found that collateral circulation most commonly arises from the vertebrobasilar system and the most frequent location of aneurysms are the basilar and posterior cerebral arteries. The direction of the aneurysm sac (as in our case) confirms that the aneurysm formation was induced by hemodynamic modifications. Saccular aneurysms associated with carotid artery occlusion, as with other arterial anomalies, have a high tendency to bleed because of the increased blood flow in the parent arterial system. These patients are at a higher risk of complications related to either modality of intervention because of parent malformation (28).

## Conclusion

Our case clearly illustrates both the difficulty in establishing the cause of subarachnoid hemorrhage in the presence of both aneurysmal and CVST disease as well as the initiation of post-endovascular coil embolization anticoagulation therapy. Based on our case and selected cases in the literature, it would appear that instigating anticoagulation treatment with subsequent close clinical, imaging and transcranial pressure monitoring is to be advocated. Early diagnosis of CVST is crucial and constitutes our first target in treating our patients with suspected CVST. In the cases in which the diagnosis of CVST is confirmed by clinical data and neuroimaging studies, our next step is the



identification of the underlying cause. Every directions is made in the prophylaxis and symptomatic treatment of seizures, intracranial hypertension, headache, and/or visual disturbances.

The basis of CVST treatment is proper anticoagulation in the acute setting. The EFNS guidelines involves the use of intravenous heparin or subcutaneous LMWH. Transient causes of CVST are usually treated in our institution with 3-month oral anticoagulation therapy, patients with CVST due to mild thrombophilias usually take the proper dose of oral anticoagulation for 6–12 months, and patients with severe thrombophilias require lifetime treatment. AC treatment for cases of CVST with hemorrhagic complications was not associated with adverse outcome. If ICH is present, immediate AC for CVST at presentation and within 24 h from onset of symptoms cannot be safely recommended, as in almost all previous reports there was a delay in the onset of AC ranging between 4 and 33 days. We also recommend to perform magnetic resonance angiography or digital subtraction angiography before AC in cases of CVST with SAH to rule out a coincident intracranial aneurysm.

Endovascular embolization may be a good treatment option with excellent safety for a ruptured aneurysm that accompanies proximal ICA occlusion with vulnerable collateral flow. It's a technical challenge with an endovascular procedure for to access to the saccular segment of left posterior communicating artery, because to the longer navigation route and its impact on the stability of catheter guidance systems currently available. However, this may involve a major risk of thromboembolic complications during and after the

procedure, because of delivery and stability. For these we need a high level of technical expertise. The possible existence of such angioarchitectural arrangement will prompt early diagnosis. Because the risks of rebleeding remains a major killer in the natural course of the disease, an interventional procedure with an optimal risk-benefit equation is yet to be determined for these patients.

Hemodynamic factors are commonly believed to play an important role in the pathogenesis, progression, and rupture of cerebral aneurysms. Recent studies have hypothesized that hemodynamic changes in parent vessels are responsible for the formation of cerebral aneurysms. We conclude that the regression and potentially the formation of this aneurysm is correlated with hemodynamic factors associated with occlusion of the contralateral ICA and the arteriographic evaluation is indicated in every patient in whom carotid artery occlusion, so that preexisting aneurysms may be found and treated.

The treatment of patients with CVST coexist with intracranial aneurysm usually requires a multidisciplinary approach, including specialists and close collaboration between the departments of hematology, neurology, neurosurgery, neuro-interventional surgery and neurointensive care.

## References

1. Alberti A, Venti M, Biagini S: Headache and cerebral vein and sinus thrombosis, *Front Neurol Neurosci*, 2008; 23:89–95.
2. Ballotta E, Da Giau G, Manara R, Baracchini C.: Extracranial severe carotid stenosis and incidental intracranial aneurysms, *Ann Vasc Surg.*, 2006; 20:5–8. (PubMed)
3. Benedetti A, Curri C, Colombo F.: Rebleeding of an angiographically healed aneurysm, *Surg Neurol*.1983; 20:206–8. (PubMed).

4. Birchall D, Khangure MS, McAuliffe W.: Resolution of Third Nerve Paresis after Endovascular Management of Aneurysms of the Posterior Communicating Artery, *AJNR*, 1999; 20:411–413.
5. Bousser MG, Ferro JM: Cerebral venous thrombosis: an update, *Lancet Neurol*, 2007; 6:162–170.
6. Clark WC, Ray MW: Contralateral intracranial aneurysm formation as a late complication of carotid ligation, *Surg Neurol*, 1982; 18: 485–462.
7. Davagnanam I, Brew S: Subarachnoid Hemorrhage with Cerebral Vein Thrombosis and Aneurysmal Disease: A Treatment Conundrum A Case Report, *Interventional Neuroradiology*, 2008; 14: 335–338.
8. Dyste GW, Beck DW: De Novo aneurysm formation following carotid ligation: case report and review of the literature, *Neurosurgery*, 1989; 24:88–92.
9. Einhäupl K, Stamb J, Bousserc M-G, De Bruijnd S, Ferroe JM, Martinelli I, Masuhra F: EFNS guideline on the treatment of cerebral venous and sinus thrombosis in adult patients, *European Journal of Neurology*, 2010; 17: 1229–1235.
10. Einhäupl KM, Villringer A, Meister W, Mehraein S, Garner C, Pellkofer M, Haberl RL, Pfister HW, Schmiedek P: Heparin treatment in sinus venous thrombosis, *Lancet* 1991; 338: 597–600.
11. Filippidis A, Kapsalaki E, Patramani G, Fountas KN.: Cerebral venous sinus thrombosis: review of the demographics, pathophysiology, current diagnosis, and treatment, *Neurosurg Focus*, 2009; 27(5).
12. Fujii Y, Tanaka R, Takeuchi S; Koike T, Minakawa T, Sasaki O: Hematoma enlargement in spontaneous intracerebral hemorrhage. *J Neurosurg*, 1994; 80: 51–57.
13. Fujiwara S, Fujiik, Fukuim: De novo aneurysm formation and aneurysm growth following therapeutic carotid occlusion for intracranial internal carotid artery (ICA) aneurysms, *Acta Neurochir*, 1993; 120:21–25.
14. Jinyu Xu, Ying Yu, Xi Wu, Yongfa Wu, Che Jiang, Shengzhang Wang, Qinghai Huang, Jianmin Liu: Morphological and Hemodynamic Analysis of Mirror Posterior Communicating Artery Aneurysms, 2013; *PLoS ONE* 8(1).
15. Kim H, Jung JY, Lee JW, Huh SK, Lee KC: A clinical analysis of twelve cases of ruptured cerebral de novo aneurysms, *Yonsei Med J*, 2007; 48(1):30–34.
16. Leach JL, Fortuna RB, Jones BV, Gaskill-Shiple MF: Imaging of cerebral venous thrombosis: current techniques, spectrum of findings, and diagnostic pitfalls, *Radiographics*, 2006; 26 (1Suppl):S19–S41.
17. Matheus MG, Castillo M: Development of de novo intracranial aneurysm in three months: case report and literature review, *AJNR Am J Neuroradiol*, 2003; 24(4):709–710.
18. Meguro T, Tanabet T, Muraoka K, Terada K, Hirotsune N, Nishino S: Endovascular Treatment of Aneurysmal Subarachnoid Hemorrhage Associated with Bilateral Common Carotid Artery Occlusion, *Interventional Neuroradiology*, 2008; 14: 447–452.
19. Obray R, Clatterbuck R, Olvi A, Tamargo R, Murphy KJ, Gailloud P: De novo aneurysm formation 6 and 22 months after initial presentation in two patients, *AJNR*, 2003; 24(9):1811–1813.
20. Omar Ahmed Hassanien: Anticoagulation for Cerebral Venous Thrombosis with Subarachnoid Hemorrhage: A Case Report, *Med Princ Pract*, 2010; 19:73–75.
21. Oppenheim C, Domigo V, Gauvrit JY, Lamy C, Mackowiak-Cordoliani MA, Pruvo JP, Méder JF: Subarachnoid hemorrhage as the initial presentation of dural sinus thrombosis, *AJNR Am J Neuroradiol*, 2005; 26: 614– 617.
22. Pappada G, Fiori L, Marina R, Citerio G, Vaiani S, Gaini SM: Incidence of asymptomatic berry aneurysms among patients undergoing carotid endarterectomy, *J Neurosurg Sci*. 1997; 41:257–62.(PubMed)
23. Paul E. Timperman, Thomas A. Tomsick, John M. Tew, Jr, and Harry R. van Loveren: Aneurysm Formation after Carotid Occlusion, *AJNR*, 1995; 16: 329–331.
24. Piazza Gregory: Cerebral Venous Thrombosis, *Circulation*. 2012; 125:1704–1709.
25. Priyangee K. Arambepola, Sean D. McEvoy, Ketan R. Bulsara: De Novo Aneurysm Formation after Carotid Artery Occlusion for Cerebral Aneurysms, *Skull Base*, 2010; 20(6): 405–408.
26. Sekhar LN, Scwabassi RJ, Sun M, Blue HB, Wasserman JF: Intra-aneurysmal pressure measurements in experimental saccular aneurysms in dogs, *Stroke*, 1988; 19:352–356. (PubMed)
27. Senn P, Krauss JK, Remonda L, Godoy N, Schroth G: The formation and regression of a flow-related cerebral artery aneurysm, *Clin Neurol Neurosurg*, 2000; 102:168–172. (PubMed)
28. Siddiqui AA, Sobani ZA: Bilateral hypoplasia of the internal carotid artery, presenting as a subarachnoid hemorrhage secondary to intracranial aneurysmal formation: a case report, *J Med Case Reports*, 2012; 6: 45.
29. Stam J: Thrombosis of the cerebral veins and sinuses, *N Engl J Med*, 2005; 352: 1791–1798.
30. Stern J, Whelan M, Brisman R, Correll JW: Management of extracranial carotid stenosis and intracranial aneurysms, *J Neurosurg*, 1979; 51:147–50. (PubMed)
31. Steiner T, Juvela S, Unterberg A, Jung C, Forsting M, Rinkel G: European stroke organization guidelines for the management of intracranial aneurysms and subarachnoid haemorrhage, *Cerebrovasc Dis*. 2013; 35 (2): 93–112.
32. Tufano A, Guida A, Coppola A, Nardo A, Di Capua M, Quintavalle G, Di Minno MN, Cerbone AM, Di Minno G.: Risk factors and recurrent thrombotic episodes in patients with cerebral venous thrombosis, *Blood Transfus*, 2013; 6:1–6.