

## Lumbosacral myelocystocele: A Case report

R.S. Mittal<sup>1</sup>, Pankaj Gupta<sup>2</sup>, Ashok Gandhi<sup>3</sup>, Achal Sharma<sup>4</sup>,  
Vinod Sharma<sup>5</sup>, Varsha Kumar<sup>6</sup>

<sup>1</sup>Professor & Head, Dept. Of Neurosurgery, S.M.S. Medical College, Jaipur, Rajasthan

<sup>2</sup>Senior Resident, Dept. Of Neurosurgery, S.M.S. Medical College, Jaipur, Rajasthan

<sup>3</sup>Assist. Professor, Dept. Of Neurosurgery, S.M.S. Medical College, Jaipur, Rajasthan

<sup>4</sup>Professor, Dept. Of Neurosurgery, S.M.S. Medical College, Jaipur, Rajasthan

<sup>5</sup>Assist. Professor, Dept. Of Neurosurgery, S.M.S. Medical College, Jaipur, Rajasthan

<sup>6</sup>Senior Resident, Dept. Of Pathology, SGPGIMS, Lucknow, Uttar Pradesh

### Abstract

Myelocystocele is a rare variety of spinal dysraphism that presents as a skin covered, midline, lumbosacral mass. Many a time it is associated with other congenital anomalies but isolated myelocystocele is rarely associated with neurological deficit. MRI is the modality of choice for preoperative diagnosis. A 3 years old female child presented with skin covered lumbosacral mass since birth. There was no associated neurological deficit. MRI revealed single cyst, which was continuous with central canal of spinal cord. Peroperatively, myelocystocele was found with tethering of cord. Untethering of cord and repair of myelocystocele was performed with uneventful recovery.

**Key words:** Myelocystocele, Spinal dysraphism, Myelomeningocele.

### Introduction

Myelocystocele is a rare spinal cord anomaly comprising 5-8% of all cases of spinal dysraphism. (1, 2, 6) This results from defect

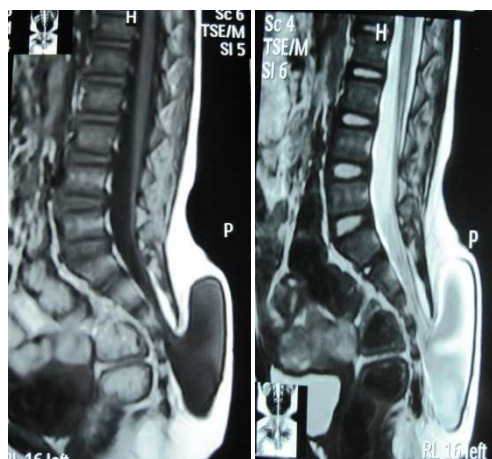in secondary neurulation. A terminal myelocystocele is composed of a low lying conus medullaris with cystic dilatation of the caudal central canal, a surrounding meningocele and a lipoma that extends from the conus to a subcutaneous fat collection. (5) The terminal cyst is lined with ependyma and dysplastic glial tissue and it does'nt communicate with subarachnoid space. (3, 4, 5) Myelocystoceles are often associated with cloacal extrophy, omphalocele, bladder extrophy, ambiguous genitalia, imperforate anus, hemi-vertebrae, sacral agenesis and pelvic abnormalities. When all these abnormalities are present, the defect is called OEIS Complex (for Omphalocele, bladder Extrophy, Imperforate anus and Spinal defect) (4). Myelocystoceles are only rarely associated with hydrocephalus or Chiari II malformation. (7) Patients with myelocystocele have normal intelligence and are usually born without neurological deficit. Therefore these defects must be identified early and repaired before

the onset or progression of lower limb weakness. (6)

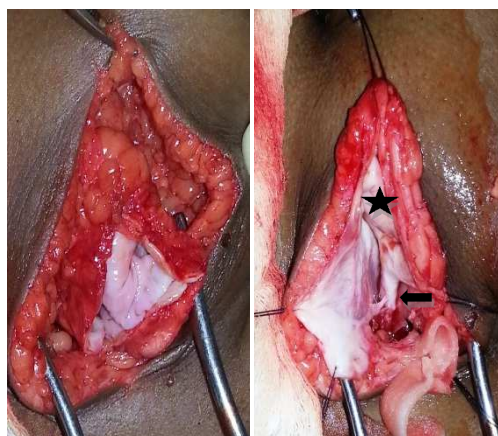
### Case report

A 3 yrs old female child presented with skin covered lumbosacral mass, which was present since birth. The swelling was gradually increasing in size. Patient was born at full term, by normal vaginal delivery. No abnormality was reported in relation to the urination and defecation. Developmental milestones, intelligence, head circumference and the neurological examination was essentially normal. The swelling was smooth, cystic, fluctuant and transilluminant, present over lumbosacral region measuring 8X8 cm. in size, covered with normal skin having well defined round borders. It was soft in consistency, dull on percussion and the cough impulse was present. MRI showed single compartment cystic swelling that was in continuation of central canal of spinal cord. It was associated with lipomeningocele at S3-S4 region, low lying cord and thickened filum terminale.

Patient was operated electively. A vertical incision was given in midline and about 50 ml CSF was drained. The cyst was explored, opened and found to be in continuation with the central canal. Central canal of cord was found dilated (Hydromyelia). Cord was tethered over S1-S2 region and was low lying type. The peroperative diagnosis was myelocystocele.



**Figure 1** - T1W1 & T2W1 MRI images of saggital cut of spinal cord is showing evidence of dilated terminal portion of central canal, continuing in cyst over sacral region,suggestive of Myelocystocele



**Figure 2** - Peroperative picture showing dilated central canal of cord (asterixis) with low lying cord and cord tethering (arrow)

The detethering of cord done and water tight repair of myelocystocele defect performed. The postoperative recovery was uneventful. No evidence of CSF leakage was there in postoperative period.

The patient is under regular follow up and doing well.

### Discussion

The myelocystocele is an unusual and rare congenital malformation of spine. The overall incidence of neural tube defect is 1:1000 live births, but variable throughout world. (3, 5) Cloacal extrophy occurs sporadically with an incidence of 1 in 200,000 to 400,000 live births. (4) No risk in siblings has been identified as no genetic association is there and myelocystocele occurs sporadically. (5) Loperamide hydrochloride, Diphenylhydantoin and Retinoic acid has been associated with myelocystoceles. Influenza vaccine has association with OEIS complex. MRI is the modality of choice for diagnosis of myelocystocele both in prenatal as well as postnatal period. (2, 6) The AFP level is usually not elevated in pregnancy as myelocystoceles are skin covered lesions. But if there is concurrent omphalocele, then AFP is elevated. (5, 7) MRI can delineate cystic mass with septations in coronal view and can show continuation with central canal of cord in saggital view. (2) It can also detect other spinal cord anomalies like tethered cord, diastematomyelia, Arnold-Chiari malformations, syringocele etc. (2) It is very difficult to diagnose myelocystocele by ultrasonography in antenatal period. (2) Myelocystoceles have been reported in cervical, thoracic and lumbosacral regions. (1, 6) Cervical myelocystocele is infrequently associated with neurological deficit whereas terminal myelocystoceles are associated with more neurological problems. (6) The whole

spinal axis including craniocervical junction should be imaged, atleast in saggital plane to evaluate other associated anomalies. (2) In contrast to meningocele repair, which is repaired at birth, repair of myelocystocele is initiated after the early stages of repair of genitourinary abnormality, if present. (1, 3) Ideally, repair of myelocystocele should be performed within first 6 months to minimize neurological loss from spinal cord tethering. (5, 7) A child with repaired myelocystocele must be monitored throughout life for symptoms and signs of retethering. (1, 6)

To summarize, myelocystocele is a rare spinal dysraphism. Our case was an isolated myelocystocele with no neurological deficits. MRI can diagnose the condition very well and excellent outcome can be achieved by an early repair of the defect.

#### Footnotes:

*Source of support:* Nil.

*Conflicts of interest:* None declared.

#### Correspondence Address:

*Dr. Ashok Gandhi (Mch.)*

*Assist. Professor (Neurosurgery)*

*Deptt. Of Neurosurgery, S.M.S. Medical College, Jaipur, Rajasthan, 302004.*

*Email: drpankaj.gupta@yahoo.co.in  
gandhineuro@gmail.com*

#### References

1. Konya D, Dacinar A, Akakin A, Gercek A, Ozgen S, Pamir M. Cervical meningocele causing symptoms in adulthood: Case report and review of the literature. *J Spinal Disord Tech.* 2006;19:531-3.[PubMed]
2. Feltes CH, Fountas KN, Dimopoulos VG, Escura AI, Boev A, Kapsalaki EZ, et al. Cervical meningocele in association with spinal abnormalities. *Childs Nerv Syst.*

2004;20:357-61. [PubMed]

3. Andronikou S, Wieselthaler N, Fieggen AG. Cervical spina bifida cystica: MRI differentiation of the subtypes in children. *Childs Nerv Syst.* 2006;22:379-84.[PubMed]

4. Bilal Mirza, Nasir Mahmood, Lubna Ijaz, Tariq Khawaja, Imaran Aslam, Afzal Sheikh. Isolated Terminal Myelocystocele: A Rare Spinal Dysraphism. *APSP J Case Rep.* 2011;Jan-Apr: 2: 3.

5. Ramesh V, V Chandra, Phani M Kumar. Cervical

myelocystocele: Case report and review of literature. *J Pediatr Neurosci.* 2011; Jan-Jun: 6: 55-57.

6. Ochiai H, Kawano H, Miyaoka R, Nagano R, Kohno K, Nishiguchi T, et al . Cervical (non-terminal) myelocystocele associated with rapidly progressive hydrocephalus and Chiari type II malformation--case report. *Neurol Med Chir (Tokyo).* 2010;50:174-7.

7. Kumar R, Chandra A, Terminal Myelocystocele. *Indian J Pediatr.* 2002;69:1083-1086.[PubMed]