

## Traumatic pseudoaneurysm of Superficial Temporal Artery - a case report with review of literature

Saurabh Jain<sup>1</sup>, Vinod Sharma<sup>2</sup>, R.S. Mittal<sup>3</sup>

<sup>1</sup>Resident, Department of Neurosurgery, SMS Hospital, Jaipur, Rajasthan, India

<sup>2</sup>Assistant Professor, Department of Neurosurgery, SMS Hospital, Jaipur, Rajasthan, India

<sup>3</sup>Professor and Head, Department of Neurosurgery, SMS Hospital, Jaipur, Rajasthan, India

### Abstract

Superficial temporal artery (STA) pseudoaneurysm is uncommon and usually is the result of trauma to the front temporal region. The appearance of a pulsatile preauricular mass chronologically related to trauma is highly suggestive of the diagnosis. Here we discuss a case of trauma to head presented with pseudoaneurysm of frontal branch of temporal artery and its management.

**Key words:** Trauma, Pseudoaneurysm, Cerebral angiography, superficial temporal artery.

### Introduction

Superficial temporal artery is one of the two terminal branches of External Carotid Artery. It supplies Scalp of frontal and parietal region. This artery is one of the most common arteries vulnerable for trauma in scalp injuries due to relatively exposed course over the temporal bone<sup>2</sup>. Few reports are available for development of aneurysm in this artery after trauma. Superficial temporal artery (STA) pseudoaneurysm is uncommon and usually is

the result of trauma to the front temporal region. The appearance of a pulsatile preauricular mass chronologically related to trauma is highly suggestive of the diagnosis. Here we discuss a case of trauma to head presented with pseudoaneurysm of frontal branch of temporal artery and its management.

### Case

A 20 - year - old male with history of trauma to the head causing laceration in frontal region two month back came to our out patient facility with history of pulsatile swelling in left frontal region. On detailed questioning patient revealed that two month back he met an accident while riding a motorbike. He got a lacerated wound over the scalp frontal region. This wound was repaired in emergency department. For about one and a half month patient was doing well when he noticed a pulsatile swelling in his frontal region away from the wound scar. The swelling was progressively increasing in size and pulsatile. On examination there was a healed scar at left frontal region of about 2 cm oriented vertically (figure 1).

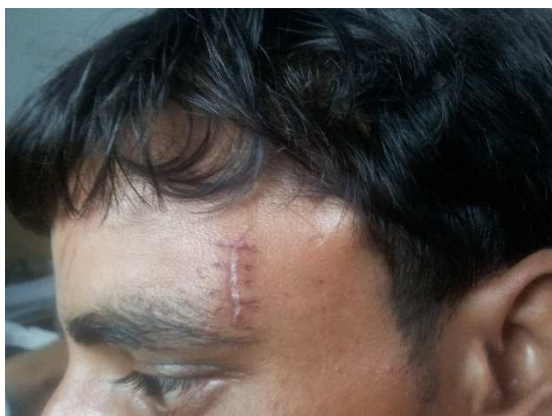

Figure 1

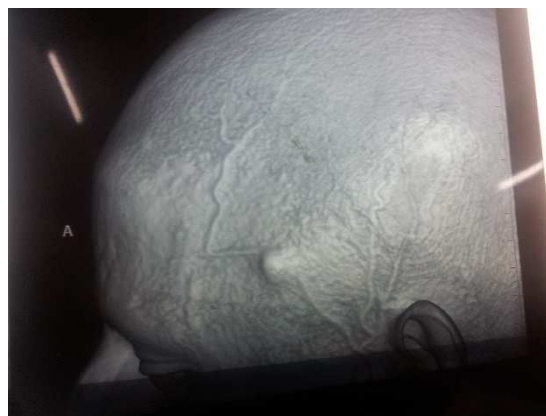


Figure 4

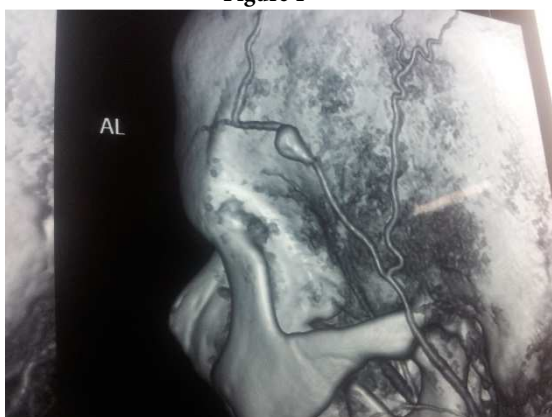

Figure 2

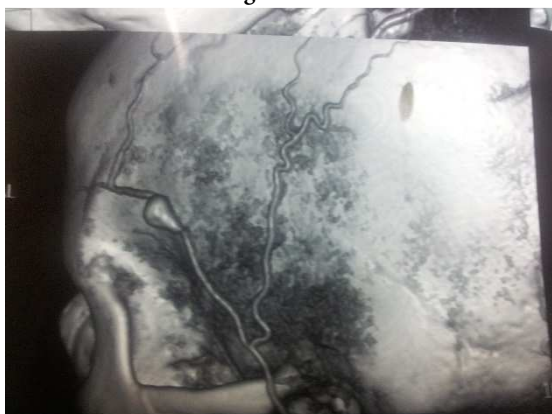

Figure 3

There was a swelling in left frontal region about six cm away from the upper margin of scar. The swelling was single, situated in left frontal region of about 1.5 cm length and one cm breadth, pulsatile, warm to touch and compressible.

A formal diagnosis of superficial temporal artery aneurysm of frontal branch was made. Patient was subjected for CT angiography head with three dimensional reconstructions (figures 2, 3 and 4). CT angiography confirmed the diagnosis. Surgical excision of aneurysm with ligation of both ends was done under local anesthesia.

### Discussion

Superficial temporal artery is a terminal branch of external carotid artery. It is of the most important artery of the scalp. Most of the scalp flaps raised for various craniotomies are based on it. It is the sole artery for ST-MC bypass procedure. Pseudoaneurysm of STA is uncommon with approximately 200 cases reported in the literature (1, 3).

Bartholin was the first one to report such an aneurysm in 1740 secondary to trauma. The most important cause of this pathology remains to be trauma whether it is war related, contact sports, road accident or iatrogenic<sup>1</sup>. STA aneurysms are usually solitary though multiple aneurysms following a craniotomy in hemophiliac have been reported.

The STA, after originating from the external carotid artery at the base of the parotid gland runs through a relatively exposed course over the temporal bone<sup>2</sup>.

The diagnosis of STA aneurysms can usually be made by history and physical examination. The usual presenting symptom is a pulsating swelling in the temporal region or a throbbing headache.

The treatment of STA aneurysms varies from a conservative method such as repeated

compression of the lesion to surgical excision of the lesion (2).

**Correspondence:**

*Dr. Saurabh Jain  
33, Uniara Gardens,  
Near Trimurti Circle,  
Jaipur, Rajasthan, India  
Email- drsaurabh\_jain@rediffmail.com  
Mobile- +91 9828954850*

**References**

1. Cheng CA, Southwick EG, Lewis EC II. Aneurysms of the superficial temporal artery: literature review and case reports. *Ann Plast Surg* 1998;40:668-671
2. Fox JT, Cordts PR, Gwinn BC. Traumatic aneurysms of the superficial temporal artery: Case report. *J Trauma* 1994;36:562-4.
3. Porcellini M, Bernardo B, Spinetti F, Carbone F. Outpatient management of superficial temporal artery aneurysms. *J Cardiovasc Surg* 2001;42:233-236