

Intraoperative neuronavigation integrated high resolution 3D ultrasound for brainshift and tumor resection control

A. Giovani¹, F. Brehar, Narcisa Bucur, D. Martin¹, R.M. Gorgan

¹PhD Student, "Carol Davila" University of Medicine and Pharmacy, Bucharest
"Bagdasar-Arseni" Emergency Clinical Hospital, Bucharest

Abstract: INTRODUCTION: The link between the neurosurgeon's knowledge and the scientific improvements made a dramatic change in the field expressed both in impressive drop in the mortality and morbidity rates that were operated in the beginning of the XXth century and in operating with high rates of success cases that were considered inoperable in the past. Neuronavigation systems have been used for many years on surgical orientation purposes especially for small, deep seated lesions where the use of neuronavigation is correlated with smaller corticotomies and with the extended use of transulcal approaches. The major problem of neuronavigation, the brainshift once the dura is opened can be solved either by integrated ultrasound or intraoperative MRI which is out of reach for many neurosurgical departments. METHOD: The procedure of neuronavigation and ultrasonic localization of the tumor is described starting with positioning the patient in the visual field of the neuronavigation integrated 3D ultrasonography system to the control of tumor resection by repeating the ultrasonographic scan in the end of the procedure. DISCUSSION: As demonstrated by many clinical trials on gliomas, the more tumor removed, the better long term control of tumor regrowth and the longer survival with a good quality of life. Of course, no matter how aggressive the surgery, no new deficits are acceptable in the modern era neurosurgery. There are many adjuvant methods for the neurosurgeon to achieve this maximal and safe tumor removal, including the 3T MRI combined with tractography and functional MRI, the intraoperative neuronavigation and neurophysiologic monitoring in both anesthetized and awake patients. The ultrasonography integrated in neuronavigation comes as a welcomed addition to this adjuvants to help the surgeon achieve the set purpose. CONCLUSION: With the use of this real time imaging device, the common problem of brainshift encountered with the neuronavigation systems is covered and any eventual tumor residue can be spotted by ultrasonography and resected.
Key words: high resolution 3D ultrasound, neuronavigation, glioma

Introduction

Neurosurgery is a very fast changing field of medicine and keeping up to date with new technologies is a must. This link between the neurosurgeon's knowledge and the scientific improvements made a dramatic change in the field expressed both in impressive drop in the mortality and morbidity rates that were operated in the beginning of the XXth century and in operating with high rates of success cases that were considered inoperable in the past.

The neuronavigation systems are as useful for orienting in the operative field as is the operative microscope or endoscope for visualization and MRI is for locating the lesion and designing an operative strategy. Yet many of the experts rely on their orientation based on anatomical knowledge limiting the use of neuronavigation for small, deep seated lesions (less than 3 cm). In this cases it has been demonstrated that the use of neuronavigation is correlated with smaller corticotomies and with the extended use of transulcal approaches.

A study in 2000 [1] presented for the first time the integration of neurosurgery into an ultrasound machine as a method to cope with normal anatomic changes during brain surgery, known as brainshift.

Compared to other methods against brainshift like intraoperative MRI, interventional MRI the ultrasound even in 2D or 3D offers real time images is much easier to use and needs less investment both of the time of the procedure and in the set up for the MRI system and special operating rooms. [5, 6, 22]

Compared to the MRI the ultrasound has a poor image quality and it is difficult to interpret, in part due to the fact that it is not regularly used in neurosurgery.

The first neuronavigation integrated to a ultrasonography system was used since November 1997 at the University Hospital in Trondheim. [1]

There are only a few studies to compare intraoperative MRI with neuronavigation integrated ultrasonography and they conclude that iMR is the most advanced and reliable intraoperative imaging modality but given to the limited applicability due to high costs and especially designed operating rooms intraoperative ultrasonography is an acceptable alternative. [8, 9, 17, 20]

Method

In order to use this combined system a fine slice MRI with fiducials applied on the scalp of the patient should be performed in the day before or the day of the surgery. We avoid performing this MRI scan more than 1 day before surgery as the marks on the scalp may vanish giving an unacceptable error for navigation.

We will chose for navigation from the acquired images the larger image series, either T1 or T2, or we can choose both and switch between them when needed.

While loading the data into the Sonowand system the patient's head is fixed in a Mayfield head holder. A Mayfield Frame with 4 reflecting spheres is fixed to the device and a nonsterile probe pointer with 4 reflecting spheres attached is used to register the points marked with fiducials on the scalp. Usually

after the first 3 or 4 points are registered in the frameless navigation system the pointer in the surgeon's hand appears on the screen.

During this procedure the three cameras of the video acquisition system should be pointed towards the surgeon's hand as to include both the Mayfield frame and the pointer device. An error less than 2 mm is acceptable. Then the incision spot is drawn on the skin and the operative field is properly draped. Before the craniectomy the sterile neuronavigation probe can be used again to avoid dural veins or dural lakes when performing the burr holes. Before and after the dural incision both the neuronavigation pointer and the ultrasound probe can be used to identify the best spot for cortical incision. This should take into account the shorter path to the middle of the lesion and the avoidance of the eloquent cortex.

The position of the ultrasound plane is shown on the monitor as the ultrasound probe has attached 4 reflecting spheres to integrate it into the neuronavigation system. The system can build 3D ultrasound images based on a slow freehand movement of the probe over the cortex for 15-30 seconds. The ultrasound image can be superimposed on the MRI slices or can be seen in a separate screen. By rotating the neuronavigation or the ultrasound probe, different images are acquired the image shifts between the 3 planes (sagittal, coronal and horizontal).

When the margin of the tumor facing the surgeon is reached the tip of the probe is used to mark it and after tumor removal the probe is inserted in the cavity to show the extent of removal. At this point when the resection is macroscopically total, the ultrasound is used

again with continuous irrigation of the cavity to verify if there is any tumor remnant left.

We have a limited experience with this device, only 7 patients, but it proved very useful in localizing and documenting the tumor resection. We used this device in cases of metastases, malignant or low grade gliomas or in cases of other intraparenchymal lesions like cavernomas especially when the lesion was located in or near the eloquent areas.

Depending on the MRI sequence that is included in the study more information about the surroundings of the tissue can be gained. For some cases where we found important vessels in close contact with the tumor we used an angio MRI sequence superimposed on the regular T1 image that we used for navigation. This proved very useful especially when performing the ultrasonography 3D acquisition.

Discussion

Since the first experiments with ultrasound on human brain in 1950, 20 years passed for the real time 2D imaging to be introduced into clinical trials and 10 more years till this technology became available on the market. Nowadays most of the neurosurgical departments in high volume centers around the world have access to this technology. [11, 15, 20] Its use is both in localizing the lesions, especially when these are small and located in eloquent cortex and in assessing the degree of tumor removal. In this era of evidence based medicine along with the microscope this device stands as a proof of the quality of surgery. [17, 21, 23]

As demonstrated by many clinical trials on

gliomas, the more tumor removed, the better long term control of tumor regrowth and the longer survival with a good quality of life. Of course, no matter how aggressive the surgery, no new deficits are acceptable in the modern era neurosurgery.[16,18,19] There are many adjuvant methods for the neurosurgeon to achieve this maximal and safe tumor removal, including the 3T MRI combined with tractography and functional MRI, the intraoperative neuronavigation and neurophysiologic monitoring in both anesthetized and awake patients. The ultrasonography integrated in neuronavigation comes as a welcomed addition to this adjuvants to help the surgeon achieve the set purpose. [4, 7f]

Some authors used all these methods combined in a series of patients both with high grade and low grade gliomas reporting an increased rate of tumor resection compared to the cases without the use of this techniques, yet further long time studies on the recurrence of the tumors are needed to prove the benefit of using this advanced technologies for the life and the survival of the patients. [10, 12, 14]

Conclusion

The ultrasound integrated neuro-navigation system is an invaluable tool, cost benefit acceptable, compared to other methods, for the intraoperative detection and removal of tumor remnants, after achieving macroscopic gross total resection. With the use of this real time imaging device, the common problem of brainshift encountered with the neuronavigation systems is covered.

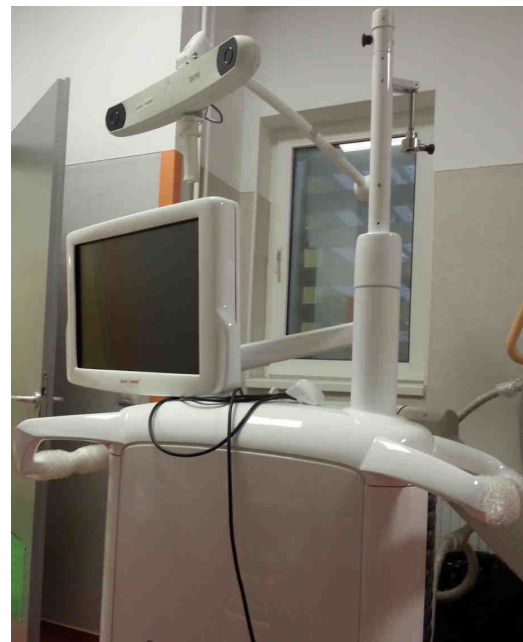

Figure 1 - neuronavigation integrated ultrasonography system: the 3 video cameras are visible on an articulated arm above the touch screen monitor

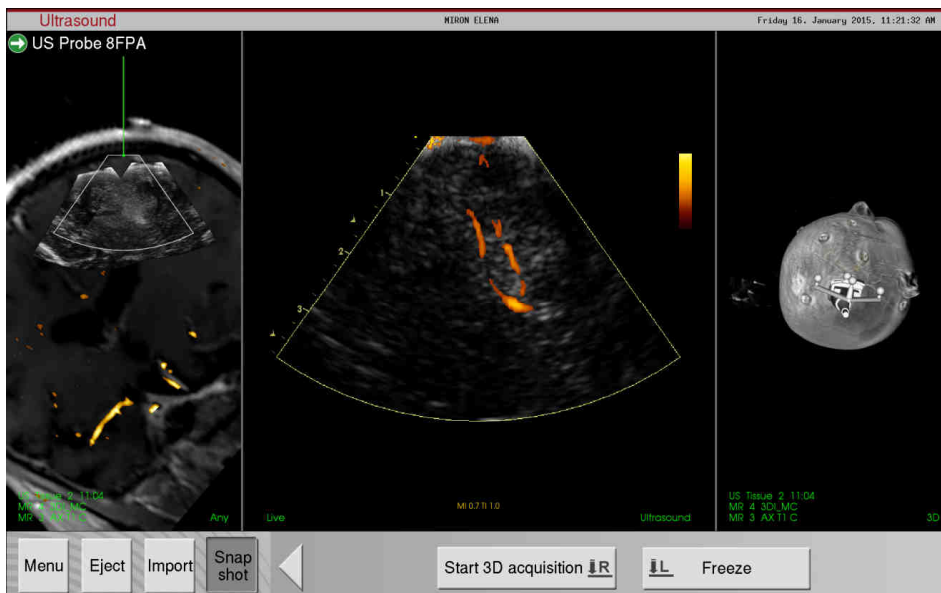


Figure 2 - in this case of parietal glioblastoma, the 52 yo woman presented for headache and left sided motor seizures; after performing the craniotomy the ultrasound probe scans the dura for the 3D image acquisition to be superimposed on the neuronavigation MRI images. In this case we used both T1 and angio MRI images and the relation of the tumor with the vessels on its surface is shown (orange)

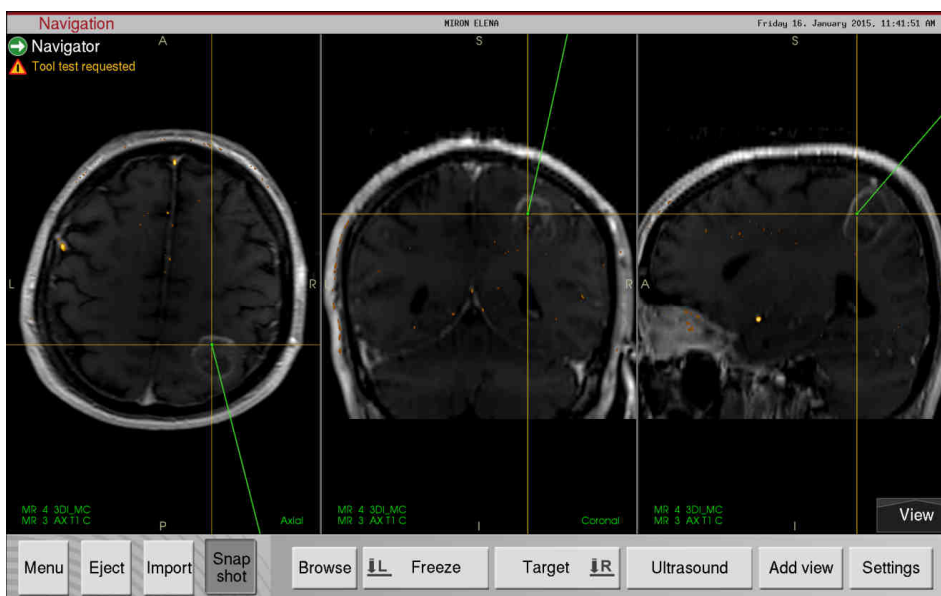


Figure 3 - the same case during tumor removal when macroscopic total resection was achieved. The green line is the neuronavigation probe touching the margins of the resection cavity. The tip of the instrument stops before reaching the deep margin of the tumor, indirect sign that there is some tumor residue

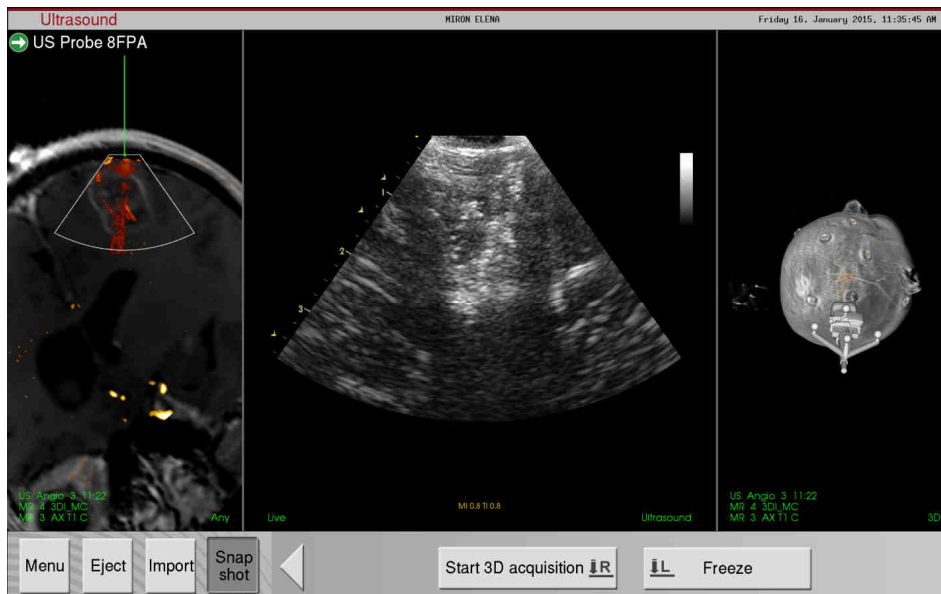


Figure 4 - the same case after tumor removal, on the central ultrasound image the resection cavity can be observed: under continuous irrigation with serum after H₂O₂ has been applied in the cavity to obtain hemostasis, oxygen bubbles can be seen inside the resection cavity. Superimposing this set of images on the first set of images gives information about the degree of tumor resection

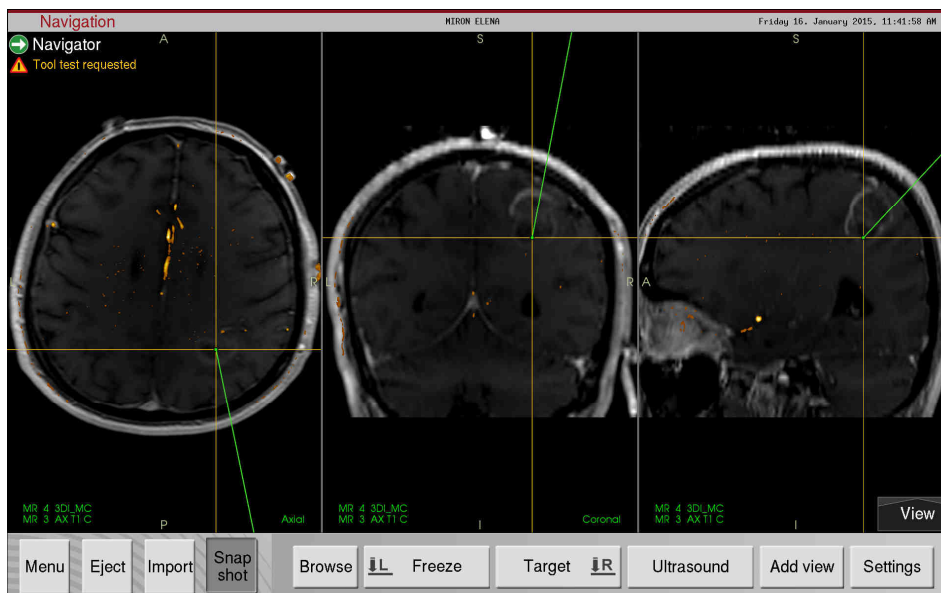


Figure 5 - the same case in the end of the surgery when the rest of the tumor was removed and the tip of the probe is reaching the distal margin of the tumor. This check should be done for all the walls of the tumor

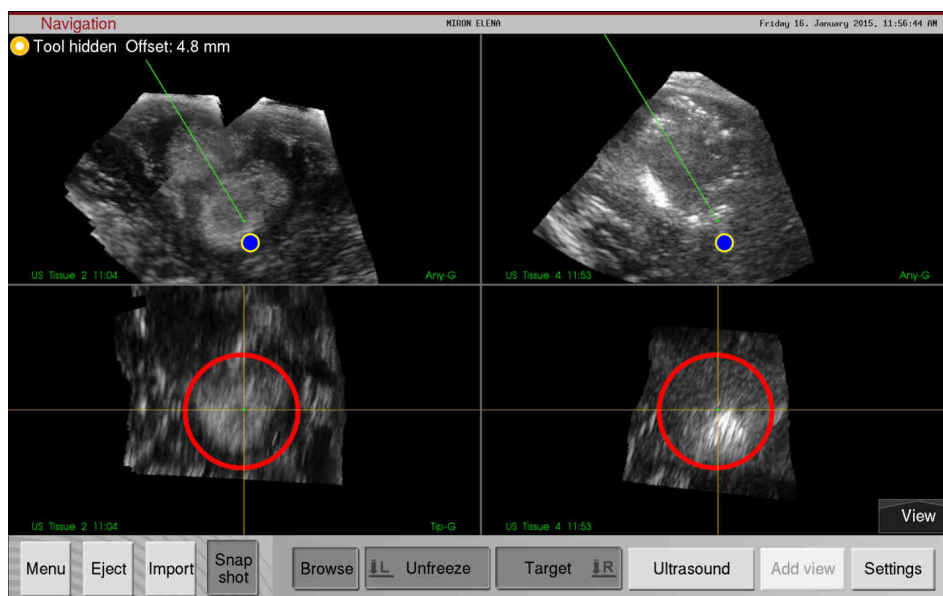


Figure 6 - Comparing the 3D acquisition data before (left) and after (right) the tumor resection showing a 4.8 mm brainshift. In order to limit the brain shift the head must be kept in a neutral position and the operating field should be continuously irrigated

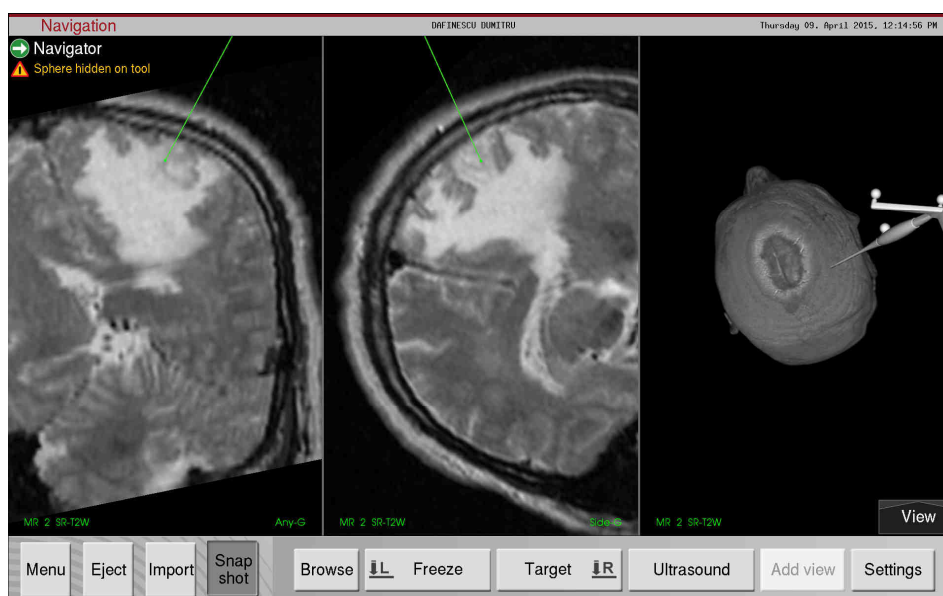


Figure 7 - navigating on a T2 MRI sequence in this case of lung cancer metastasis in a 62 yo heavy smoker man. After the tumor removal the pointer touches the deep margin of the tumor

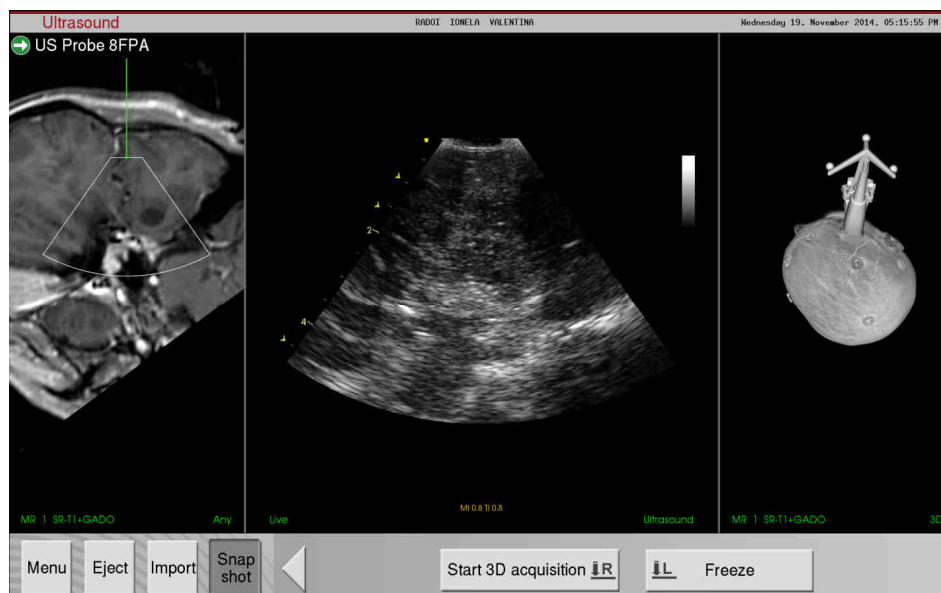


Figure 8 - oxygen bubbles on ultrasound filling the resection cavity of a pseudocystic hypocampal glioma in a 30 yo woman presenting with mesial temporal lobe epilepsy (MTLE) for generalized seizures and temporal seizures with euphoric and aggressive behavior

References

1. Aage Gronningsaeter, Ph.D., Atle Kleven, M.S., Steinar Ommedal, B.S., Tore Erling Aarseth, M.S., Torgrim Lie, M.S., Frank Lindseth, M.S., Thomas Langø, M.S., Geirmund Unsgård, M.D., SonoWand, an Ultrasound-based Neuronavigation System, *Neurosurgery* 47:1373–1380, 2000
2. Claus EB, Horlacher A, Hsu L, Schwartz RB, Dello-Iacono D, Talos F, et al: Survival rates in patients with low-grade glioma after intraoperative magnetic resonance image guidance. *Cancer* 103:1227–1233, 2005
3. Smith JS, Chang EF, Lamborn KR, Chang SM, Prados MD, Cha S, et al: Role of extent of resection in the long-term outcome of low-grade hemispheric gliomas. *J Clin Oncol* 26: 1338–1345, 2008
4. Holodny AI, Schwartz TH, Ollenschleger M, Liu WC, Schulder M: Tumor involvement of the corticospinal tract: Diffusion magnetic resonance tractography with intraoperative correlation. *J Neurosurg* 95:1082, 2001.
5. Nimsky C, Gansland O, Cerny S, Hastreiter P, Greiner G, Fahlbusch R: Quantification of, visualization of, and compensation for brain shift using intraoperative magnetic resonance imaging. *Neurosurgery* 47:1070–1080, 2000.
6. Nimsky C, Gansland O, Hastreiter P, Fahlbusch R: Intraoperative compensation for brain shift. *Surg Neurol* 56:357–365, 2001.
7. Pierpaoli C, Jezzard P, Basser PJ, Barnett A, Di Chiro G: Diffusion tensor MR imaging of the human brain. *Radiology* 201:637–648, 1996.
8. Unsgaard G, Ommedal S, Muller T, Gronningsaeter A, Nagelhus Hernes TA: Neuronavigation by intraoperative three-dimensional ultrasound: Initial experience during brain tumor resection. *Neurosurgery* 50:804–812, 2002.
9. Auer LM, van Velthoven V: Intraoperative ultrasound (US) imaging: Comparison of pathomorphological findings in US and CT. *Acta Neurochir (Wien)* 104:84–95, 1990
10. Berger MS, Deliganis AV, Dobbins J, Keles GE: The effect of extent of resection on recurrence in patients with low grade cerebral hemisphere gliomas. *Cancer* 74:1784–1791, 1994
11. Black PM, Moriarty T, Alexander E III, Stieg P, Woodard EJ, Gleason PL, et al: Development and implementation of intraoperative magnetic resonance

- imaging and its neurosurgical applications. *Neurosurgery* 41:831–845, 1997
12. Chacko AG, Kumar NK, Chacko G, Athyal R, Rajshekhar V: Intraoperative ultrasound in determining the extent of resection of parenchymal brain tumours—a comparative study with computed tomography and histopathology. *Acta Neurochir (Wien)* 145:743–748, 2003
13. Chandler WF, Knake JE, McGillicuddy JE, Lillehei KO, Silver TM: Intraoperative use of real-time ultrasonography in neurosurgery. *J Neurosurg* 57:157–163, 1982
14. Fahlbusch R, Samii A: A review of cranial imaging techniques Lindner D, Trantakis C, Renner C, Arnold S, Schmitgen A, Schneider J, et al: Application of intraoperative 3D ultrasound during navigated tumor resection. *Minim Invasive Neurosurg* 49:197–202, 2006
15. Mäurer M, Becker G, Wagner R, Woydt M, Hofmann E, Puls I, et al: Early postoperative transcranial sonography (TCS),
16. Nimsky C, Ganslandt O, Buchfelder M, Fahlbusch R: Intraoperative visualization for resection of gliomas: The role of functional neuronavigation and intraoperative 1.5 T MRI. *Neurol Res* 28:482–487, 2006
17. Nimsky C, Ganslandt O, Kober H, Buchfelder M, Fahlbusch R: Intraoperative magnetic resonance imaging combined with neuronavigation: a new concept. *Neurosurgery* 48:1082–1091, 2001
18. Regelsberger J, Lohmann F, Helmke K, Westphal M: Ultrasound guided surgery of deep seated brain lesions. *Eur J Ultrasound* 12:115–121, 2000
19. Roth J, Biyani N, Beni-Adani L, Constantini S: Real-time neuronavigation with high-quality 3D ultrasound SonoWand in pediatric neurosurgery. *Pediatr Neurosurg* 43:185–191, 2007
20. Rubin JM, Quint DJ: Intraoperative US versus intraoperative MR imaging for guidance during intracranial neurosurgery. *Radiology* 215:917–918, 2000
21. Rygh OM, Nagelhus Hernes TA, Lindseth F, Selbekk T, Brostrup Müller T, Unsgaard G: Intraoperative navigated 3-dimensional ultrasound angiography in tumor surgery. *Surg Neurol* 66:581–592, 2006
22. Tronnier VM, Bonsanto MM, Staubert A, Knauth M, Kunze S, Wirtz CR: Comparison of intraoperative MR imaging and 3D-navigated ultrasonography in the detection and resection control of lesions. *Neurosurg Focus* 10(2):E3, 2001
23. Unsgaard G, Rygh OM, Selbekk T, Selbekk T, Brostrup Müller T, Unsgaard G: Intra-operative 3D ultrasound in neurosurgery. *Acta Neurochir (Wien)* 148:235–253, 2006