

Temporo-sylvian anastomosis and aneurysm clipping in a case of left M1 aneurysm with progressive evolution after initial embolization; Case report

Georgiana Ion¹, A. Chiriac, I. Poata

“Grigore T. Popa” University of Medicine and Pharmacy, Iasi

¹“Prof. Dr. N. Oblu” Clinic Emergency Hospital, Iasi

Abstract: A giant unruptured middle cerebral artery aneurysm partially thrombosed, previously endovascularly treated after a mild right hemiparesis remitted. After 12 months, in routine check we discovered a reperfusion of the aneurysm and decide EC-IC bypass and clipping, with a good outcome.

Introduction

Complex intracranial aneurysms are among the most challenging lesions faced by neurosurgeons. Among them are mentioned giant aneurysms and those with an intraluminal thrombus that can dislodge emboli into the vascular territory. Partially thrombosed aneurysms, is defined to be those aneurysms in which the diameter of the aneurysm as detected by cross-sectional studies is larger than the diameter of the perfused aneurysm detected by digital subtraction angiography. It is suggested that the giant intracranial aneurysm grows by recurrent hemorrhage into its wall and behaves like growing encapsulated hematomas. The neurosurgical approach often requires techniques other than conventional clipping, such as bypass and clip reconstruction. Disadvantage of coiling is the

migration of coils into the thrombus during follow-up.

Case Report

A 53-years-old female first presented 1 year ago with headache, right hemiparesis and aphasia, remitted in a few days. Brain computer tomography imaging raised suspicion of a MCA aneurysm. The diagnosis was confirmed by the angio-CT and by the digital subtraction angiography.

It was observed a 12x18mm left M1 segment, saccular aneurysm with broad-based neck. The aneurysm was treated by coil embolization. Under local lidocaine anesthesia, a 6.0 Fr guiding catheter was introduced into the left carotid artery via the transfemoral approach. Then a coaxial microcatheter under fluoroscopic guidance

was introduced through the left carotid artery, into the MCA and finally into the aneurysm.

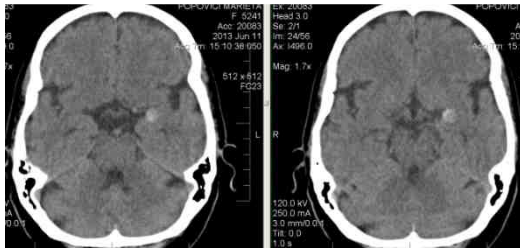


Figure 1 - Initial CT scan- hyperdense area on the topography of the left sylvian fissure

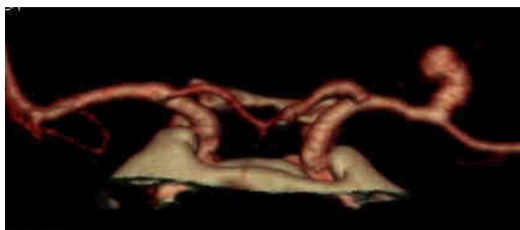


Figure 2 - Angio-CT reconstruction

After the first coil placement 5000 U of intravenously heparin were used for systemic anticoagulation and another 5000 U at the end of the procedure. To achieve occlusion were placed five coils. Post embolization angiography showed a approximately 90% occlusion, with a a portion of the neck of the aneurysm not closed. Further packing of the aneurysm would have carried a high risk of parent artery compromise because of the large aneurysm neck that appeared to be incorporated into the parent artery. CT scan follow-up 4 month later showed nothing abnormal, but after 12 month CT scan, angio-CT and cerebral MRI point-out a giant MCA aneurysm, partially thrombosed. The next step was to perform an angiography, were is

observed an M1 segment giant aneurysm near the one previous occluded.

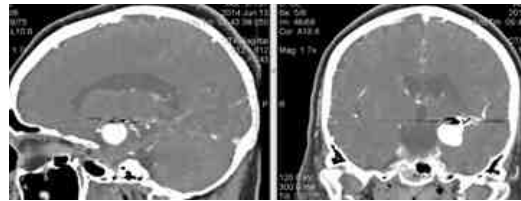


Figure 3 - Angio-CT reconstruction after 12 months follow-up

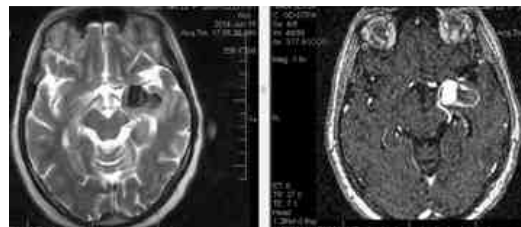


Figure 4 - T2 and TOF weighted sequences 12 months after embolization

It can be seen that the coils are scattered and have a different conformation, showing a regrowth and recanalization of the aneurysm.

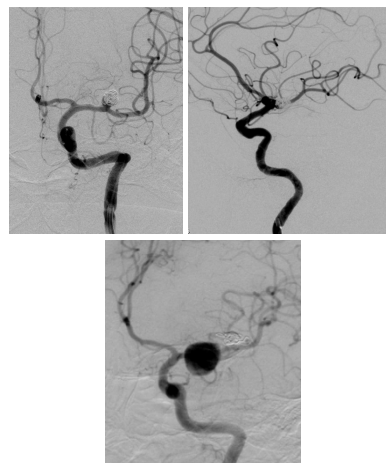


Figure 5 - top images-control angiography after embolization; bottom image-control angiography after 12 month

It was decided that the best method of treatment in this case would be the surgical one, clip reconstruction and obliteration of the aneurysm and a by-pass between superficial temporal artery and sylvian artery. First we studied angiographically STA and then we have identified it with Doppler ultrasound.

A left pterional approach was performed, the afferent (ICA and MCA), and efferent vessels were then dissected and the aneurysmal neck was exposed. A temporary clip was placed on the M1 segment for less than 2 minutes, and the aneurysm was closed with multiple fenestrated clips. After securing the aneurysm, the sac was opened for endarterectomy and reconstruction of the arterial wall with suture.

STA-MCA bypass is a technique that allows the blood supply from the extracranial carotid circulation to be routed to the distal middle cerebral artery branches, to increase flow to the distal MCA territory. First STA-MCA anastomoses were made by Yasargil for the treatment of complex intracranial aneurysms or for cerebrovascular occlusive disease.

Procedure

Preoperative preparation consists of computed tomography scan and Digital subtraction angiography

The STA, in the most cases bifurcates in the preauricular region into a frontal and parietal branch, with some anatomic variations: one branch dominant, both branches of the same caliber, or atresia of the parietal branch. The donor artery branch of the STA must to be more than 1mm in diameter and is identified by Doppler ultrasound. To expose and isolate

the STA branch, after the skin incision and dissection of an acceptable length of the artery then is irrigated with heparinized saline, temporary clipped at the distal extremity and stored in a wet gauze. A suitable M4 branch of the MCA is dissected, mobilized for 2 cm and isolated in a rubber barrier. The blood pressure is elevated and the cerebral metabolic activity is reduced with barbiturates or propofol. After the small temporary clip is placed on the M4 branch, the vessels are irrigate with papaverine solution. An end to end anastomosis, a running suture with an 9-0/10-0 nylon microsuture with noncutting needle. After the suture is ready the temporary clamps are removed from the recipient and donor vessels, and flow is established. A small amount of leakage of blood at the suture site is acceptable and can be diminish with an application of a small amount of Surgicel. When closing, have to rongeur an adequate portion of the craniotomy flap and to suture the temporalis muscle loosely to prevent compression of the graft. The patient's blood pressure is kept above 110 systolic to prevent graft occlusion. Postoperatively, in the first 24h, patient was with a right central facial paresis and right sided hemiparesis (4/5 MRC), that resolved in a few days. At the control CT scan was observed a hypodense area in the left caudate nucleus. For a better view of the permeability of the anastomosis was performed an angio-CT scan.

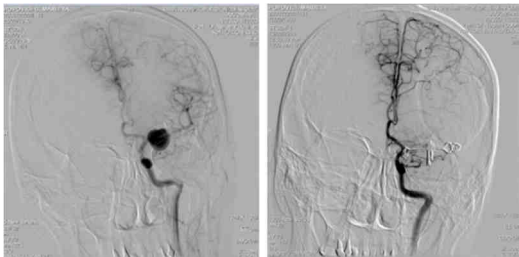


Figure 7 - Before and after surgical treatment angiography

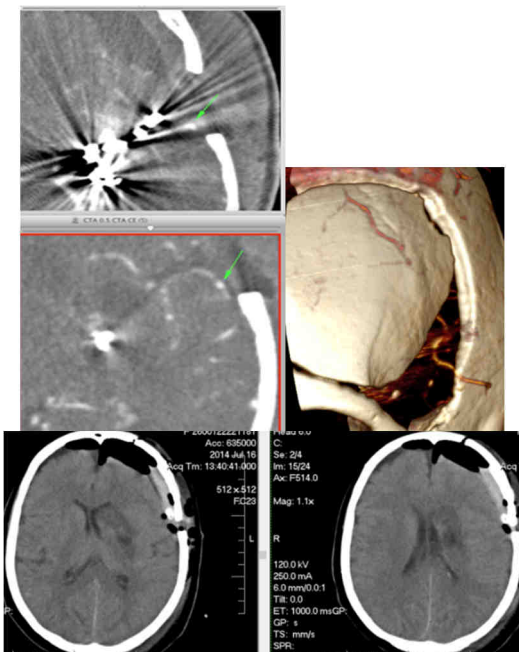


Figure 6 - top images-angioCT images with STA-MCA by-pass (arrow); bottom images-native CT scan

No complication was observed during or after surgery. Clinically, the patient was discharged only with a right facial paresis. After 2 months, for a better analysis of the anastomosis and the circulation and cerebral perfusion we thought that the angiography is more conclusive. It highlights the complete closure of the aneurysm and left two-thirds of the M1 segment, and re-permeabilisation of the

left MCA territory at an SCA-MCA anastomosis and by collateral circulation from the left anterior cerebral artery and posterior circulation (PCA). The occlusion of the parent vessel (M1) can be caused by a thrombus or the atherosclerotic plaque.

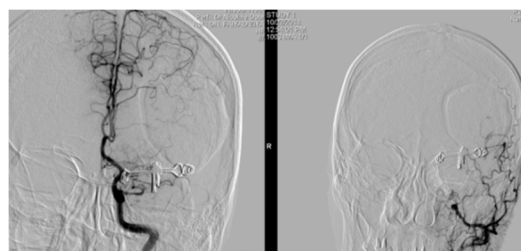


Figure 8 - Control angiography 2 months after surgery

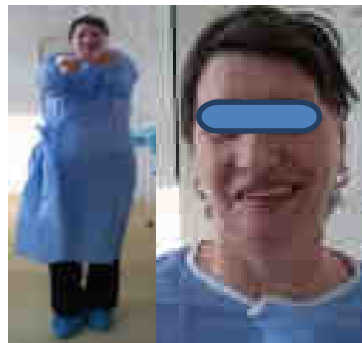

Figure 9 - clinical outcome 2 months after surgical treatment; right facial paresis

Discussion

The first question we must ask is whether there it originally was a giant aneurysm or if it developed further. Initial catheter angiography and angio-CT scans failed to disclose a giant aneurysm partially thrombosed or a blister aneurysm that may progress to a giant aneurysm to time. The residual neck observed on the angiographic control may be associated with aneurysm

regrowth. Although statistical data are not sufficient, there are studies that support this theory.

In a study of Murayama, et al. it was reported that aneurysms with a neck remnant after embolization 30% remained unchanged, 30% thrombosed and 30% showed recanalization.

Interlocking detachable coils were deposited into the patent portion of the aneurysm, resulting in 95% obliteration of the aneurysm and preservation of the parent artery. Reperfusion is not a rare complication following coiling. Some studies regarding endovascular treatment of the partially thrombosed intracranial aneurysms showed that this is not the first or the best treatment option. Reopening after coiling is frequent—21% in the literature and retreatment was often needed (10%) and this is due to the migration of the coil mass into the thrombus. In cases in which surgical treatment or parent vessel occlusion is not possible, placement of a flow diverter is an option. 86% of aneurysms treated by carotid artery ligation were not visualized postoperatively or reduced in dimensions, after a study of Roski and Spetzler. Partially thrombosed aneurysm pathophysiology is controversial. Some suggest that in the development of this aneurysm by proliferation, inflammation and rupture is involved vasa vasorum of the wall, but most of the theories conclude that the growth of these aneurysms is determined by the dissection of the aneurysm wall. So, this explains why in case of endovascular treated partially thrombosed aneurysms, dissection may continue at the level of the remaining

neck. Review of the patient's previous images we realize that probably would have been required an MRI exploration at the first presentation in the hospital. Regarding the initial symptomatology, given that the right hemiparesis and aphasia were transient, probably were caused by small thrombus that had migrated into the distal circulation and less likely determined by the mass effect of the aneurysm. On the initial CT scan there were no signs of SAH.

Follow-up angiography (2 months later) revealed obliteration of the aneurysm and the parent vessel, but with a good compensation through the collateral circulation and from the external carotid artery via the anastomosis, all these evidenced by the absence of symptomatology.

Conclusion

In the future, angiographic and long-term clinical follow-up is needed, not for a routine but in case of expansive aneurysms, with known residual necks or broad-based ones. Vascular by-pass of aneurysm with subsequent clipping was the best option in this case.

In selected cases of partially thrombosed aneurysms the best treatment option may be the use of flow-diverting stents.

If on follow-up imaging growth of the aneurysm is detected, surgical or endovascular procedures should be considered because the prognosis of these patients is poor.

References

1. David W. Newell, M.D, Superficial Temporal Artery to Middle Cerebral Artery Bypass. *J Neurosurg*. 2005 May; 15(2): 133–141.

- 2.H. Hunt Batjer, M.D., Alan I. Frankfurt, M.D., Phillip D. Purdy, M.D., Shirley S. Smith, M.D., and Duke S.Samson, M.D., .Use of etomidate, temporary arterial occlusion, and intraoperative angiography in surgical treatment of large and giant cerebral aneurysms, University of Texas Health Science Center
- 3.Carlos A. David, M.D., A. Giancarlo Vishteh, M.D., Robert F. Spetzler, M.D., Michael Lemole, M.D., Michael T.Lawton, M.D., and Shahram Partovi, M.D., Late angiographic follow-up review of surgically treated aneurysms, . Journal of Neurosurgery,September 1999 / Vol. 91 / No. 3 / Pages 396-401
- 4.Robert A. Mericle, M.D., Ajay K. Wakhloo, M.D., Ph.D., Demetrius K. Lopes, M.D., Giuseppe Lanzino, M.D., Lee R. Guterman, Ph.D., M.D., and L. Nelson Hopkins, M.D., Delayed aneurysm regrowth and recanalization after Guglielmi detachable coil treatment, Journal of Neurosurgery,July 1998 / Vol. 89 / No. 1 / Pages 142-145
- 5.Motoharu Hayakawa, M.D., Yuichi Murayama, M.D., Gary R. Duckwiler, M.D., Y. Pierre Gobin, M.D., GuidoGuglielmi, M.D., and Fernando Viñuela, M.D., Natural history of the neck remnant of a cerebral aneurysm treated with the Guglielmi detachable coil system, Journal of Neurosurgery,October 2000 / Vol. 93 / No. 4 / Pages 561-568
6. Murayama Y, Viñuela F, Duckwiler GR, et al: Embolization of incidental cerebral aneurysms by using the Guglielmi detachable coil system. J Neurosurg 90:207–214, 1999
- 7.Kakarla UK, MaughanPH, Deshmukh VR, Spetzler RF., Giant,partially thrombosed aneurysm develops after remote angographically negative subarachnoid hemorrhage: case report ,Neurosurgery 2007Mar60(3):E572
- 8.S. Kobayashi, Neurosurgery of Complex Vascular Lesions and Tumors
- 9.T. Krings, H. Alvarez, P. Reinacher,A. Ozanne, C.E. Baccin, C. Gandolfo,W.-Y. Zhao, M.H.T. Reinges,and P. Lasjaunias, . Growth and Rupture Mechanism of Partially Thrombosed Aneurysms, Interv Neuroradiol. 2007 Jun; 13(2): 117–126.
10. H. Richard Winn, MD and H. Richard Winn, MD, Youmans Neurological Surgery, 6th Edition