

Osteoporotic vertebral fracture simulating a spinal tumor: a case report

Luis Rafael Moscote-Salazar¹, Gabriel Alcala-Cerra¹, Hernando Raphael Alvis-Miranda², Carlos Fernando Lozano-Tangua¹, Sandra Milena Castellar Leones, Maria Jose Merlano Almanza

Universidad de Cartagena, Colombia

¹Neurosurgeon; ²Physician

Abstract: Vertebral fractures are a frequent entity, mainly in the thoracolumbar and lumbar spine. In some circumstances the differential diagnosis of vertebral injuries can confuse the physician, since the difference between an osteoporotic vertebral fracture and a fracture secondary to a tumor is not clear. We report the case of a patient with osteoporotic vertebral fracture simulating a spinal tumor, handled by our department of neurosurgery as illustrative experience to guide the approach in those cases, in which the definitive diagnosis is crucial for therapeutic decision making.

Key words: Osteoporosis, spine, vertebral fracture.

Introduction

Vertebral fractures associated with osteoporosis are a common entity. (1) The consequences of this type of fragility fractures are diverse. Osteoporosis is estimated to affect 30-40% of all postmenopausal women and 50% of people over 76 years. (2) Occasionally, differentiate between an osteoporotic fracture and a tumoral lesion becomes a challenge. We report the case of a patient managed by the neurosurgical service of the University of Cartagena.

Case report

Female patient, 60 years old, with a history of arterial hypertension diagnosed 10 years ago, handled regularly with hydrochlorothiazide in a controlled manner. She consults to the emergency department because of thoracolumbar pain that started 2 month ago, and increased in intensity until difficulty the gait, associated with appearance of sacral skin ulcer as result of being bedridden for several days. She denies history of recent trauma.

Admission physical examination of head and neck was normal, cardiopulmonary and abdomen without alterations, symmetrical

limbs, skin ulcer in right sacral region with fetid serous discharge, pain on dorsolumbar movements, lower limbs flexion limited by pain, left Lassegue sign positive, Bragard, Patrick and Faber signs negative.

Neurologically conscious, oriented, no meningeal signs, sensitivity: not identified sensory level, proprioceptive function preserved (vibration and position) and estereoeceptive (touch, pain and temperature); muscular strength: 5/5 in the upper limbs, with bilateral paraparesis 4/5 on lower limbs; left antalgic gait of few steps because of exquisite pain, tendon reflexes: +/++++ symmetric, generalized; bilateral neutral plantar reflex; abdominal skin reflexes normal; digital rectal examination: eutonic sphincter, sphincter reflex present, preserved perianal sensitivity.

Laboratories on admission showed: leukocytosis with neutrophilia, increased acute phase reactants, normoglycemia, normal serum electrolytes, renal and hepatic profile unaltered, and normal coagulation tests. Dorsal and lumbar spine radiographies were performed showing T12 fracture.

The patient is evaluated by the neurosurgery service, which considered a spinal cord compression syndrome secondary to a T12 pathological fracture on study, it is considered to perform lumbar spine MRI, reporting change in the shape of the T12 vertebral body with collapse and mixed images infiltrating peri- and sub-dural space with medullary parenchymal commitment and compression, suggesting metastatic etiology.

Concomitantly is valued by internal medicine who establishes management for the infectious process with oxacillin and

ciprofloxacin, wound healing, antithrombotic therapy, proton pump inhibitors and general measures.

Likewise, general surgeries validates the patient, and consider to practice skin ulcer washing and sampling for culture, which reported *Acinetobacter baumani* sensitive to clindamycin and imipenem, so the antibiotic is rotated.

Medical board was performed for suspected metastatic lesion, which decides scheduled for surgery to open spinal biopsy, after resolution of the infectious process in the sacral bed sore. During surgery, are dissected the spinous apophysis and left sheets of T11-T12-L1; sheets looks gray-white unpolished. Ligament is dissected and T12 hemilaminectomy is performed with Kerrinson tweezers. Samples are taken for histology. Yellow ligament is repaired and cut with scalpel and Kerrinson tweezers.

Free nerve root and dural sac are identified, which are not imprisoned. It is observed T12 vertebral body destruction and partial absence of the same, with reduced height. Vertebral body samples were taken for histological study. Intervertebral discs had fibrosed aspect. Samples are taken from upper and lower disc and soft tissue. Compressive or infiltrative lesion is not apparent in the canal. Integrity of the root and dural sac is verified, with bipolar coagulation for hemostasis. Muscle is approximated with poliglactina 910, muscle fascia is sutured with poliglactina 910 continuous points. Subcutaneous fat is approximated with poliglactina 910 and skin with nylon 3/0 suture with continuous crossed points. Approximated bleeding volumen: 50 cc.

Pathology report is consistent with osteoporotic fracture, medical management for osteoporosis is started, and then is performed posterior thoracolumbar fusion. Postoperative course was satisfactory. Patient continues in outpatient control with neurosurgery and internal medicine.

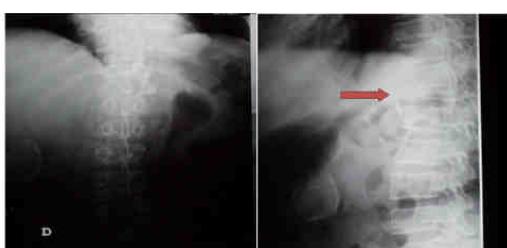


Figure 1 A, B - AP and lateral lumbar spine radiograph evidencing T12 fracture by crushing (see arrow)

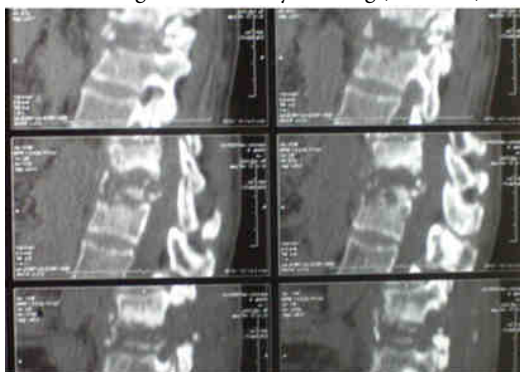

Figure 2 A, B - MRI of the thoracolumbar spine, sagittal reconstruction evidence vertebral collapse

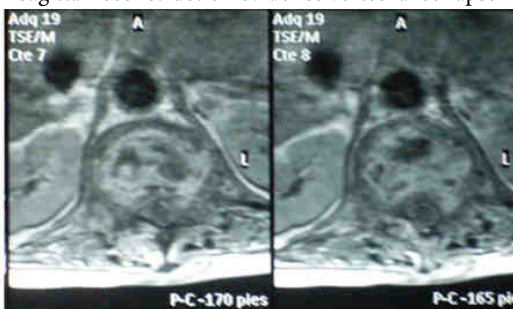


Figure 3 A, B - MRI of the thoracolumbar spine, sagittal cut evidencing vertebral body infiltration

Discussion

Some imaginological characteristics have been defined on MRI to help in the differentiating between osteoporotic and tumoral fractures.

a. In metastatic fracture often can be identified a convex edge in the posterior wall (74%). (2, 3)

b. In tumor fractures, the pedicles and posterior elements have abnormal signal intensity (85%). (4, 5)

c. Epidural lesions can be identified in pathological fractures (74%), the presence of paraspinal focal masses are not suggestive lesions to differentiate between osteoporotic from tumoral lesions.

Among injuries that must be taken in consideration is the plasmacytoma, this represents a subtype of B-cell lymphocytic tumor; it is located predominantly in the lumbar region and can cause pathological fractures; in these cases, often, is very difficult to define it preoperatively either by clinical features and / or imaging. (3, 6)

Common benign lesions are the hemangiomas, the edema of degenerative disease, osteoporotic fractures with edema and espondilodisquitis. Atypical hemangiomas and excessive edema due to degenerative problems may be a problem in the differential diagnosis of malignancy. Malign lesions are represented by malignant metastatic lesions, myeloma, malignant primary bone tumors and primary and secondary lymphoma. Myeloproliferative diseases can also be found, including leukemia. (7, 8)

Conclusion

This article shows that in patients with suspected tumoral fractures should be considered in the differential diagnosis the presence of osteoporotic fractures, sometimes the diagnosis becomes a neurosurgical challenge.

Correspondence

Luis Rafael Moscote Salazar

Universidad de Cartagena, Cartagena de Indias, Colombia

Email: mineurocirujano@aol.com

References

1. Camins M, Oppenheim J, Perrin R. Tumours of the vertebral axis: benign, primary malignant, and metastatic tumors. Youman's Neurol Surg. Philadelphia: Elsevier Saunders; 2011. p. 3131–67.
2. Cuénod CA, Laredo JD, Chevret S, Hamze B, Naouri JF, Chapaux X, et al. Acute vertebral collapse due to osteoporosis or malignancy: appearance on unenhanced and gadolinium-enhanced MR images. Radiology [Internet]. 1996 May [cited 2013 Nov 13];199(2):541–9. Available from: <http://www.ncbi.nlm.nih.gov/pubmed/8668809>
3. Tan SB, Kozak JA, Mawad ME. The limitations of magnetic resonance imaging in the diagnosis of pathologic vertebral fractures. Spine (Phila Pa 1976) [Internet]. 1991 Aug [cited 2013 Nov 13];16(8):919–23.

Available from:

<http://www.ncbi.nlm.nih.gov/pubmed/1948377>

4. Mubarak F, Akhtar W. Acute vertebral compression fracture: differentiation of malignant and benign causes by diffusion weighted magnetic resonance imaging. J Pak Med Assoc [Internet]. 2011 Jun [cited 2013 Nov 13];61(6):555–8. Available from:

<http://www.ncbi.nlm.nih.gov/pubmed/22204209>

5. Wonglaksanapimon S, Chawalparit O, Khumpunnip S, Tritrakarn S-O, Chiewvit P, Charnchaowanish P. Vertebral body compression fracture: discriminating benign from malignant causes by diffusion-weighted MR imaging and apparent diffusion coefficient value. J Med Assoc Thai [Internet]. 2012 Jan [cited 2013 Nov 13];95(1):81–7. Available from:

<http://www.ncbi.nlm.nih.gov/pubmed/22379746>

6. Shih TT, Huang KM, Li YW. Solitary vertebral collapse: distinction between benign and malignant causes using MR patterns. J Magn Reson Imaging [Internet]. 1999 May [cited 2013 Nov 13];9(5):635–42. Available from: <http://www.ncbi.nlm.nih.gov/pubmed/10331758>

7. Sugimura K, Yamasaki K, Kitagaki H, Tanaka Y, Kono M. Bone marrow diseases of the spine: differentiation with T1 and T2 relaxation times in MR imaging. Radiology [Internet]. 1987 Nov [cited 2013 Nov 13];165(2):541–4. Available from:

<http://www.ncbi.nlm.nih.gov/pubmed/3659380>

8. Baur-Melnyk A. Malignant versus benign vertebral collapse: are new imaging techniques useful? Cancer Imaging [Internet]. 2009 Jan [cited 2013 Nov 13];9 Spec No:S49–51. Available from:

<http://www.pubmedcentral.nih.gov/articlerender.fcgi?artid=2797458&tool=pmcentrez&rendertype=abstract>