

Extracranial internal carotid artery aneurysm treated by combined endovascular - microsurgical techniques

A. Chiriac, Georgiana Ion*, N. Dobrin*, I. Poata

“Gr. T. Popa” University of Medicine and Pharmacy, Iasi

*“Prof. Dr. N. Oblu” Clinic Emergency Hospital, Iasi

Abstract: Extracranial internal carotid artery aneurysms are rare lesions that still represent a challenge from diagnosis and treatment point of view. Giant complex aneurysms of extracranial internal carotid artery are usually completely excluded by surgical approaches. We present a case of a patient with an extracranial internal carotid artery aneurysm treated by a combined treatment, along with a short review of this pathology.

Key words: extracranial internal carotid artery aneurysms, combined treatment.

Introduction

Extracranial internal carotid artery aneurysms are very rare documented lesions. Even if the spontaneous rupture is uncommon manifestation, they can cause life threatening complications especially represented by thromboembolic. These vascular lesions are characterized by different etiologies, multiple neurological disturbances and varying diagnostic and therapeutic approaches. Open surgery is the first mode of treatment with satisfactory in long term. The endovascular approach is also a viable alternative especially when open access to the distal extent of the aneurysm is difficult. In this report we describe a case of giant extracranial carotid aneurysm with fulminant evolution treated by a combined endovascular and surgical technique.

Etiology and Epidemiology

Most common etiological factors for extracranial internal carotid artery aneurysms include congenital factors, trauma (pseudoaneurysms), athero-sclerosis, infective and fibromuscular dysplasia (3). In the recent studies there has been a change of the etiological profile of extracranial internal

carotid artery aneurysms with an increase incidence in atherosclerotic (42% to 70%) and dysplastic (20%) aneurysms and a decrease in infective and posttraumatic aneurysms [9].

Extracranial internal carotid artery aneurysm could be characterized like a dilation of ICA more than 50% of its normal diameter (0.55 ± 0.66 cm in male and 0.49 ± 0.07 cm in female) [8,9]. For the younger patients the common cause is represented by posttraumatic and infectious factors with possible associated diagnoses of tuberculosis, HIV or Takayasu arteritis. Salmonella and syphilis is known as main causes of so called mycotic aneurysms. In patients aged over 50 years, atherosclerosis is known as the main cause of these lesions, even if it serves for a secondary finding rather than a primary cause. Fibromuscular dysplasia, collagen tissue disorders and irradiation are among the rare etiologies.

In terms of location, they can be positioned proximal and distal to the Blaisdell line. The proximal types are usually fusiform involving the common carotid artery, the carotid bifurcation and the first part of internal carotid

artery. The distal are usually saccular in shape and located near the angle of the jaw [3].

Clinical Symptoms

The clinical symptoms of the patients with ECA aneurysms vary from asymptomatic neck mass or with aerodigestive tract compression, to neurological deficits and aneurysm rupture. The mass effect can cause direct compression of the vagus, hypoglossal or glossopharyngeal nerves or dysphagia due to pressure on pharyngeal constrictor muscles, pharyngeal dysfunction due to pressure on mucous membranes and ear pain radiating to occipital area. Horner's syndrome can be developed due to the affected cervical sympathetic nerves and hoarseness can be seen as a result of vagus nerve compression.

Most of the patients addresses on admission for painful pulsatile mass at neck region. However, some patients may develop transient ischemic attack or stroke due to a thrombotic or embolic event from the aneurysmal contents. Spontaneous rupture or bleeding are very rare but sometimes severe complication can be seen. Among the patients of published literature, 60% experienced transient ischemic attack (33% amaurosis, 21% hemispheric) or obvious stroke (8%) [9]. The risk of rupture was documented to be higher in mycotic carotid aneurysms whereas traumatic ones tend to stabilize and show regression in time.

Imaging diagnosis

Early diagnosis and anatomical characterization of these lesions are very important in terms of both endovascular and surgical treatments.

The diagnosis may be established by Doppler ultrasound which ensure determination of the size and extension of the aneurysm. Doppler examination is sufficient to characterize vascular and pulsatile structure of these lesions, but without being able to give

enough information concerning the thrombosed part and relation with its neighboring structures.

Conventional digital subtraction angiography remains the "gold standard" imaging investigation for the aneurysms diagnosis. Even so, it has the disadvantage of offering incomplete information, only about their patent lumen. Current angiographic explorations represented by Angio-CT and Angio-MRI provide a complete diagnostic imaging and highlighting information on the vascular lumen, thrombosed portions and existing calcifications.

Treatment

The treatment options are represented by surgical excision, endovascular interventions or conservative management. Surgery remains the gold standard and the different procedures consisted in simply ligation of the internal carotid artery and aneurysmal sac resection with wall reconstruction, end to end anastomosis, graft interposition of saphenous vein, PTFE or Dacron or ECA to ICA by-pass. The aim of surgery is to remove the risk of thromboembolic events or rupture of the aneurysm. The end to end anastomosis procedure is indicated in case of presence of artery tortuosity especially in elderly patients. The main risks of surgical interventions are represented by transient ischemic attacks (8%), cerebrovascular accidents (4–4.5%), cranial nerve injury (glossopharyngeal, vagus and hypoglossal, 20.8–44%) and death [0% in elective cases, 50% in emergency cases] [8].

The endovascular techniques are indicated especially in poor surgical candidates or who refuse surgery and consisted in ICA occlusion with detachable balloons, aneurysm coil embolization and stent graft reconstruction.

Case presentation

A 62-year old man was referred to our Neurosurgery Department with a two-week history of an enlarging right neck mass. The patient declares a cranio-cervical trauma in last month by accidental dropping with latero-cervical impact of a hard object.

The physical examination revealed a pulsatile semi-solid cervical mass located anterior to the sternocleidomastoid muscle (Figure 1). There was an associated pain and compressive symptoms with hoarseness, odynophagia or dysphagia for the last three days. He had no symptoms suggestive of cranial or peripheral neurologic deficits.

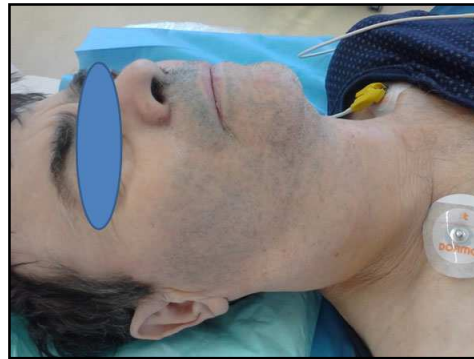
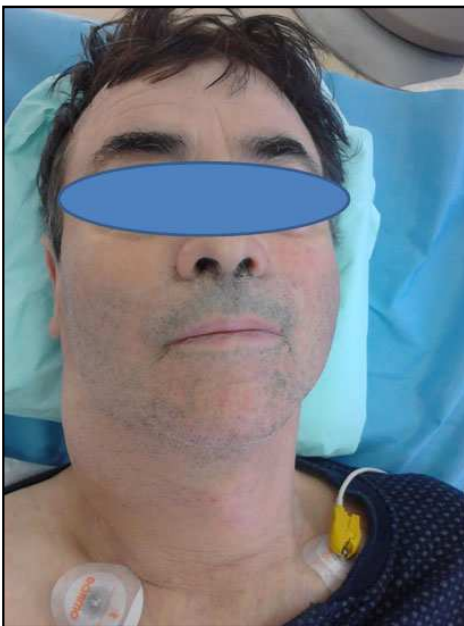
Figure 1 - Patient with latero-cervical mass



Imaging investigations started with an ultrasound Doppler performed at admission, which revealed the “mass” to be a giant aneurysm of the right internal carotid artery (ICA). The distal end of the internal carotid artery could not be highlight on ultrasound.

The digital subtraction angiography performed revealed a giant dysplastic aneurysm at the right common carotid artery bifurcation with atherosclerotic partially calcified walls.

The left common carotid artery bifurcation presents a partially calcified atherosclerotic plaque with extension in to internal carotid artery and without significant stenosis effect. Both vertebral arteries are patent and no evidence of atheroma.

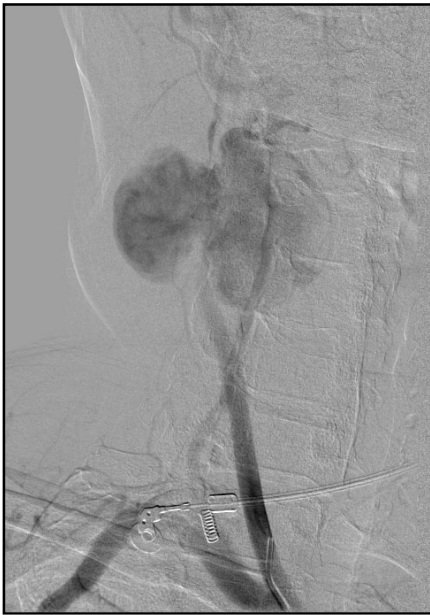

Figure 2 - DSA image of a giant right extracranial ICA aneurysm

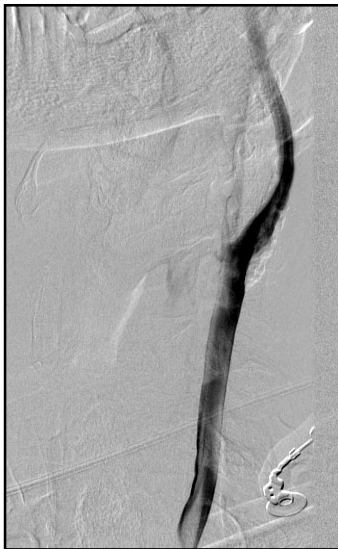
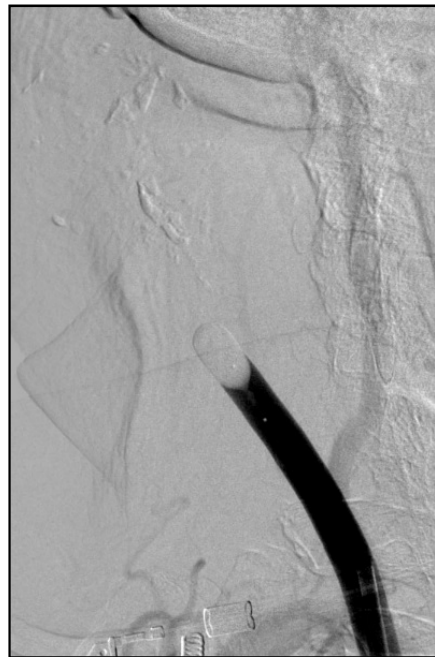
Figure 3 - DSA image of an athermatous left ICA bifurcation

by a combined approach, endovascular carotid occlusion and surgical aneurysm resection.

A temporary balloon occlusion testing under fluoroscopic guidance was performed for 10 minutes. The procedure showed a good arterial compensation of the right internal carotid artery territory by left internal carotid injection via anterior communicating artery. The right vertebral artery injection with right carotid temporary balloon occlusion showed a partial posterior communicating artery contrast filling (Figure 4).

After occlusion testing a permanent obstruction of the right common carotid artery was performed by placing two latex detachable balloons (Goldballoon 3) at the proximal part of the vessel (Figure 5).



After discussing the options with the vascular team we decided to treat the patient

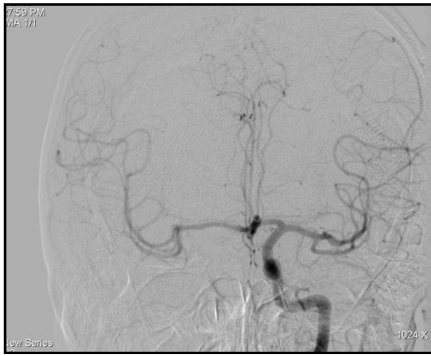

Figure 4 - DSA images showing right ICA test occlusion and good supplying of right ICA territory by left ICA injection

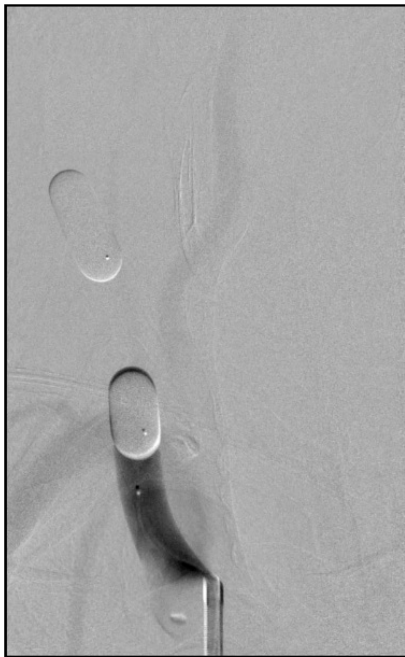


Figure 5 - DSA images showing right ICA occlusion with no contrast filling of the aneurysm

The next day the patient was referred to the vascular surgery clinic for complete resection of the aneurysm. The procedure was performed under general anesthesia continuously systemic anticoagulation. The lesion was achieved through a standard approach along the anterior

border of the sternocleidomastoid muscle. The aneurysm was exposed with carefully preservation of VII, X, XII cranial nerves. A total resection of the aneurysm was performed by vascular permanent clip placement above (ICA, ECA) and below (CCA) the lesion. The postoperative course was very good and the patient was discharged on post-operative day 5.

Conclusions

The possibility of an aneurysm at extracranial internal carotid artery should always be considered in patients with increasing volume mass in the neck. The good results obtained by both endovascular and surgical techniques are an important indicator for an urgent treatment in such patients with these particular vascular lesions.

Correspondence

Stefan M. Iencean

"Gr. T. Popa" University of Medicine and Pharmacy, Iasi

References

1. Ak, K., İsbir, S., Bayramiçli, M., Tekeli, A., Bozkurt, S., & Arsan, S. (2009). Aneurysm of extracranial internal carotid artery: A case report. <http://hdl.handle.net/11424/2199>.
2. Blanco, E., Serrano, F. J., Reina, R., Martín, A., Moñux, G., Ponce, A., & Morata, C. (2008). Saccular aneurysms of the extracranial internal carotid artery. Experience and review of the literature. *Journal of Cardiovascular Surgery*, 49(1), 73.
3. Castelli, P., Scamoni, C., Caronno, R., Piffaretti, G., Tozzi, M., Carnini, M., & Canziani, M. (2005). Giant aneurysm of the extracranial carotid artery: case report. *EJVES Extra*, 9(4), 84-86.
4. Kakisis, J. D., Giannakopoulos, T. G., Moulakakis, K., & Liapis, C. D. (2014). Extracranial internal carotid artery aneurysm. *Journal of vascular surgery*, 5(60), 1358.
5. Lim, Y. M., Lee, S. A., Kim, D. K., & Kim, G. E. (2002). Aneurysm of the extracranial internal carotid artery presenting as the syndrome of glossopharyngeal pain and syncope. *Journal of Neurology, Neurosurgery & Psychiatry*, 73(1), 87-88.
6. Perrin, J. M., Turowski, B., Steiger, H. J., & Hänggi, D. (2012). Double-barrel extracranial–intracranial bypass

surgery followed by endovascular carotid artery occlusion in a patient with an extracranial giant internal carotid artery aneurysm due to Ehlers–Danlos syndrome. *Journal of neurointerventional surgery*, neurintsurg-2012.

7. Robijn, S. M., Welleweerd, J. C., Lo, R. T., Moll, F. L., & de Borst, G. J. (2015). Treatment of an extracranial internal carotid artery aneurysm with a flow-diverting stent. *Journal of Vascular Surgery Cases*, 1(2), 191-193.

8. Smith M., Johnson P. (2013) Spontaneous extracranial internal carotid artery aneurysm. A case report. *WestIndianMedJ*2013;62(7):667.

9. Yetkin, U., Yürekli, İ., & Gürbüz, A. (2006). Extracranial internal carotid artery aneurysms. *Internet J Thorac Cardiovasc Surg*, 10(2).

10. Wu, J., Chen, Y., Qu, L., He, Y., Zhi, K., Bai, J., ... & Wu, Y. (2015). Using PTFE covered stent-artery anastomosis in a new hybrid operation for giant juxta-skull internal carotid aneurysm with tortuous internal carotid artery. *International journal of cardiology*, (185), 25-28.