

## Intraoperative contralateral extradural hematoma during evacuation of traumatic acute extradural hematoma

Anand Sharma<sup>1</sup>, Arti Sharma<sup>2</sup>, Yashbir Dewan<sup>1</sup>

<sup>1</sup>Artemis Health Institute, Gurgaon, India

<sup>2</sup>NSCB medical college, Jabalpur, India

**Abstract:** *Introduction:* Extradural hematomas (EDHs) accounts for approximately 2% of patients following head trauma and 5-15% of patients with fatal head injuries. When indicated, the standard surgical management consists of evacuation of the hematoma via craniotomy. Intraoperative development of acute extradural hematoma (AEDH) on the contralateral side following evacuation of acute extradural hematoma is uncommon and very few cases have been reported. *Case report:* We report a case of 28 year-old-male who suffered from a severe head injury following assault and diagnosed as acute extradural hematoma over right fronto-parietal region with midline shift towards left. Patient underwent emergency craniotomy with acute EDH evacuation. Following evacuation of acute EDH the duramater was tense which was unusual finding. With anticipation of underlying acute SDH small durotomy was done, but there were no subdural hematoma. Bone flap were repositioned and closure were done. Patient was shifted for NCCT head from OT, which revealed 2.7cm acute EDH over left frontoparietal region. Patient was again shifted back to OT and left frontoparietal craniotomy with evacuation of hematoma was done. Postoperative NCCT head was satisfactory. However, the patient remained severely disabled. *Conclusion:* Formation of contralateral EDH after AEDH surgery is a rare but potentially dangerous complication. A high degree of suspicion should be kept for contralateral extradural hematoma if during surgery there is tense duramater following AEDH evacuation. We would advise urgent NCCT head especially if a fracture is demonstrated on the preoperative CT scan on contralateral side. This would save some invaluable time, which may help in changing the outcome in some of the patients.

**Key words:** Traumatic acute extradural hematoma, skull fracture, Tense duramater, Head injury

### Introduction

Extradural hematomas (EDHs) accounts for approximately 2% of patients following head trauma and 5-15% of patients with fatal head injuries (8). An associated skull fracture is present in ~75% of cases. Intracranial acute

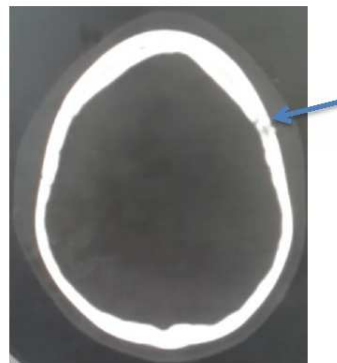
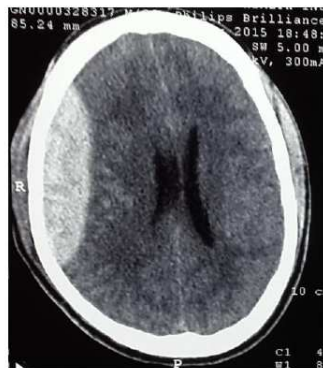epidural hematoma is considered to be the most serious complication of head injury, requiring immediate diagnosis and surgical intervention. When indicated, the standard surgical management consists of evacuation of the hematoma via craniotomy. Delayed

formation of extradural hematoma (EDH) on the contralateral side is a known entity (1) but intraoperative development of EDH on the contralateral side following evacuation of AEDH is uncommon. If unrecognized, this condition can cause devastating consequences. In this report, we presented our experience of a young male who developed a contralateral EDH during the removal of a traumatic acute extradural hematoma with short review of literature.

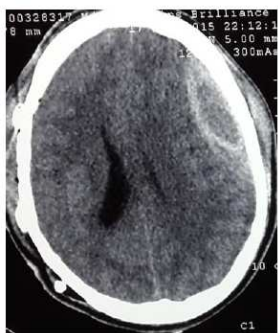**Case report**

A 28-year male suffered from a severe head injury following assault. He arrived after 6-hours of injury, on arrival at the emergency room; he was unconscious with labored breathing and a scalp hematoma over right frontoparietal area. His GCS was E1V1M2 with bilateral 5mm, nonreacting pupils. He was managed in emergency room with intubation, general care and antiepileptics. NCCT head revealed right fronto-parietal 2.6 cm acute

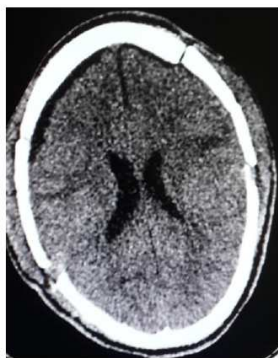EDH (Figure 1A, 1B) with left sided midline shift of 6mm with left temporal contusion. A right-sided craniotomy was immediately performed to evacuate the hematoma. Bleeding source was a tear in anterior branch of middle meningeal artery at the level of skull fracture. Following evacuation of acute EDH the duramater was tense which was unusual finding. With anticipation of underlying acute SDH small durotomy was done, but there were no hematoma. Bone flap were repositioned and closure were done. Patient was shifted for NCCT head from OT. His NCCT head revealed 2.7 cm acute EDH over left frontoparietal region (Figure 2); patient was again shifted back to OT and left frontoparietal craniotomy with evacuation of hematoma was done. Again bleeding source was a tear in anterior branch of middle meningeal artery at the level of skull fracture. Following evacuation duramater become lax. Postoperative NCCT head was satisfactory (Figure 3). However, the patient remained severely disabled.



**Figure 1 – A – NCCT head: right fronto-parietal acute extradural hematoma with midline shift towards left.  
 B – Bony window revealed linear fracture at left frontotemporal region**



**Figure 2** – Immediate postoperative NCCT head, revealed acute extradural hematoma over left frontoparietal region with midline shift towards right



**Figure 3** – NCCT head (Postoperative)

## Discussion

“Intraoperative hematoma”(9) is defined as a hematoma, not present on initial CT scan, but one that develops on the contralateral side during the process of evacuation of an acute traumatic hematoma. In contrast, “delayed epidural hematoma” (9) is any EDH developing after an initial CT scan had revealed no hematoma. However, delayed EDH can develop at any time after the initial CT scan, especially if the initial CT scan is done early (within first few hours following injury), our case represents a type of intraoperative extra dural hematoma.

Pathophysiology for development of intraoperative EDH is primarily related to rapid loss of tamponade effect on dura and

skull during a craniotomy (9, 5, 7) and the possible sources of bleeding include a ruptured meningeal arterial branch (tamponade because of edema, clot), venous lacerations, causing low tension bleeding, or a skull fracture. The possible cause of the EDH in our case could be due to rapid evacuation of the AEDH resulting in shifting of the brain towards the operated site with separation of the dura on opposite side. Evacuation of hematoma might have caused the loss of tamponade effect and bleeding from middle meningeal artery.

Intraoperative EDH manifests as tense duramater (6) (10) and after durotomy there is massive brain bulge from durotomy site due to severe brain shift. Other causes of massive brain bulge include acute cerebral vascular engorgement due to loss of cerebral vasomotor tone, intracerebral hematoma, expansion of other contusions in the same or opposite hemisphere and acute subdural hematoma (9, 5).

The diagnostic approach to possible contralateral intraoperative EDHs is challenging. Some authors have proposed intraoperative brain swelling, postoperative neurologic deterioration, papillary dilation contralateral to the operative side, seizures, and intractable raised intracranial pressure (ICP) as some indicator for the detection of such pathology (3). On presentation of these signs, immediate CT scan of the head and treatment of the cause is essential to the survival of the patient (9, 5, 3, 2). Mahindra et al recommends routine postoperative CT immediately after cranial surgery for head trauma, which would help in timely detection and treatment of such a complication (7). In our case we did immediate NCCT head after the surgery with immediate evacuation of contralateral hematoma.

A careful review of reported cases (9, 5, 3) of this disorder suggest that the outcome is better in those patients in whom the EDH was responsible for the worsening neurologic status rather than the underlying brain injury,

and in whom the recognition and treatment of the first and the contralateral hematoma was promptly undertaken. Patients with diffuse parenchymal injury and delay in treatment evidenced by poor neurologic status from the instant of trauma did poorly. Our report is compatible with this finding. However, we think that EDH evacuation still has potential value in improving the prognosis in these patients with severe head injury unless they have expressed the signs of brainstem failure. So we should evacuate the EDH promptly if it causes significant mass effect.

Our case represents a therapeutic challenge with development of contralateral acute extradural hematoma. A high degree of suspicion should be kept for contralateral extradural hematoma if during surgery there is tense duramater following AEDH evacuation. We would advise urgent NCCT head especially if a fracture is demonstrated on the preoperative CT scan on contralateral side. This would save some invaluable time, which may help in changing the outcome in some of the patients.

#### **Correspondence**

*Dr. Anand Sharma  
Mch Neurosurgery, Associate consultant,  
Neurosurgery, Artemis health sciences, Gurgaon,  
122003(India), Ph: +91-9873190047  
Email: dranandsharma100123@gmail.com*

#### **References**

1. Alappat JP, Baiju, Praveen, Jaya kumar K, Sanalkumar P. Delayed extradural hematoma : a case report. *Neurol India* 2002; 50:313-5.
2. Borovich B, Braun J, Guilburd JN, Zaaroor M, Michich M, Levy L, Lemberger A, Grushkiewicz I, Feinsod M. Delayed onset of traumatic extradural hematoma. *J Neurosurg.* 1985;63:30-4.
3. Borah N, Dutta D, Baishya BK, Hussain Z. Contralateral extradural hematoma formation following evacuation of chronic subdural hematoma- A case report and review of literature. *Indian Journal of Neurotrauma.* 2015;1-3.
4. Eftekhari B, Ketabchi E, Ghodsi M, Esmaeli B. Bilateral asynchronous acute epidural hematoma: a case report. *BMC Emerg Med.* 2003 Dec 30;3(1):1.
5. Feuerman T, Wackym PA, Gade GF, Lanman T, Becker D. Intraoperative development of contralateral epidural hematoma during evacuation of traumatic extraaxial hematoma. *Neurosurgery* 1988; 23: 480-4.
6. Matsuno A, Katayama H, Wada H, et al. Significance of consecutive bilateral surgeries for patients with acute subdural hematoma who develop contralateral acute epi- or subdural hematoma. *Surg Neurol* 2003; 60:23-30.
7. Mohindra S, Mukherjee KK, Gupta R, et al. Decompressive surgery for acute subdural haematoma leading to contralateral extradural haematoma: a report of two cases and review of literature. *Br J Neurosurg* 2005;19:490-4.
8. Rajput DK, Kamboj R, Srivastav AK, Kaval P, Kumar R. Is management of spontaneous intracranial extradural hematoma in chronic renal failure is different with traumatic extradural hematoma - Case report and review of literature: *Indian Journal of Neurotrauma.* 2010; 7:81-84.
9. Singh M, Ahmad F U, Mahapatra AK. Intraoperative development of contralateral extradural hematoma during evacuation of traumatic acute subdural hematoma: A rare cause of malignant brain bulge during surgery. *Indian journal of Neurotrauma* 2005; 2:139-140.
10. Wani AA, Dhar A, Laherwal M, Ramzan AU, Malik NK, Nizami FA, Wani MA. Bilateral sequential developed asynchronous extradural haematomas. *Indian Journal of Neurotrauma* 2010,7,79-80.