

## Non traumatic fractures of the lumbar spine and seizures: case report

Luis Rafael Moscote-Salazar<sup>1</sup>, Andres M. Rubiano<sup>2</sup>,  
Hernando Raphael Alvis-Miranda<sup>3</sup>, Gabriel Alcala-Cerra<sup>1</sup>

<sup>1</sup>Neurosurgeon, Universidad de Cartagena, CISNEURO Research Group-Colombia

<sup>2</sup>Neurosurgeon, Universidad El Bosque, Bogota, Colombia

<sup>3</sup>Resident of Neurosurgery, Universidad de Cartagena, CISNEURO Research Group-Colombia

**Abstract:** Injury-induced seizures may appear clinically asymptomatic and can be easily monitored by the absence of trauma and post-ictal impairment of consciousness. Patients with epilepsy have a higher risk of compression fractures, leading to serious musculoskeletal injuries, this type of non-traumatic compression fractures of the spine secondary to seizures are rare lesions, and is produced by the severe contraction of the paraspinal muscles that can achieve the thoracic spine fracture. Seizures induced lesions may appear clinically asymptomatic and can be easily monitored by the absence of trauma and post-ictal impairment of consciousness. We present a case report.

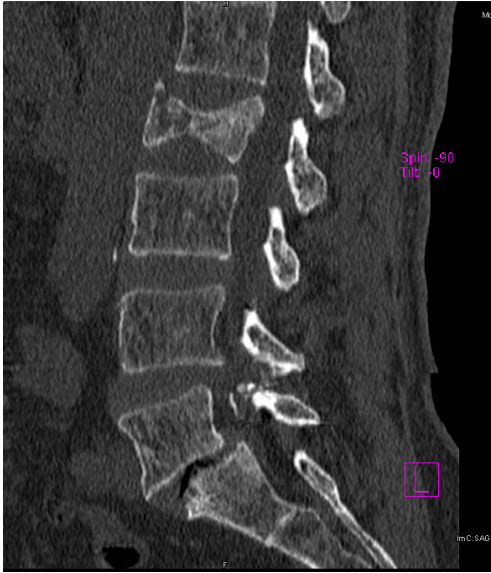
**Key words:** Injury-induced seizures, spine fractures

### Introduction

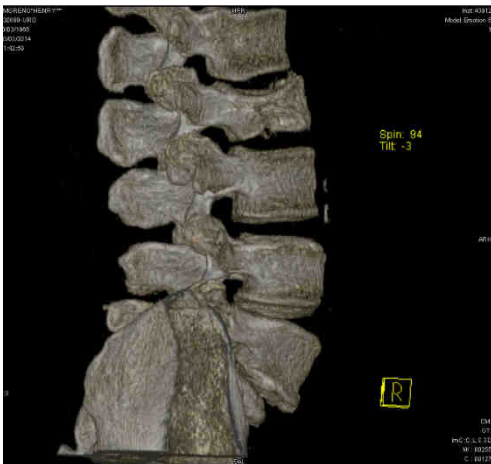The spine may present a risk of fracture during seizures. Basically two factors may increase the risk, first, frequent crises and second, altered bone metabolism by anticonvulsant drugs. We report here a case of this rare condition. This type of non-traumatic compression fractures of the spine secondary to seizures are unusual lesions and are generated by a severe contraction of the paravertebral muscles that can achieve spinal fracture in different segments. These lesions may be asymptomatic in the absence of trauma.

### Case report

Male 46 years old with a history of seizures and back pain of two days, was referred to our neurosurgery department. On admission blood pressure was 140/80, heart rate 100/min and oxygen saturation 95%. Past medical history neither an even of fall nor an accident. At presentation the neurological examination of upper and lower limbs was normal. He complained of pain in the lumbar area. Lumbar spine CT revealed L2 fracture. (Figure 1 and 2). The patient was treated with posterior fusion. 3 months after at the latest follow up visit, the patient had no problem and returned to his previous activity.



**Figure 1** - CT scan of lumbar spine showed a fracture of L2



**Figure 2** - Three-dimensional CT reconstruction of L2 fracture

## Discussion

It is usual that forces generated during a seizure can cause severe pain and walking impairment, basically due to the repeated contraction, relaxation and trembling of one

or more muscles abruptly, being violent forces generated during seizure activity. (3, 4)

It is recognized that forces generated during tonic-clonic seizure can cause axial skeletal trauma, including thoracic and lumbar fractures. Clinical signs of unstable fractures can be subtle.

Manifestations can be similar to those exhibiting stable fractures with anterior edge depression, affecting only the anterior column, leaving intact the middle and posterior column. These fractures are termed wedge fractures. This type of fracture occurs when there is comminution of the posterior part of the vertebral body plus subluxations or dislocations associated with the interapophyseal joints. These are referred to as comminuted fractures. They can also split the spinal fractures with or without neurological injury irrespective of stability or instability. Trauma to the spine especially fractures present with pain, functional disability, deformation, increased volume, bruising and crepitus in some cases associated with fracture of the vertebral body may be associated with damage to the posterior arch. A high index of clinical suspicion is guaranteed to patients suffering from tonic-clonic seizures with associated risk factors. (4)

Vigorous muscle contractions during a seizure can result in vertebral compression fracture, especially in the middle thoracic region, the production mechanism of spinal fractures is hyperextension. A complaint of back pain after isoniazid -induced seizures in patients raises a strong suspicion of vertebral fracture and should be evaluated radiologically. (7) Despite the relative

frequency of vertebral compression fractures as a complication of seizures, burst fractures are rare.

Health professionals who care for patients in postictal state should maintain a high index of suspicion for secondary injury and a detailed clinical examination. If there is any doubt about the diagnosis, appropriate imaging should be employed. (5) Patients with epilepsy taking antiepileptic drugs tend to have an increased risk of fractures. (6)

Vestergaard et al., in their meta-analysis studied the effects of epilepsy in the risk of fractures and changes in bone mineral density (BMD) in patients with epilepsy. A weighted estimate of the relative risk of fractures and changes in BMD (Z-score) was calculated. A total of 11 studies on the risk of fracture and 12 studies on BMD were recovered. The relative risk of any fracture increased (2.2, 95% CI 1.9 to 2.5, five studies), and spine fractures (6.2, 2.5 to 15.5, three studies). A high proportion of fractures (35%) seemed related to seizures. Spine (mean +/- SEM: -0.38 +/- 0.06) and hip (-0.56 +/- 0.06) BMD Z -score was significantly reduced hip over the spine (2P <0.05). Projected increases in the relative risk of any fracture BMD Z scores were 1.2 to 1.3, and significantly lower than that observed (2P < 0.05). The deficit in BMD in patients with epilepsy is too small to explain the observed increase in fracture risk. The remaining increase in the risk of fracture may be associated with seizures. (8)

Diagnosis is made by a good history (if possible), neurological examination together with clinical manifestations ranging from a totally asymptomatic patient to tetraplegia,

lesions to the cervical plexus, brachial, partial or complete spinal cord injury. Hence the importance of evaluating the mechanism of injury and the status of the same order to progress in clinical diagnosis, determine the degree of neurological compromise, instability, and determine proper handling.

Imaging resources combined with the clinical findings confirm the diagnosis. The former include the simple Rx as a timely measure of first instance, CT, MRI, according to the patient's needs and myelography as the last option to discard movements that compress the spinal cord.

## Conclusions

Column fractures secondary to a seizure are rare entities; however in the context of the forces generated violently during neuronal hyperexcitability motor reactions generated contractility and overextension. Clinical and neurosurgeon should be aware of the possibility of skeletal muscle damage after a seizure.

## Correspondence

*Luis Rafael Moscote-Salazar*

*Universidad de Cartagena, Cartagena de Indias, Colombia*

*E-mail: mineurocirujano@aol.com*

## References

1. Mehlhorn AT, Strohm PC, Hausschildt O, Schmal H, Südkamp NP. Seizure-induced muscle force can cause lumbar spine fracture. *Acta Chir Orthop Traumatol Cech [Internet]*. 2007 Jun [cited 2014 Apr 25];74(3):202-5.
2. Gnanalingham K, Macanovic M, Joshi S, Afshar F, Yeh J. Non-traumatic compression fractures of the thoracic spine following a seizure -- treatment by percutaneous

- kyphoplasty. *Minim Invasive Neurosurg* [Internet]. 2004 Aug [cited 2014 Apr 24];47(4):256–7.
3. Harrison *Principios de Medicina Interna. Convulsiones y epilepsia en español*. 16a edición. Cap. 363. Harrison online en español. McGraw-Hill. 2006
4. Youssef JA, McCullen GM, Brown CC. Seizure-induced lumbar burst fracture. *Spine (Phila Pa 1976)* [Internet]. 1995 Jun 1 [cited 2014 Apr 25];20(11):1301–3.
5. Napier RJ, Nolan PC. Diagnosis of vertebral fractures in post-ictal patients. *Emerg Med J* [Internet]. 2011 Feb [cited 2014 Apr 24];28(2):169–70. Available from: <http://www.ncbi.nlm.nih.gov/pubmed/20935331>
6. Shiek Ahmad B, Hill KD, O'Brien TJ, Gorelik A, Habib N, Wark JD. Falls and fractures in patients chronically treated with antiepileptic drugs. *Neurology* [Internet]. 2012 Jul 10 [cited 2014 Apr 16];79(2):145–51.
7. Kalaci A, Duru M, Karazincir S, Sevinç TT, Kuvandik G, Balci A. Thoracic spine compression fracture during isoniazid-induced seizures: case report. *Pediatr Emerg Care* [Internet]. 2008 Dec [cited 2014 Apr 25];24(12):842–4.
8. Vestergaard P. Epilepsy, osteoporosis and fracture risk - a meta-analysis. *Acta Neurol Scand* [Internet]. 2005 Nov [cited 2014 Apr 25];112(5):277–86.