

Multimodality treatment of brain arteriovenous malformation. Case report

Georgiana Ion¹, A. Chiriac, N. Dobrin¹, I. Poeată

“Grigore T. Popa” University of Medicine and Pharmacy, Iasi, Romania

¹“Prof. Dr. N. Oblu” Clinic Emergency Hospital, Iasi, Romania

Introduction

Brain arteriovenous malformations (AVMs) are abnormal shuntings between arteries and veins that bypasses normal brain tissue. The vascular conglomerate is called the nidus. Frequency range between 0,89%-1,24% per 100.000 person-year, most commonly in young adults. Only 12% of the AVMs are estimated to become symptomatic through hemorrhage, seizures, progressive neurological deficit, headache and migraine. A multifactorial etiology is suspected and Spetzler — Martin grading system is the reference scale. Regarding the treatment options we mention: microsurgery, endovascular embolization and radiosurgery.

We report our experience in a case of an unruptured AVM treated initially endovascular and then microsurgical resected.

Case presentation

This is a case of a 36 years old female known with moderate headache, preceded by left homonymous hemianopsia onset 8 years ago, symptomatology that it was repeated weekly during two years. In the last year episodes had become less frequent and

headache was associated with complex visual disturbances. Patient shows no associated pathologies. She was taken to a local hospital where it was investigated by cerebral MRI.

The MRI scan demonstrated an unruptured right occipital arteriovenous malformation, Spetzler II.

At the time of her admission in our hospital, she was neurologically normal, only with mild headache and rare phosphenes. To study AVM angioarchitecture the exploration was completed with Seldinger angiography. It was demonstrated an AVM in the right temporo-occipital region with two pedicles from middle cerebral artery (M3) and another two pedicles from right posterior cerebral artery, segment P2, with a large draining vein into inferior anastomotic vein (Labbe). In order to facilitate surgical resection it was decided that initially to achieve occlusion of the AVM via an endovascular route. A multifunctional team is necessary in these cases, a team of neurosurgeons and an endovascular team.

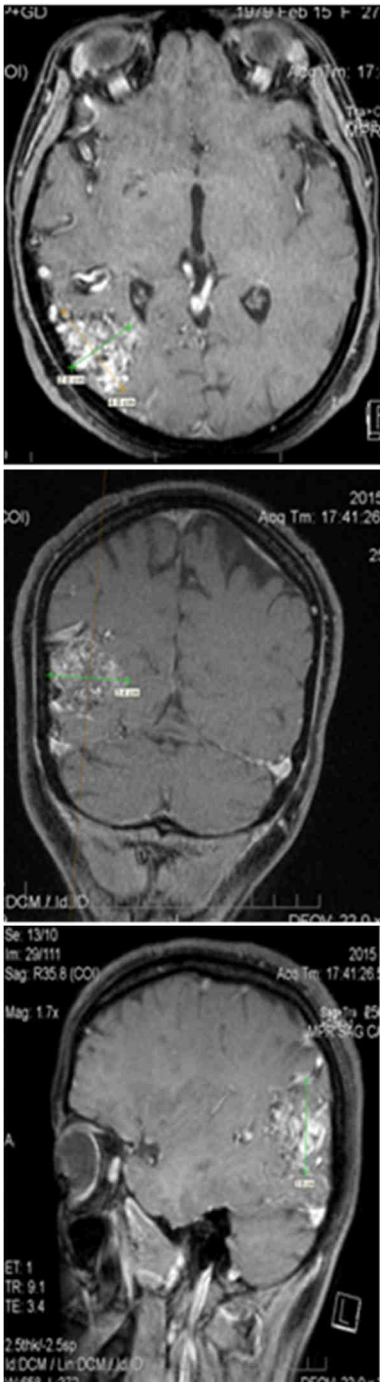


Figure 1 - MRI scan, T1 with contrast image

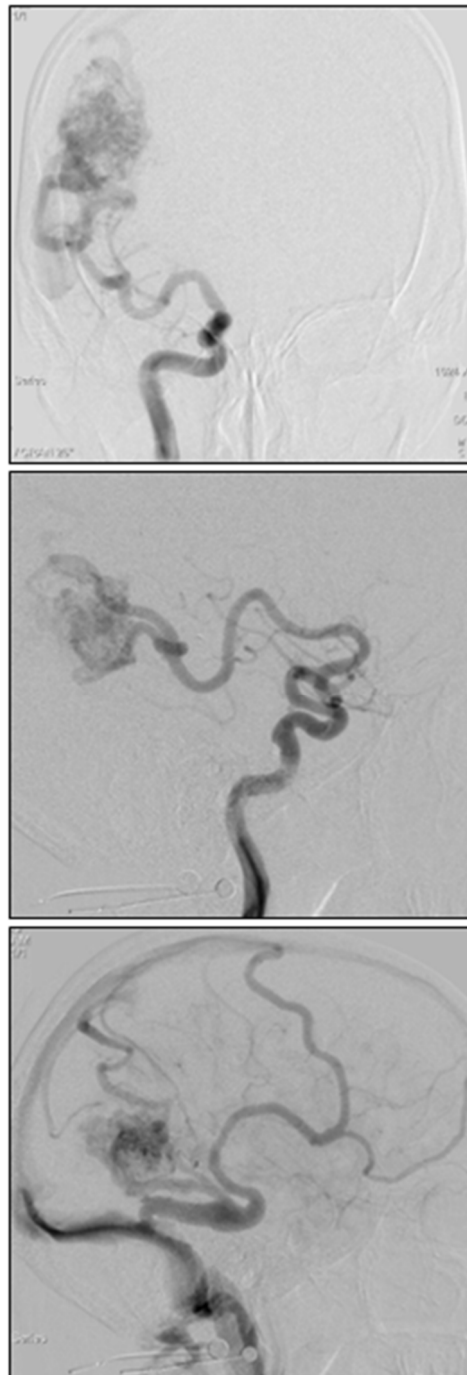


Figure 2 - DSA A, B right MCA, C venous drainage into Labbe vein

Embolization

After one month the patient was admitted for the treatment. Preoperative embolization was performed in the same day with the surgical resection.

It was practiced right 6 French femoral approach with selective catheterization of the left vertebral artery. It was distinguished the two feeding pedicles from the right posterior cerebral artery, P2 segment. Next it was achieved the micro catheterization of the P2 segment with a microghid supported microcatheter near the origin of the two pedicle. For the safety of the procedure, catheter was positioned perinidal and the embolization substance was injected controlled. The following step was represented by injection of 5% glucose solution and then 1,5 ml of Glubran 2 mixed with contrast substance was injected under subtracted fluoroscopy. The microcatheter was withdrawn fast after injection once reflux occurred. The control angiography demonstrated complete occlusion of the two pedicles.

Surgical technique

A temporo -parietal -occipital flap of about 7/8 cm was performed. The dura was opened in a "U" shape taking care not to damage the adherent superficial draining veins and is cut with an anterior pedicle, next is observed the venous drainage of the AVM that is at the brain surface. Nidus tension level is high and decreases more after pedicles dissection and clipping. However, nidus circumferential dissection reveals many small pedicle, intense bleeding, up to the ventricle, that is opened for 1 cm. Can be observed a racemic area at the

level of occipital cortex and also in white matter. Voluminous pedicles from middle cerebral artery have diameter of about 5-6mm and at the attempt to ligation prove to be friable for which reason are used 3 Yasargil titanium clips. After all the feeders were interrupted, the nonarterialized draining vein has been disconnected. Nidal tissue is removed for histopathological examination. After a good hemostasis was achieved, the walls were coated with gelaspon.

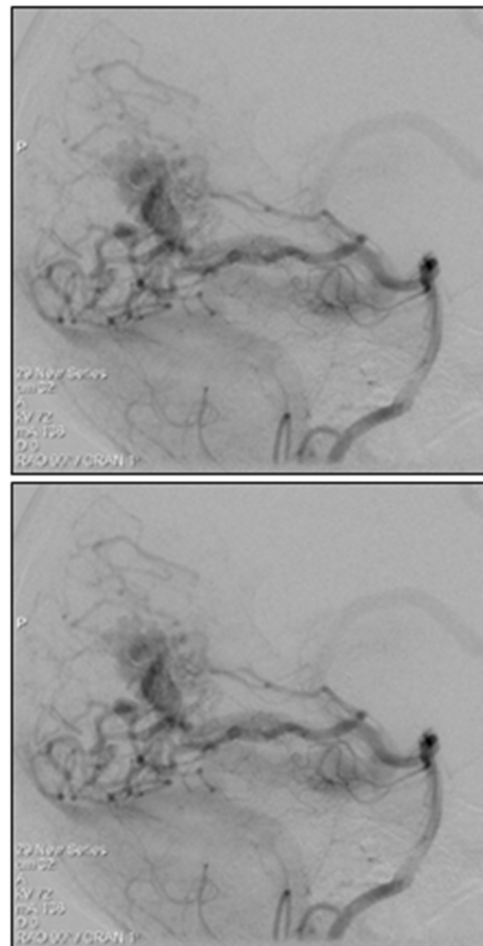


Figure 3 - DSA Pedicles from right PCA

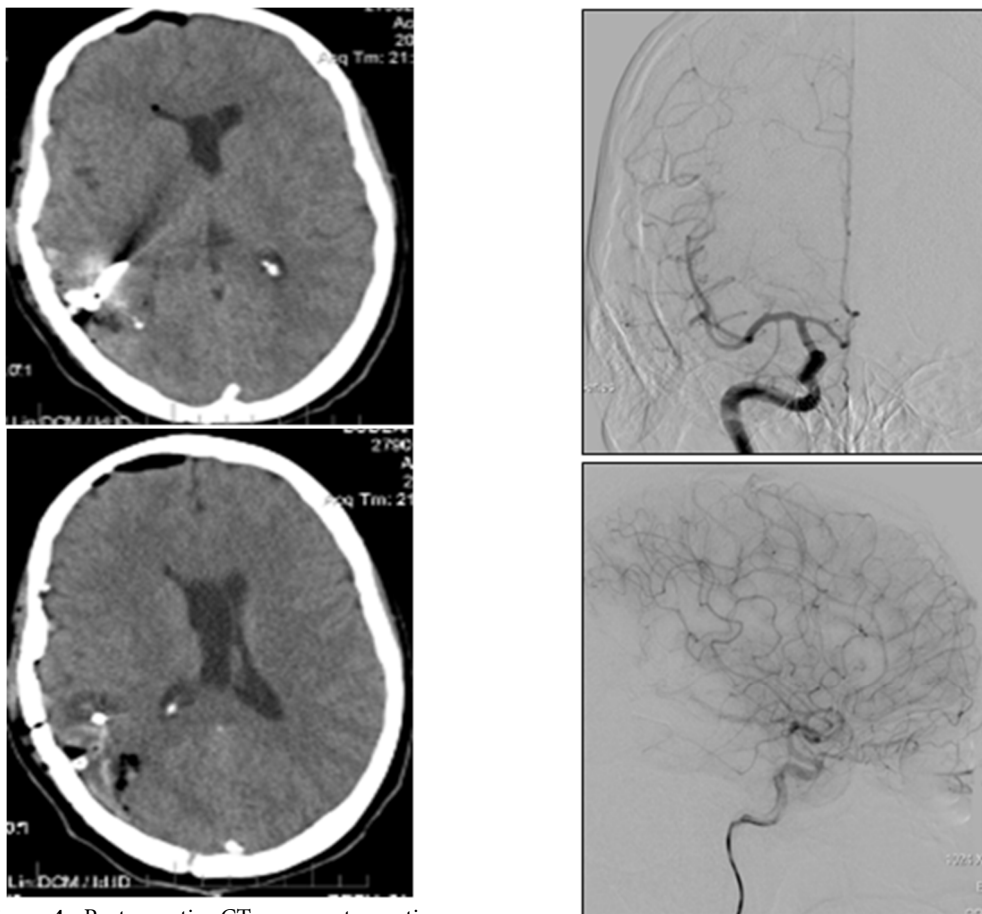


Figure 4 - Postoperative CT scan, postoperative aspects, titanium clips

Postoperative Course

Postoperatively, the patient retained rare episodes of headache, with no visual disturbances and it was followed periodically by CT scans. It returned to our institution, for evaluation after two months, when it was performed an angiographic study. Have been verified angiographically both vertebral arteries and right carotid artery and there was no remaining AVM noted except for a small vascular pedicle only observed during arterial phase.

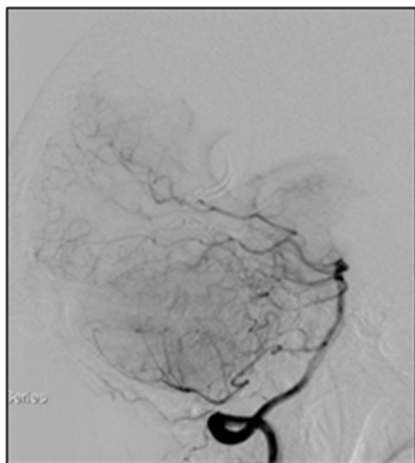


Figure 5 – A, B two month follow-up DSA- right ICA, C, D vertebral artery DSA-a small arterial pedicle with no venous drainage

Discussion

The most important question concerning the treatment of an AVM is which is the best option or options, in what order and in what time period with the lowest rate of complications. Many studies were made in order to determine the natural history of the AVMs.

The annual hemorrhage risk varies between 0,9% in cases with unruptured, superficial drainage or superficially located AVMs and 34% in cases with deeply seated brain AVMs ,deep venous drainage and those ruptured. Symptomatology is represented by seizures in 25%-50% of the cases, most of them being represented by simple or partial complex seizure. The mechanism is assumed to be the cortical irritation, gliosis, ischemia due to hemodynamic alteration or the mass effect. Factors associated with seizure were evaluated in numerous studies and are represented by location and the angioarchitecture of the

AVM, like cortical location, absence of the aneurysms and more draining veins. Regarding the seizure outcome some authors found no differences in seizure control after AVM treatment regardless the method.

Regarding the treatment of the AVMs is well known that grades I and II best options are microsurgery or stereotactic radiosurgery while in grades IV and V the most effective treatment method is still under study because of high morbidity and mortality rates. Grade III AVMs are subdivided into IIIA if they are large and IIIB if are in eloquent area or have a deep venous drainage. In this cases are recommended endovascular treatment followed by surgical resection for IIIA type and radiosurgery with or without embolization in type IIIB.

According to recent meta-analysis complications rates, like intracranial hemorrhage are 1,7% after endovascular treatment and 0,18% after microsurgery, in a smaller percentage in male population, small AVM and those with deep venous drainage. Concerning successful obliteration of the AVM (angiographic obliteration), large studies conclude that after microsurgery was achieved in 96% of the cases, 13% (0%-94%) after embolization and 38% after radiosurgery.

Microsurgery treatment is safe and effective after embolization Glubran 2, a cyanoacrylate-based synthetic glue modified by the addition of a monomer, with satisfying occlusion rates and low complications. However, maneuvering with Gluebrant requires experience because the material polymerizes very quickly and the

microcatheter may remain stuck to the vascular wall.

Because complete surgical resection is difficult to assess, postoperative angiographic evaluation is necessary to exclude any residual AVM, or to ensure a regrowth of an AVM (well documented in children).

It is interesting to assess the benefit of preoperative embolization in AVM pathology, and in this sense there are few studies. Some concludes that preoperative endovascular treatment convert these lesions of a higher grade into in some easier for resection. First debate is related to the agent used for closing the arterial pedicle, Gluebran or Onyx (ethylene vinyl alcohol copolymer dissolved in DMSO-dimethyl sulfoxide). Onyx polymerizes slowly, is less adhesive and an extended intranidal injection is possible, compared to Gluebran except the cases with feeders in passage or a plexiform nidus. Some authors found a complete obliteration in 16% of the cases and a size reduction in 75% of the cases, after using Onyx.

Second, what are the benefits of preoperative embolization? Some studies suggests that blood loss is reduced, the same as the operative time. Others have concluded that after embolization, hemodynamics changed, fact that made it more difficult for resection, on the other hand, vessels with glue differentiate better from the ones which irrigate normal parenchyma.

In definitive, it greatly matter the existence of a complete teams within the same hospital that has significant experience in this pathology.

Conclusion

Brain AVM treatment is associated with incomplete efficacy and a moderate risk. Decision-making process should be made by a team by taking into account a number of factors related to each individual patient, the AVMs angioarchitecture and all the risks included, specific to each procedure and, not the least, considering the center experience in this pathology. Life expectancy, occupation and lifestyle of the patient must be considered when treating this pathology.

Preoperative embolization is necessary in order to make the surgical resection easier by reducing the blood flow or by closing some deeper feeding arteries that are not accessible to the surgeon.

Correspondence

Dr. A. Chiriac

References

1. Janneke van Beijnum, H. Bart van der Worp, Dennis R. Buis, Rustam Al-Shahi Salman, L. Jaap Kappelle, Gabriël J. E. Rinkel, MD; Jan Willem Berkelbach van der Sprenkel, W. Peter Vandertop, Ale Algra, Catharina J. M. Klijn (2011) Treatment of Brain Arteriovenous Malformations A Systematic Review and Meta-analysis JAMA, 306(18):2011-2019.
2. Hoh, B. L., Chapman, P. H., Loeffler, J. S., Carter, B. S., & Ogilvy, C. S. (2002). Results of multimodality treatment for 141 patients with brain arteriovenous malformations and seizures: factors associated with seizure incidence and seizure outcomes. *Neurosurgery*, 51(2), 303-311.
3. Natarajan, S. K., Ghodke, B., Britz, G. W., Born, D. E., & Sekhar, L. N. (2008). MULTIMODALITY TREATMENT OF BRAIN ARTERIOVENOUS MALFORMATIONS WITH MICROSURGERY AFTER EMBOLIZATION WITH ONYX: SINGLE-CENTER EXPERIENCE AND TECHNICAL NUANCES. *Neurosurgery*, 62(6), 1213-1226.

4. Han, P. P., Ponce, F. A., & Spetzler, R. F. (2003). Intention-to-treat analysis of Spetzler-Martin grades IV and V arteriovenous malformations: natural history and treatment paradigm. *Journal of neurosurgery*, 98(1), 3-7.
5. Sasaki, T., Kurita, H., Saito, I., Kawamoto, S., Nemoto, S., Terahara, A., ... & Takakura, K. (1998). Arteriovenous malformations in the basal ganglia and thalamus: management and results in 101 cases. *Journal of neurosurgery*, 88(2), 285-292.
6. Robert F. Spetzler, M. Yashar S. Kalani, Peter Nakaji (2015) *Neurovascular Surgery*, 2nd edition;
7. Gabriel, E. M., Sampson, J. H., & Wilkins, R. H. (1996). Recurrence of a cerebral arteriovenous malformation after surgical excision: case report. *Journal of neurosurgery*, 84(5), 879-882.
8. Liu, J., Lv, M., Lv, X., He, H., Liu, A., Qian, Z., & Li, Y. (2014). Curative Glubran 2 Embolization of Cerebral Arteriovenous Malformations Patient Selection and Initial Results. *Interventional Neuroradiology*, 20(6), 722-728.
9. Jafar, J. J., Davis, A. J., Berenstein, A., Choi, I. S., & Kupersmith, M. J. (1993). The effect of embolization with N-butyl cyanoacrylate prior to surgical resection of cerebral arteriovenous malformations. *Journal of neurosurgery*, 78(1), 60-69.
10. Nataraj, A., Mohamed, M. B., Gholkar, A., Vivar, R., Watkins, L., Aspoas, R., ... & Mendelow, A. D. (2014). Multimodality treatment of cerebral arteriovenous malformations. *World neurosurgery*, 82(1), 149-159.
11. Van Rooij, W. J., Sluzewski, M., & Beute, G. N. (2007). Brain AVM embolization with Onyx. *American Journal of Neuroradiology*, 28(1), 172-177.