

Intracranial arachnoid cyst: an institutional experience

Mukesh Sharma, R.S. Mittal, Rajeev Bansal, Achal Sharma

Department of Neurosurgery, S.M.S. Medical College and Hospitals Jaipur Rajasthan (India)

Abstract: *Aim:* In this study, symptoms at presentation, indication for surgery, surgical treatment modalities, postoperative results and complications were studied. *Material and methods:* We retrospectively compiled the details of patients with IAC from admission and operative records admitted through our OPD during the period between January 1995 and January 2015. Only those patients were admitted whose symptoms attributes to the cyst and asymptomatic patients were followed on OPD basis. This is a single institutional study. *Results:* This study includes 56 patients of IAC who were operated. Posterior fossa cysts (62.5%) were found more commonly symptomatic. Headache (32%) was the most common symptom in a patient with IAC. Out of all, 24 patients presented with headache and underwent surgery subsequently; 20 showed satisfactory relief after surgery while four showed partial relief. Size of cyst was significantly reduced after surgery in 52 patients after 12 weeks but four patients, who underwent cystoperitoneal shunt, required re-operation as patients showed no decrease in size of cyst due to shunt malfunction. Head circumference was reduced following intervention in infant patients. Three patients who presented with visual field defects with IAC in sellar region showed improvement after endoscopic fenestration of cyst. One of the patient with cerebellopontine angle arachnoid was died immediately after marsupialization due to unexplained bleeding. *Conclusions:* IAC is not an uncommon finding on imaging but only few are symptomatic. Patients with Intracranial arachnoid cyst should be treated only if the patient's symptoms are attributable to the cyst.

Key words: Intracranial Arachnoid cysts, cerebellopontine angle, neuroendoscopy, cystoperitoneal

Introduction

Intracranial Arachnoid cysts (IAC) are benign cystic lesions containing cerebrospinal fluid (CSF) like material and are enclosed in arachnoid like membrane. The origin of arachnoid cyst is probably developmental in

origin and these lesions become symptomatic either due to their progressive enlargement or due to haemorrhage into the cyst.

With the increasing use of MRI and CT, there has been a corresponding increase in the number of incidentally diagnosed arachnoid cysts.

As per study done by Wajid N. Al-Holou et al, the prevalence of arachnoid cyst in children was found to be 2.6 percent and in adults 1.4 percent. (1, 2) Our study is a retrospective study and reports our experience with 56 patients of IAC who underwent surgery.

As patients of IAC can be symptomatic or asymptomatic, asymptomatic patients are followed while symptomatic ones are evaluated so that it can be assured whether the symptoms are related with the cyst. As for instance delayed milestones, headache and hydrocephalus in children can be due to multiple others reasons also. So children were evaluated and investigated accordingly prior to surgery. For each patient we collected information regarding age, sex, symptoms at presentation, indication for imaging, location of intracranial arachnoid cyst and treatment modality used and outcome of patients. IAC were considered symptomatic only if the patient's symptoms are attributable to the cyst and only symptomatic patients were treated either by craniotomy, endoscopic or cystoperitoneal shunting.

Material and methods

We retrospectively compiled the details of patients with IAC from admission and operative records admitted through our OPD during the period between January 1995 and January 2015. A detailed history of all patients of IAC who attended OPD whether newly registered or referred from other specialities taken. Only those patients were admitted whose symptoms attributes to the cyst and asymptomatic patients were followed on OPD basis. Symptomatic cysts were operated. Data was collected for Age, Sex, Symptoms,

Location, and type of surgery. The follow-up period was 12 weeks. The aim of our study was to evaluate the symptoms at presentation, location of the IAC, indications for surgery, surgical treatment modalities, postoperative results and postoperative complications. This is a single institutional study.

Results

This study includes 56 patients of IAC who were operated during the period between January 1995 and January 2015. Out of 56, seventeen (30.36%) were adult males, 12(21.43%) adult females, 16(28.57%) males<18years of age and 11(19.64%) females<18 years of age. Posterior fossa cysts (62.5%) were found more commonly symptomatic as shown in table 1. Headache (32%) was the most common symptom in a patient with IAC as shown in table 2. Out of all, 24 patients presented with headache and underwent surgery; 20 showed satisfactory relief after surgery while four showed partial relief. Size of cyst was significantly reduced after surgery in 52 patients after 12 weeks but four patients, who underwent cystoperitoneal shunt, required re-operation as patients showed no decrease in size of cyst due to shunt malfunction. Seizure control was noted in all four patients who presented with seizures. However, it is unclear whether it is due to surgery or antiepileptic prescribed postoperatively. Head circumference was reduced following intervention in infant patients.

Three patients who presented with visual field defects with IAC in sellar region showed improvement after endoscopic fenestration of cyst.

One patient having cyst in right cerebellopontine angle with acoustic neuroma presented with sensorineural hearing loss and facial palsy, in which facial palsy was improved after excision of cyst and acoustic neuroma.

Craniotomy for IAC was done in 31 patients as shown in table 3. The surgery was fenestration, marsupialisation (Figure 1), excision of cyst, cystoventriculostomy or cystocisternostomy.

Endoscopic procedure was done in 14 patients. Four patients with sylvian fissure cyst, four patients with third ventricular region cyst (Figure 2), three patients with suprasellar region cyst, and two cases of infratentorial cyst underwent it. Endoscopic fenestration of IAC in carotid-optico cistern and suprasellar cistern was done successfully for bilateral frontotemporal IAC.

Cystoperitoneal shunting was done in 11 patients by using low pressure shunt (Figure 3). Six patient with supratentorial IAC and five patients with infratentorial arachnoid cysts were shunted.

TABLE I

Distribution of cysts according to location

Location of cysts	No of symptomatic patients	% of symptomatic patients
Anterior cranial fossa	3	5.35
Middle cranial fossa	4	7.14
posterior cranial fossa	35	62.5
convexity	2	3.57
Intraventricular	4	7.14
Quadrigeminal cisterns	5	8.92
Suprasellar cisterns	3	5.35
Total	56	100

TABLE II

Clinical features of different IACs

Sign and symptoms	No of patients	%
Headache	24	32
Seizures	4	5.33
gait disturbances	10	13.33
Cognitive	2	2.66
Focal deficit	2	2.66
Post traumatic Hemorrhage	3	4
Visual	6	8
delayed milestones	7	9.33
Hydrocephalous	17	22.66
Total	75	100

TABLE III

Types of surgery

Type of surgery	No of patients underwent procedure	No. of patients having successful results	No. of patients having unsuccessful results
Craniotomy	31	31	-
Endoscopic procedure	14	14	-
Cystoperitoneal shunting	11	7	4

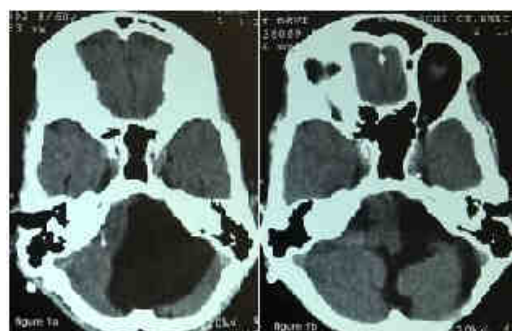


Figure 1a - Pre-operative CT brain of 60 year old female having left cerebellopontine angle arachnoid cyst presented with headache and gait disturbances.

Figure 1b - CT brain of post-marsupialisation of arachnoid cyst showing reduction in size and craniectomy defect

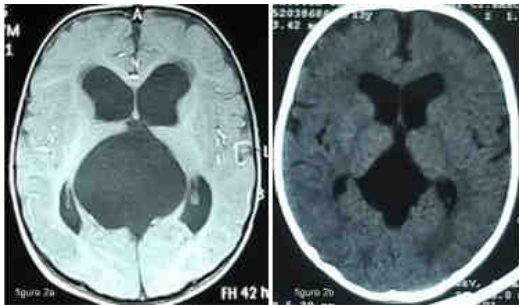


Figure 2a - Pre-operative CT brain of 3 months male having third ventricle arachnoid cyst presented with vomiting and delayed milestones. **Figure 2b** - CT brain of post-endoscopic fenestration of third ventricle cyst with reduction in size seen after four weeks

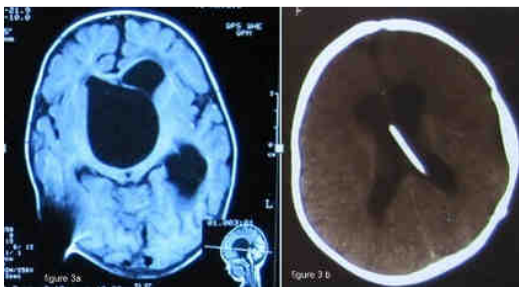

Figure 3a - Pre-operative CT brain of 8 years female having suprasellar arachnoid cyst presented with vomiting, headache and diminution of vision. **Figure 3b** - CT brain of post-cystoperitoneal shunt showing reduction in size of suprasellar arachnoid cyst

Surgical treatment of arachnoid cysts results in complications in eight patients. One patient had CSF leak which was controlled by conservative means. One patient developed wound infection which was treated with higher antibiotics. One patient developed subdural hygroma but fortunately it posed no problem in the patient.

Four patients developed shunt malfunction. In one patient shunt reposition was done in cyst and in another one ventriculoperitoneal shunt was done. In rest

two patients marsupialisation of cyst was done successfully and shunt was removed.

One of the patients with cerebellopontine angle arachnoid was died immediately after marsupialization due to unexplained bleeding.

Discussion

Arachnoid cysts are benign cystic lesions containing cerebrospinal fluid. The increasing use of intracranial imaging especially MRI, has led to more frequent diagnosis of arachnoid cysts. (6, 13) As per study done by Wajid N. Al-Holou et al, the prevalence of arachnoid cyst in children was found to be 2.6% and in adults 1.4%. (1, 2) Cysts in posterior fossa, quadrigeminal cistern and suprasellar cisterns were frequently symptomatic.

Majority of arachnoid cysts are asymptomatic and not all growing cysts may be symptomatic. (14) The intracranial arachnoid cyst can be asymptomatic or can present with symptoms depending on the location of cyst. However there are no guidelines regarding the operative indication or the best treatment modality or choice of surgery.

Patients can present with headache, seizures, gait disturbances, cognitive decline, focal neurologic deficits, cranial nerve palsy, visual disturbances, and increase in head circumference. The sign and symptoms depend on the location and size of cyst.

IAC can be supratentorial or infratentorial. In supratentorial region cyst can be in sylvian fissure, cerebral convexity, sellar or suprasellar, interhemispheric or quadrigeminal. In infratentorial region cyst can be in posterior midline, clival,

cerebellopontine angle, vermis or in cistern magna.

Neurosurgeons agree that patients with IAC with symptoms of intracranial hypertension, intractable seizures, and focal neurologic deficits warrant surgical management. (9)

In patients with symptomatic arachnoid cysts, treatment may lead to lasting relief of focal neurological deficits. (4, 20) Seizures and headaches, however, often persist despite adequate surgical treatment of the cyst, (15) as illustrated by the results of some studies but in our study seizures and headache were relieved following surgery.

Given the difficulty in properly identifying which cysts are symptomatic and the potential for surgical morbidity, further definition of treatment indications would be helpful.

The operative indication for IAC depends on signs and symptoms, site of cyst, size of cyst, features of raised intracranial pressure, and measurement of ICP. The choice of surgery depends on the age of patient, the distance between the lesion and the neighbouring ventricle or cistern, presence of hydrocephalus, mass effect caused by cyst, relation with surrounding structures.

Surgical options available are open craniotomy for cyst removal or fenestration into adjacent arachnoid spaces, shunting or stenting of cyst contents into ventricle, endoscopic fenestration or cystoperitoneal shunt operation. (18)

Although any surgical technique to treat an arachnoid cyst may result in complication, the preference for any given surgical technique over another has been debated. (12, 15)

Among surgical options, primary endoscopic fenestration appears to be an ideal procedure. As the target membranes are avascular, CSF provides optimal image transmission and the method of fenestration is familiar to those performing neuroendoscopy. (11)

In our study, the principal of surgery was fenestration, marsupialisation, excision of cyst, cystoventriculostomy or cystocisternostomy, either by craniotomy or by endoscopy. Cystoperitoneal shunting was also done in some cases.

The results of our study of either endoscopy or craniotomy were similar but the endoscopic approach had advantage, as procedure was minimally invasive, associated with less bleeding and early recovery. Cystoperitoneal shunting was effective for large cysts, particularly by using the low pressure shunt. However, recurrence of the cyst was noted and shunt related complications were also seen, thus cystoperitoneal shunting should not be the first choice as per our view.

Surgical treatment of arachnoid cysts may occasionally result in complications, including pseudomeningocele and CSF leak, (15) wound related complications, (12, 15, 16) infection, (15) subdural hygroma, (15, 16) subdural hematoma (12, 16) seizure, (15) redo surgery (12, 15) and the risk of shunt dependency and its overdrainage. (17)

Johnson et al. (10) found that endoscopic treatment of middle cranial fossa arachnoid cysts resulted in subdural hygromas and subdural hematomas in 9% and 5% of cases, respectively. But only single patient in our study developed subdural hygroma during the

follow-up.

Haemorrhage into the subdural space or into the arachnoid cyst has been reported in patients with arachnoid cysts. (3, 5, 19) The potential for haemorrhage has been used as a justification for prophylactic treatment of asymptomatic arachnoid cysts by some authors. (19) It is a rare event and not even a single patient in the natural history group experienced a haemorrhage. Haemorrhages associated with arachnoid cysts have been reported in the literature are associated with generally good outcomes (19) and Surgery may not eliminate the risk of future haemorrhage in these patients. (14, 21) We do not regard the potential for future haemorrhage as a justification for prophylactic surgical treatment. But if the patient presented with haemorrhage in cyst, surgical treatment was done. Three patients (4%) presented with posttraumatic haemorrhage in cyst in our study.

The cysts should be treated if they demonstrate evidence of local mass effect on imaging (7, 8) We do recommend surgery for cysts when there is an appearance of mass effect seen on imaging.

Conclusion

Arachnoid cysts are frequently discovered incidentally on intracranial imaging. Most arachnoid cysts are asymptomatic. Patients with intracranial arachnoid cyst should be treated only if the patient's symptoms are attributable to the cyst. Modality of surgery doesn't create any difference in the outcome, though Endoscopy has the advantage of minimal invasiveness.

Correspondence

Dr. Mukesh Sharma

Department of Neurosurgery, S.M.S. medical college and Hospitals Jaipur Rajasthan (India) 302004

Telephone no. 91-9672209314

Email: dr_mukki@yahoo.co.in

References

1. Al Holou WN, Yew AY, Boomsaad ZE, Garton HJ, Muraszko KM, Maher CO. Prevalence and natural history of arachnoid cysts in children. *J Neurosurg Pediatr* 5 :578 85, 2010
2. Al-Holou WN, Terman S, Kilburg C, Garton HJ, Muraszko KM, Maher CO. Prevalence and natural history of arachnoid cysts in adults. *J Neurosurg* 118:222-31, 2013
3. Bilginer B, Onal MB, Oguz KK, Akalan N: Arachnoid cyst associated with subdural hematoma: report of three cases and review of the literature. *Childs Nerv Syst* 25:119–124, 2009
4. Boutarbouch M, El Ouahabi A, Rifi L, Arkha Y, Derraz S, El Khamlichi A: Management of intracranial arachnoid cysts: institutional experience with initial 32 cases and review of the literature. *Clin Neurol Neurosurg* 110:1–7, 2008
5. Domenicucci M, Russo N, Giugni E, Pierallini A: Relationship between supratentorial arachnoid cyst and chronic subdural hematoma: neuroradiological evidence and surgical treatment. *Clinical article. J Neurosurg* 110:1250–1255, 2009
6. Eskandary H, Sabba M, Khajehpour F, Eskandari M: Incidental findings in brain computed tomography scans of 3000 head trauma patients. *Surg Neurol* 63(6):550-3, 2005
7. Go KG, Houthoff HJ, Blaauw EH, Havinga P, Hartsuiker J: Arachnoid cysts of the sylvian fissure. Evidence of fluid secretion. *J Neurosurg* 60:803–813, 1984
8. Harsh GR IV, Edwards MS, Wilson CB: Intracranial arachnoid cysts in children. *J Neurosurg* 64:835–842, 1986
9. Hellwig D, Schulte M, Tirakotai W. Surgical management of arachnoid, suprasellar, and Rathke's cleft cysts. In: Schmidek HH, Roberts DW, editors. *Schmidek and Sweet Operative Neurosurgical Techniques*. 5th ed., vol. 1. Philadelphia: Saunders Elsevier; 2006. p. 455 76.

10. Johnson RD, Chapman S, Bojanic S: Endoscopic fenestration of middle cranial fossa arachnoid cysts: does size matter? *J Clin Neurosci* 18:607–612, 2011
11. Kandasamy J, Souweidane M. Editorial: Arachnoid cysts. *J Neurosurg Pediatr* 9:228–30, 2012
12. Kang JK, Lee KS, Lee IW, Jeun SS, Son BC, Jung CK, et al: Shunt-independent surgical treatment of middle cranial fossa arachnoid cysts in children. *Childs Nerv Syst* 16:111–116, 2000
13. Katzman GL, Dagher AP, Patronas NJ: Incidental findings on brain magnetic resonance imaging from 1000 asymptomatic volunteers. *JAMA* 282:36–39, 1999
14. Lee JY, Kim JW, Phi JH, Kim SK, Cho BK, Wang KC. Enlarging arachnoid cyst: A false alarm in infants. *Childs Nerv Syst* 28:1203–11, 2012
15. Levy ML, Wang M, Aryan HE, Yoo K, Meltzer H: Microsurgical keyhole approach for middle fossa arachnoid cyst fenestration. *Neurosurgery* 53:1138–1145, 2003
16. Marin-Sanabria EA, Yamamoto H, Nagashima T, Kohmura E: Evaluation of the management of arachnoid cyst of the posterior fossa in pediatric population: experience over 27 years. *Childs Nerv Syst* 23(5):535–42, 2007
17. Martínez-Lage JF, Ruíz-Espejo AM, Almagro MJ, Alfaro R, Felipe-Murcia M, López-Guerrero AL: CSF overdrainage in shunted intracranial arachnoid cysts: a series and review. *Childs Nerv Syst* 25:1061–1069, 2009
18. Oertel JM, Wagner W, Mondorf Y, Baldauf J, Schroeder HW, Gaab MR. Endoscopic treatment of arachnoid cysts: A detailed account of surgical techniques and results. *Neurosurgery* 67:824–36, 2010
19. Parsch CS, Krauss J, Hofmann E, Meixensberger J, Roosen K: Arachnoid cysts associated with subdural hematomas and hygromas: analysis of 16 cases, long-term follow-up, and review of the literature. *Neurosurgery* 40:483–490, 1997
20. Shim KW, Lee YH, Park EK, Park YS, Choi JU, Kim DS: Treatment option for arachnoid cysts. *Childs Nerv Syst* 25 : 1459–1466, 2009
21. Spacca B, Kandasamy J, Mallucci CL, Genitori L: Endoscopic treatment of middle fossa arachnoid cysts: a series of 40 patients treated endoscopically in two centres. *Childs Nerv Syst* 26:163–172, 2010