

5 years experience in epidermoid and dermoid cysts: case presentation and literature review

G. Popescu, A. Giovani, N. Bucur, A. Neacsu, A. Gheorghiu, S. Mara, R.M. Gorgan

“Bagdasar Arseni” Clinical Emergency Hospital, 4th Neurosurgical Department

Abstract: *Introduction:* Intracranial epidermoid and dermoid cysts are the result of an embryogenesis dysfunction leading to an abnormal migration of ectodermal cells characterised by a slow and benign rate of growth which is associated with minimal neurological symptoms in large or giant tumors. *Materials and methods:* We retrospectively reviewed the case files of 17 patients with epidermoid and dermoid cysts operated using the operative microscope and neuronavigation in our department between January 2011 and December 2015. *Results:* Reviewing the case files we selected fourteen patients with epidermoid cysts and 3 patients with dermoid cysts who underwent surgical resection. Most of the cysts were located infratentorial (64%) with a propensity for the CP angle (81%). Total resection was attempted in all cases but was possible in only 13 cases. All cases with subtotal resection were infratentorially located in close relation to the brainstem or cranial nerves. *Conclusion:* When the tumor extension reaches beyond the limits of the surgical approach used, the tumor remnant should be addressed in a second surgery. Using the cysternal anatomy and the vessels dissection technique the risks aseptic meningitis and of injuring the cranial nerves are diminished.

Introduction

Dermoid cysts, also known as dermoid tumors or ectodermic inclusion cysts, are benign congenital inclusion cysts, representing one of the rarest forms of benign intracranial lesion, their frequency ranging from 0.04% to 0.6% of all intracranial tumors.

They are usually sporadic rather than familial, but up to half of all patients with dermoid cysts have additional congenital

abnormalities. Because of a common congenital origin they have frequently been confused with epidermoid cysts, although intradural dermoid cysts are four to nine times less common than epidermoid lesions. As many as one third of dermoid cysts are associated with dermal sinus tracts. Dermoid and epidermoid cysts are both thought to arise from defects in the separation of the neuroectodermic plate during the formation of the neural tube, leading to sequestration of

ectodermic remnants.

Epidermoid cysts are more common and are not usually located in the midline, which is the location of most dermoid cysts. Many reports indicate that the midline below the tentorium is the preferential location site of intradural dermoid cysts, often associated with the occipital dermal sinus. More recent series show a higher frequency of supratentorial than infratentorial dermoid cysts. Intracranial dermoid cysts are well circumscribed and most often occur in the parasellar region, sylvian fissure, cerebellopontine angle, posterior fossa, and fourth ventricle. Patients with dermoid cysts usually present with symptoms related to a focal mass effect, seizures, or recurrent meningitis.

On CT scans, dermoid cysts usually appear as nonenhancing, hypodense lesions, and on MR images they demonstrate increased T1- and variable T2-weighted signal. Less frequently, the cyst contents can be hyperdense mimicking a hemorrhage. It is important to recognize the unusual imaging characteristics of some dermoid cysts because they are managed differently from posterior fossa hemorrhage.

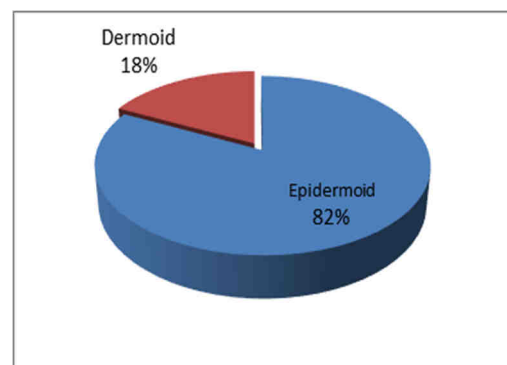
Materials and methods

We retrospectively reviewed the case files of 14 patients with epidermoid and dermoid cysts operated in our department between January 2011 and December 2015. The microneurosurgical technique performed under the operative microscope was used in most of the cases. Neuronavigation was also used in cases where we considered it was useful. In all the cases the diagnosis of epidermoid/dermoid cyst was suspected on

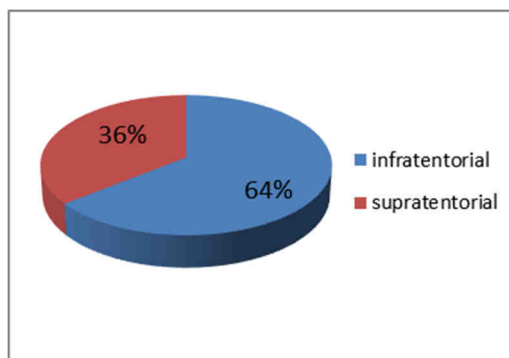
the MRI. The clinical setting, the preoperative and postoperative CT-scans and MRI's were reviewed and where available the entire operative video was analyzed in order to provide details associated with the impossible total resection.

Results

Fourteen patients with epidermoid cysts and 3 patients with dermoid cysts underwent surgical resection in our department during January 2011 and December 2015. The mean age at presentation was 32.4 years old, with a slight male predominance 10:7. Most of the patients had a long symptoms history before surgery with an average of 6.7 years. The most common symptoms in patients with supratentorial cysts were headache and seizures while imbalance, headache and cranial nerve deficits (especially trigeminal and vestibulocochlear) predominate in the infratentorial location. Most of the tumors (64.7%) were located infratentorially and most of these were located in the cerebellopontine angle (81.8%) and one was located predominantly inside the IVth ventricle and one in the prepontine cistern.



Pathological based distribution



Location based case distribution

Main neurologic symptoms	
Supratentorial	-Seizures -Headache
Infratentorial	-Imbalance -Cranial nerve deficit -Headache

All the tumors in this series were resected using the microdissection of the arachnoid space in order to free the vessels and nerves involved by the tumor. We achieved gross total resection in all supratentorial cysts and subtotal resection in 4 infratentorial tumors, one with interpeduncular extension and 3 with infra/supratentorial extension. All these 4 patients with incomplete removal of posterior fossa epidermoids lately presented with symptoms of hydrocephalus and required ventriculoperitoneal shunting.

Operative technique

Minimal brain retraction and minimal cortical damage was the key point we followed in choosing the surgical approach to the tumor. That is why we used skull base approaches or for the supratentorial location, where possible, natural corridors like fissures

or large sulci to approach the tumor. The shortest way to the tumor was used in any case, and the neuronavigation was an advantage in reaching this purpose. Once the tumor is reached, its capsule was entered with a scalpel followed by internal debulking with aspiration in order to avoid spilling the contents in the surgical corridor. After enough debulking has been achieved the capsule dissection is started and the vessels and nerves are carefully freed from the adherences to the capsule. Traction on the tumor before the entire capsule has been freed should be avoided. We noticed a surgical difference between epidermoid and dermoid cysts in that the latter are more adherent to the arachnoid and even the pia mater. Given the pattern of growth inside the cisterns we even achieved a total resection using a retrosigmoidian approach in a few cases with supratentorial parasellar extension.

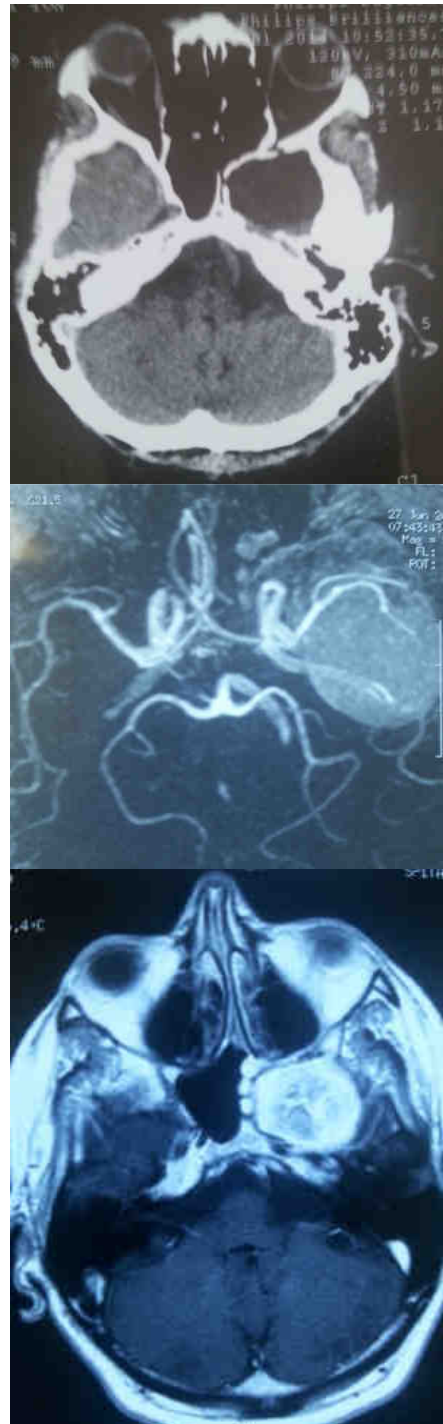
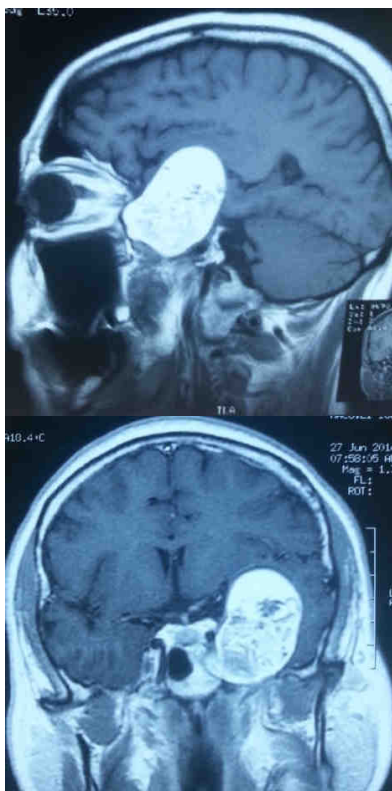
The most common complications encountered were hydrocephalus in 4 cases, aseptic meningitis in 3 cases. 3 patients with CP angle located tumors presented with new transient cranial nerve palsies. Two patients presented with postoperative seizures that were controlled with medication.

The mean follow up of the patients was of 2,4 years. There was no evidence of tumor recurrence in this follow up interval.

Case 1

The Patient was accepted in our service with bilateral temporal headache and left facial paresthesia. The neurological examination showed left facial paresis, without focal motor deficit, or epileptic seizures.

Imaging Work-up showed a well-defined left parasellar tumor, with lipid and solid components, without enhancement after gadolinium injection, 3/3,5/5 cm in diameter showing homogenous hypointensity in T1 and hyperintensity in T2. Angio MRI was within normal limits making the differential diagnosis with a middle fossa meningioma. Gross total resection was achieved through a fronto-temporal craniotomy, with opening of the carotid-optic cistern. The large tumor, was located in the temporal lodge to the sphenoidal sinus, was well defined, white and made of tissue, hair and fat. The histopathological examination revealed a dermoid cyst with didermic mature teratoma areas.



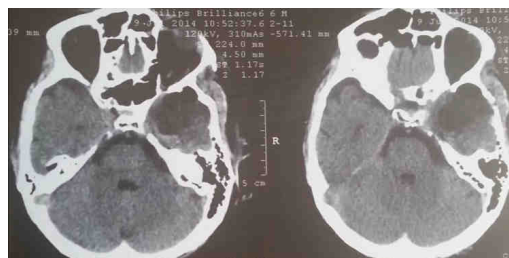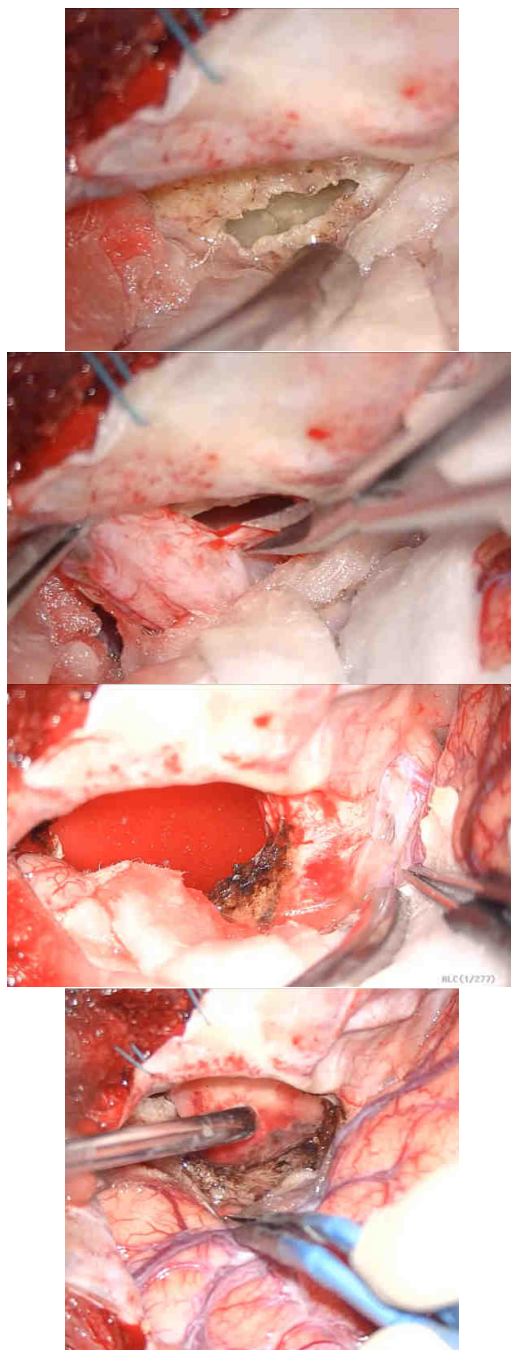


Figure 1 - Left middle fossa dermoid compressing the cavernous sinus and displacing the left MCA (a, b). Hair is encountered during tumor debulking (c). Part of the cyst capsule is resected to allow better extracapsular dissection (d). The left optic nerve and carotid are identified and followed distally in order to dissect the tumor capsule from the middle cerebral artery (f). Middle fossa dura after total resection and haemosthesis was achieved. Postop CT scan showing total resection (g).

<https://www.youtube.com/watch?v=O4re9RPbtLI>

Case 2

A 32 yo Male patient, was admitted in our clinic for history of headache, right hearing loss, dizziness for more than 1 month. The neurological examination revealed nonsystematic balance disorder; and sensitivity disorders: headache, dizziness. As well right hearing loss with uncertain debut was reported. The MRI scan showed a pontocerebellar angle extraneuraxial expansive lesion, that develops in the cerebellopontine angle cistern and extends inside the internal auditory canal (which appears enlarged) with mass effect on the acustico-vestibular nerves (that is compressed antero-superiorly) without infiltrating it and on the brainstem, mid cerebellar peduncle and the fourth ventricle (without hydrocephalus). The described cisternal mass has lobulated contour,

heterogeneous structure, without gadolinium enhancement and 4,1/2,7 cm in diameter.

The tumor was completely resected using a retrosigmoid approach and a microsurgical technique to dissect it from the cranial nerves, AICA and SCA.

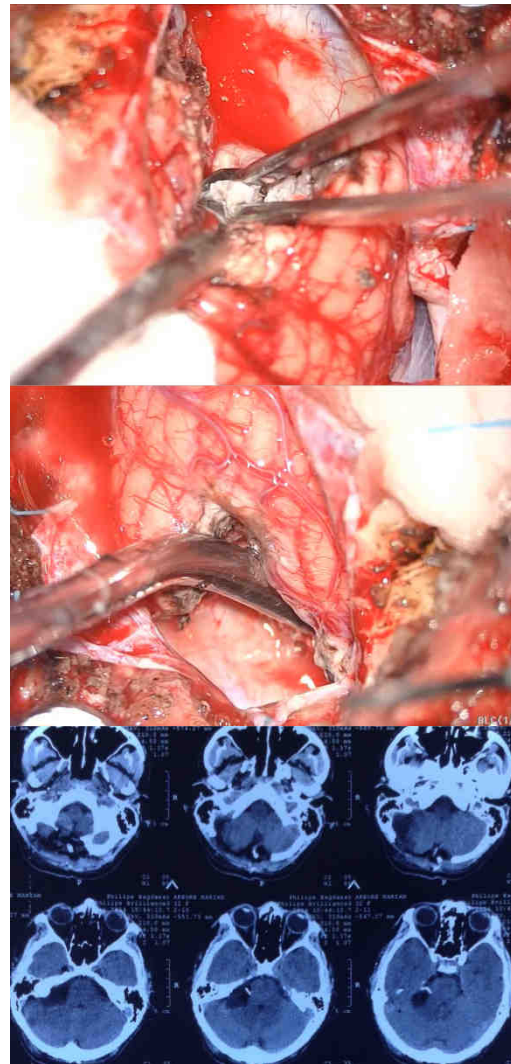
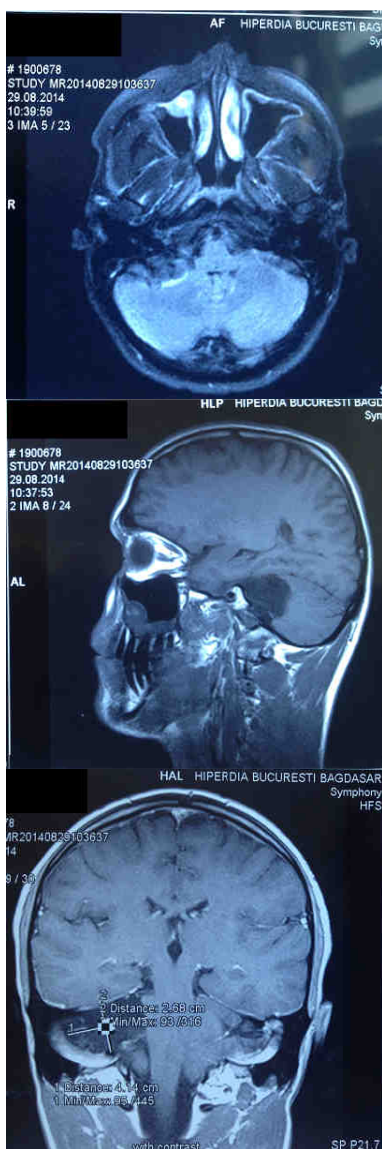
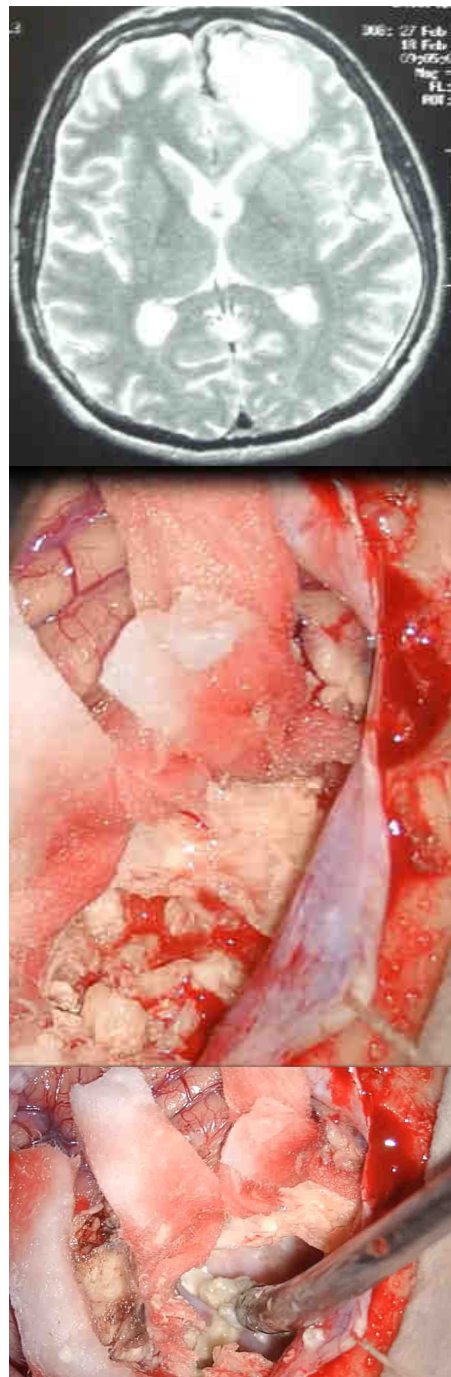
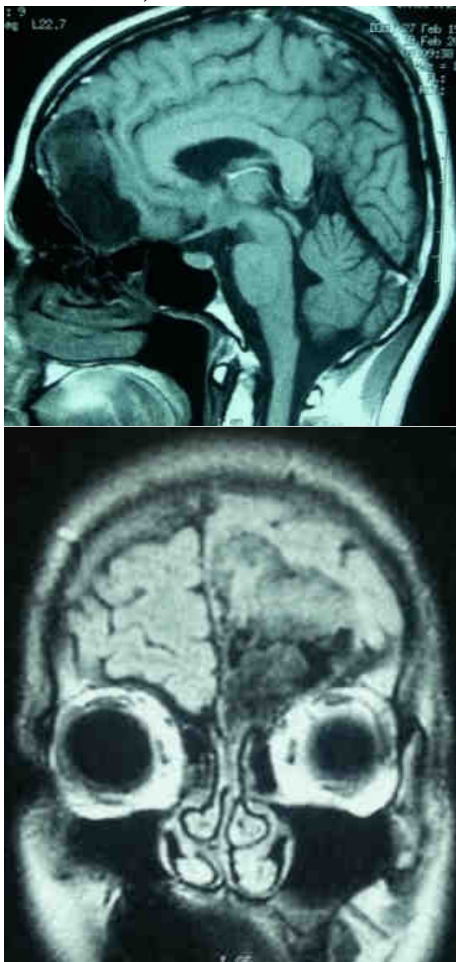


Figure 2 - left CP angle epidermoid cyst compressing the Vth, VII and VIIIth nerves. Internal tumor debulking. Total removal after the cranial nerves were freed from the tumor capsule. 24h postoperative CT scan, showing the resection cavity.
<https://www.youtube.com/watch?v=3e39shAdQZY>

Case 3

A 39 yo male patient, was admitted for headache and epileptic seizures lasting for

more than 6 months. The CT scan showed a well-defined, left frontal intracranial expansive process, partially calcified, without edema and a normal midline ventricular system. The MRI showed a left frontal extraaxial well-circumscribed mass, extending in the left ethmoidal cells. Gross total resection of the described tumor was achieved using a subfrontal approach. The histopathological examination was suggestive for dermoid cyst (cholesteatoma).



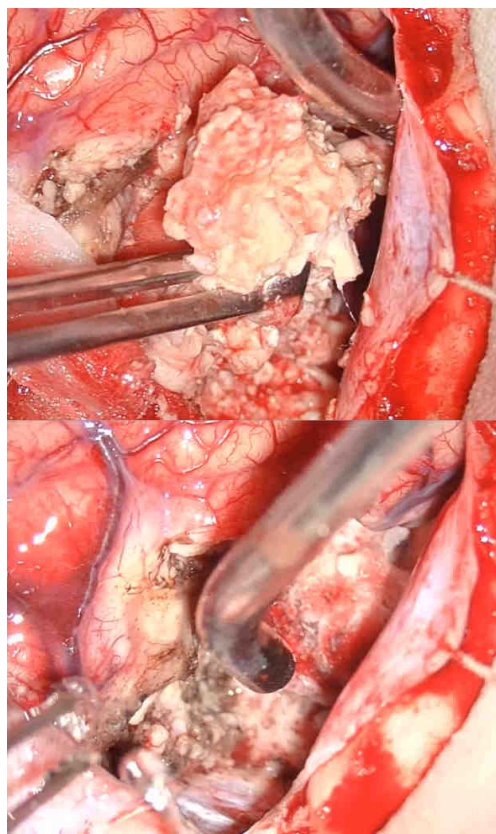


Figure 3 - Frontoetmoidal giant epidermoid cyst displacing the left ophthalmic and optic nerves.

Intraoperative aspect after incising the cyst. The cyst wall seen from the inside during internal debulking. A view along the falx during the final hemostasis after total removal was achieved.

<https://www.youtube.com/watch?v=ZySC4OoUk9o>

Discussions

Since Yasargil et al presented their series of 43 patients with epidermoid and dermoid cysts operated in 22 years there were many reports on this focus with a special interest in CP angle tumors with intraventricular or supratentorial extension. Hitoshi et al. presented a series of 30 cp angle epidermoids operated in a time span of 14 years presenting

with cranial nerves hyperactive dysfunction especially trigeminal neuralgia. In this series the patients with trigeminal neuralgia following direct trigeminal nerve irritation were significantly younger than those with symptoms caused by vascular compression.

In 2008 Liu et al. presented their results with 5 cases of ruptured intracranial dermoid cysts discussing clinical, diagnostic and therapeutic aspects.

Most of the patients have their epidermoid cysts discovered in the 2nd decade, yet some authors have reported series of patients commonly diagnosed in the 3rd or 4th decades of life. Patients with posterior fossa dermoid cysts typically present with neurological symptoms when the cyst is larger than 3 cm. Most cases are characterized by a chronic and progressive course rather than an acute clinical decline. Neurological deficit, recurrent meningitis, seizures, and chronic headaches are the most common symptoms.

The current theory is that the dermoid cyst develops from a tuck of skin which may be retained when the dura mater invaginates to form the tentorium, the high incidence of associated dermal sinuses confirms the dysembryogenetic theory.

In all likelihood, supratentorial dermoid cysts arise due to misplacement of embryonic inclusions in the vicinity of the developing neural tube up to the 3rd week of life, during Carnegie stages 8 to 10, when the neural groove begins to close. Cranial abnormalities such as bone defects, dermal sinuses, or meningoencephaloceles are not associated with this development.

Because epidermoid/dermoid cysts have a

soft consistency they can grow to impressive dimensions spanning more than one cystem in some of the cases extending from one skull base fossa to another. Because these tumors are well encapsulated and the capsule is not adherent to the vasculo-nervous elements it compresses, as well as because its contents are easily aspirable the approach to these tumors should focus not on the tumor itself but on the important structures related to the tumor that should be avoided during the approach.

Most of the epidermoid cysts in the posterior fossa (60%) are located in the cerebellopontine angle, where they are the 3rd most common tumor after vestibular schwannomas, and meningiomas. Following the CP angle, the most common location for epidermoids is the IVth ventricle. Other rare locations can require a difficult surgical approach like those for the petroclival, prepontine or pineal region. Many classifications have been used for posterior fossa epidermoids given the unusual growth patterns of these tumors including those of Yasargil and Samii. Bricolo et al. classifies the posterior fossa epidermoids in CPA lesions with suprasellar/chiasmatic, parasellar/temporobasal or mesencephalic/pineal extension, posterior fossa basal lesions with the same 3 possible extensions or 4th ventricle lesions.

Location (n)	Tumor Extension (n)	Removal Rate (n)		Remnants	
		Total	Subtotal	Re	NV
CPA (20)	Pure CPA (6)	5	1		1
	Suprasellar (5)	2	3	3	
	Parasellar (3)	1	2	2	
	Mesencephalic (6)	3	3	2	1
Posterior fossa basal (3)	Parasellar (2)	2			
	Mesencephalic (1)		1	1	
Fourth ventricle (5)		3	2		2

^a Re, tumor remnants remote from the primary location; NV, tumor remnants attached to neurovascular structures (brain stem, cranial nerves, vessels); CPA, cerebellopontine angle.

With permission from Tallachi et al *Assessment and Surgical Management of Posterior Fossa Epidermoid Tumors: Report of 28 Cases, Neurosurgery. 42(2):242-251, February 1998*

Most of the tumors located in the CP angle determine irritative symptoms usually in one of the involved cranial nerves either trigeminal, facial or acoustic. Intracranial hypertension signs are rarely a complaint in posterior fossa epidermoids.

The MRI is the investigation of choice both because it differentiates the cyst from the adjacent cystems and it makes a differential diagnosis between these cysts and the arachnoid cysts. The lack of peritumoral edema indicates that the blood brain barrier has not been disrupted by the slow growing tumor. One should always keep in mind during the surgery that all the tumors initiate their growth in the cisterns and develop where they find a cisternal enlargement or an intraventricular cavity even if their development in the third and lateral ventricles is quite a rare manifestation. In large middle fossa extensions of posterior fossa epidermoids, the usual retrosigmoid approach should be combined with a presigmoid approach in order to attempt a total resection.

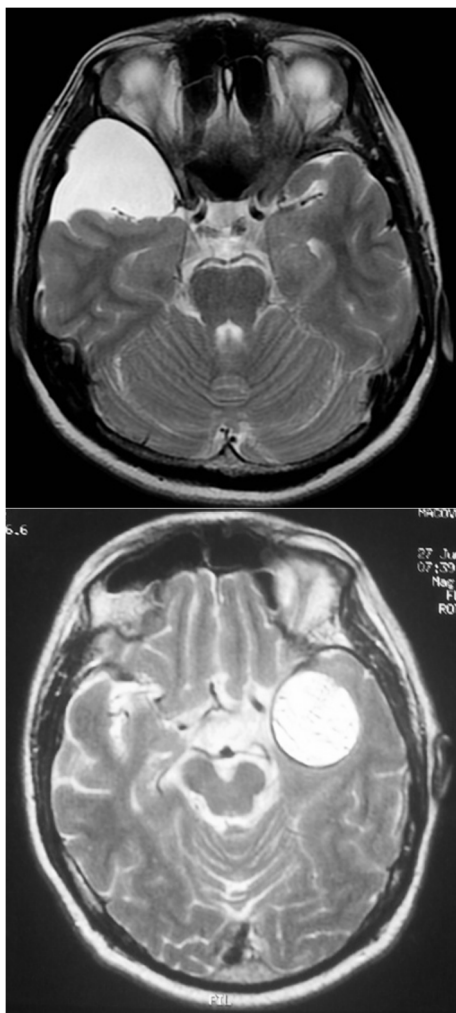


Figure 4 - differential diagnosis between an arachnoid cyst (a) and an epidermoid cyst (b) – note that in T2 the images look alike yet a fine capsule can be distinguished surrounding the epidermoid, and also its content is less homogenous than the arachnoid cyst

Another important clue to a definitive cure of an epidermoid tumor is to avoid spilling the tumor into adjacent cisterns or anywhere in the surgical corridor as this may be the cause

of distant spreading of the tumor or of aseptic meningitis.

Most authors report total removal in less than 60% of cases precisely because the tumor extension cannot be removed through a single approach without causing collateral damage.

Conclusion

All efforts should be made to achieve a total resection of epidermoid and dermoid cysts, using a clean technique that avoids spilling the cyst contents and diminishes the risk of distant recidives and aseptic meningitis. When the tumor extension reaches beyond the limits of the surgical approach used, the tumor remnant should be addressed in a second surgery. Using the cisternal anatomy and the vessels dissection technique the risks aseptic meningitis and of injuring the cranial nerves are diminished.

References

1. Abramson RC, Morawetz RB, Schlitt M: Multiple complications from an intracranial epidermoid cyst: Case report and literature review. *Neurosurgery* 24:574–578, 1989.
2. Arseni C, Danaila L, Constantinescu AI, Carp N, Decu P: Cerebral dermoid tumours. *Neurochirurgia (Stuttg)* 19:104–114, 1976.
3. Berger MS, Wilson CB: Epidermoid cysts of the posterior fossa. *J Neurosurg* 62:214–219, 1985.
4. Carvalho GA, Cervio A, Matthies C, Samii M: Subarachnoid fat dissemination after resection of a cerebellopontine angle dysontogenic cyst: Case report and review of the literature. *Neurosurgery* 47:760–764, 2000.
5. Lunardi P, Missori P: Supratentorial dermoid cysts. *J Neurosurg* 75:262–266, 1991.

6. Yasargil MG, Abernathey CD, Sarioglu AC: Microneurosurgical treatment of intracranial dermoid and epidermoid tumors. *Neurosurgery* 24:561-567,1989.
7. Vinchon M, Pertuzon B, Lejeune JP, Assaker R, Pruvo JP, Christiaens JL: Intradural epidermoid cysts of the cerebellopontine angle: Diagnosis and surgery. *Neurosurgery* 36:52-57, 1995.
8. Vion-Dury J, Vincentelli F, Jiddane M, Van Bunnan Y, Rumeau C, Grisoli F, Salamon G: MR imaging of epidermoid cysts. *Neuroradiology* 29:333-338, 1987.
9. Lunardi P, Fortuna A, Cantore G, Missori P: Long term evaluation of asymptomatic patients operated on for intracranial epidermoid cyst: Comparison of the diagnostic value of magnetic resonance imaging and computed-assisted cisternography for detection of cholesterolin fragments. *Acta Neurochir (Wien)* 128:122-125, 1994.
10. Alvord EC Jr: Growth rates of epidermoid tumors. *Ann Neurol* 2:367-370, 1977.