

Differential diagnostic problems in elderly chronic subdural hematoma patients

Valentin Munteanu¹, Ionut Luca-Husti², Teodora Camelia Coman¹, Alexandru Vlad Ciurea^{2,3}

¹“Bagdasar Arseni” Emergency Hospital, Bucharest

²Sanador Clinical Hospital, Bucharest

³“Carol Davila” University of Medicine and Pharmacy, Bucharest

Abstract: Chronic subdural hematomas (CSDH) are recognized as common in older people (over 70 years). They are produced in minor injuries (falls on the same level). These CSDH have minor symptoms (headache, memory disorders, balance disorders, cognitive disorders, etc. and are classified as signs for the onset of dementia, circulatory failure - basilar vertebra, Alzheimer, etc. A simple brain CT scan can highlight these hematomas and a neurosurgical intervention will achieve extremely favorable prognosis. There are many pitfalls in the differential diagnosis of CSH especially with strokes being so common at this age.

Key words: chronic subdural hematoma, older patients, CT scan, GCS, GOS, and neurosurgery

Introduction

Diseases with surgical recommendation in elderly patients, especially for those over 70 years old, involve significant risks both surgically and anesthetically, given the associated rich pathological context, as well as a very likely reduction in the body's available capability to recover after as a resource-consuming event, as surgery.

The most common diseases of the elderly are obvious and indisputable, cardiovascular diseases accompanied by disorders of lipid metabolism with formation of atheroma

plaques, leading most often to ictal neurological pathology like the hemorrhagic or ischemic strokes. In neurovascular pathology, the transitory ischemic stroke is an event that foresees severe lesions with permanent effects that can present itself later on.

These considerations determine a more aggressive therapeutic approach from the neurological medical community in order to prevent events with significant consequences.

In the case of neurosurgical pathology of these patients an important place is occupied by the chronic subdural hematoma. The main

etiological factor in the occurrence of subdural hematic collections is obviously the traumatic brain injury, but in the case of chronic subdural hematoma the traumatic factor is often unrecognized by patients or persons around them. The reason is that the traumatic event has taken place usually far away from the moment of the deceleration of the collection (usually at least 3 weeks) and the trauma is usually minor and overlooked immediately after production.

The reasons favoring this particular type of intracranial fluid accumulation are related on one hand to the age-related involution of the brain parenchyma with subsequent atrophy and increased peri-cerebral spaces and on the other hand the long-term use of antithrombotic medication such as aspirin or other anticoagulants in the context of very likely associated cardiovascular diseases, which implies a more difficult hemostasis in case of any lesion in the “bridging” dural veins tensed by the reduction of the volume of the cerebral parenchyma.

The most commonly used diagnostic method is computed tomography imaging which brings enough information to establish a diagnosis and a suitable treatment plan. Chronic subdural hematomas occur classically under the form of a crescent hypo-dense collections located extra axially with mass effect on the adjacent brain parenchyma. Depending on the time elapsed from the initial bleeding until the diagnosis the images can be different in relation to the adjacent parenchyma. This describes three phases of evolution: the first 7 days of collection has a hyper-dense appearance corresponding to the

acute phase of bleeding, then for approx. 2 weeks iso-dense collection compared to the brain parenchyma, followed only after the third week of evolution to be described as having the classical hypo-dense fluid accumulation. Thus between the first and third week of chronic subdural hematoma bilateral evolution can be very difficult to see on the native CT imaging, especially because the midline structures might not be deflected in this case.

Clinical symptoms that determines the patient to go to the doctor is nonspecific and often installs in an insidious way, some patients have minor symptoms. Patients may complain of impaired consciousness with sleepiness, which is associated in varying proportions with headache, walk and balance disorders, cognitive disorders, personality changes or motor deficit or aphasia. Often the onset symptoms are super-imposable on a clinical picture of transient ischemic stroke. The most common symptoms are headache, confusion syndrome and various degrees of neurological motor deficit.

Accordingly, when the CT imaging reveals iso-dense subdural collection hardly distinguishable from the brain parenchyma and it will not cause a significant mass effect, the differential diagnosis of minor neurological disorders and transient becomes difficult. Within the neurological therapeutics the administration of anticoagulant and anti-platelet medication is very important in the prevention of acute ischemic events. A major disadvantage of taking this type of medication is that it predisposes to bleeding complications if the patients must undergo major surgery.

The latter must be timed according to the medication administered, for varying time intervals that can reach up to several days. These delays in adopting surgical treatment solutions may have important consequences for the affected patients. On the other hand the administration of anticoagulant and anti-platelet therapy may increase the volume of intracranial hematic collections with the worsening of the accompanying neurological phenomena.

Material: case presentation

In the following we want to present the case of a 72 years old patient with known hypertension in treatment, accusing short speech disorder episodes of “verbal barrage”, which were resolved at a minimum diuretic therapy, the allegations were recorded for approx. 2 weeks.

The medical history revealed the existence of a head injury secondary to an accident, approx. 1.5 months prior to the installation of the symptoms. The injury was considered minor, followed by easy and fast reversible alteration of consciousness immediately posttraumatic with no obvious cranial trauma signs. The patient initially addressed the service of Neurology, where the patient's complaints were interpreted as the manifestation of transient ischemic strokes and was prescribed anti-platelet treatment with Plavix. It is worth noting that the neurological consult ran a cerebral CT scan showing a subdural collection in the left cerebral hemisphere, without an obvious compressive character and was not considered to be an important factor of the symptom (Figure 1).

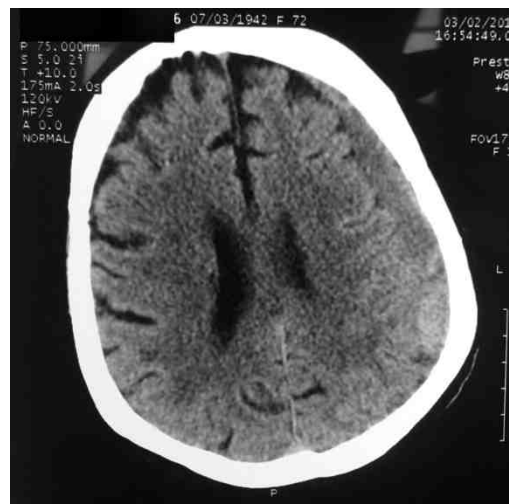


Figure 1 – A.M. – CT aspect at admission

Given the absence of a favorable response to therapy by repeating the symptoms present at admission, the neurologist guided the patient to get a neurosurgical consult. After analyzing the CT imaging presented by the patient it is decided to adoption of a surgical therapeutic solution to evacuate the visualized collection. Considering the introduction of treatment with Plavix earlier, the surgical therapeutic solution, even if it involves a minimally invasive approach has high risks in terms of bleeding. For this reason it was decided to stop the Plavix treatment for at least 7 days before surgery and replaced with low molecular weight heparin with clinical supervision to highlight any worsening of neurological status of the patient.

Surgery was performed safely, 7 days after discontinuation of anti-platelet medication, evacuating the collection through two drill holes and abundantly irrigating the subdural space (Figure 2).

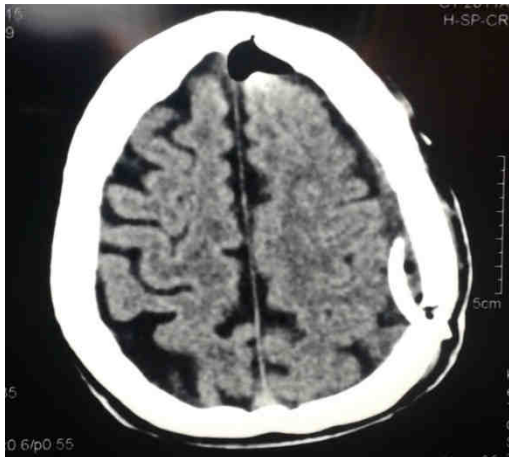

Figure 2 – A.M. – CT native aspect 24 hours post operatory

Post operatory, given the associated pathology of the patient, she was monitored within the first 24 hours in the intensive care unit. The evolution was favorable with the relief of the neurological symptoms without repeating the episodes of verbal barrage.

We can say that surgery was postponed with more than two weeks from the moment of the first consultation with the intention to minimize the potential irrigative effect of the CT visualizations – even though a little compressive - corroborated with a possible „illusion” of the symptomatological interpretation seen through “the lens” of the known pathology treated as it currently is.

This case had, fortunately, a very favorable evolution, with restoration of the optimal neurological functionality. However, by adopting – for a longer time period – of the wrong therapeutic attitude, it could have evolved towards severe neurological deficits. (Figure 3).

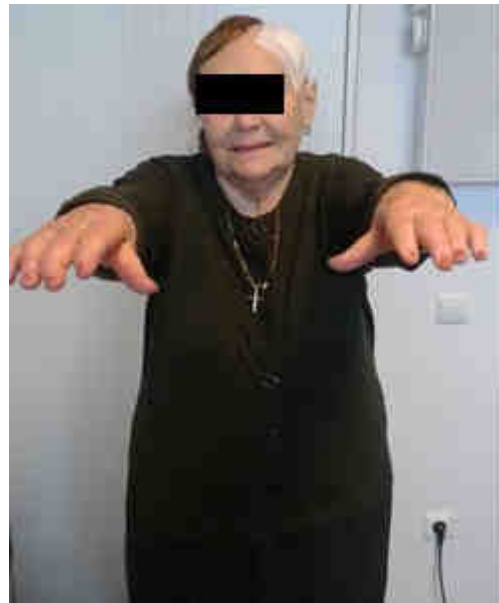

Figure 3 – 3 days after surgery, patient discharged

Discussion

Chronic subdural hematoma (CSDH) is one of the major co-morbidities in elderly resulting in disability and death. Early recognition of CSDH is important for early management. However, manifestations of CSDH are nonspecific and subtle (8, 9).

Mixed density of CSDH on radiological investigations results from multiple episodes of trauma, usually in the aged. Although there were membranes within the mixed density hematomas, burr-holes were usually enough to drain the hematomas (6).

Surgical evacuation is the basis of management for symptomatic patients or hematomas exerting significant mass effect. Although burr whole craniotomy is the most widely practiced technique worldwide, approximately 10-20% of surgically treated patients experience postoperative recurrence necessitating reoperation (2). Recurrence rates

in single and double-burr-hole groups were 6.15% and 4.83% respectively, which was not statistically significant. Most of the subdural hematomas can be dealt by single burr-hole drainage (4). Trepanation may be superior to craniotomy as primary surgery for sub-acute and chronic hematomas (1).

A study on 45 patients 70 years of age or older relieves that there was a significant improvement in the neurological status of patients from admission to follow up as assessed using the Markwalder grading scale, yet no improvement in functional outcome was observed as assessed by Glasgow Outcome Score (3). Surgery for CSDH is safe and positively recommended even in super-aged patients over 90 years old if the patient's physical status is fair. Pre-illness status is the most important factor for considering operative indications and represents a limiting factor for postoperative outcomes in this age population (7).

Results of a new study on patients with anti-platelet therapy (recurrence occurred 8.9%, one of the lowest rates in the literature) relieves the safety of early surgery for patients on the preoperative anti-platelet therapy without drug cessation or platelet infusion. Patients with a previous history of infarction may need to be closely followed regardless of anti-platelet or anticoagulant therapy (5).

Conclusions

We believe that the presence of pericerebral fluid collections which indicate the presence of a chronic subdural hematoma in the cranial-cerebral imaging investigations, should lead to the advice and guidance of the patients to a neurosurgical therapeutic attitude, prior to the initiation of therapy with

anticoagulant or anti-platelet visa which may worsen the neurological status of the patients through the potential effect of augmentation of the collection by recurrent bleeding and difficult self-limiting of the bleeding.

Correspondence

Prof. Dr. A.V. Ciurea

E-mail: prof.avciurea@gmail.com

References

- Godlewski B, Pawelczyk A, Pawelczyk T, Ceranowicz K, Wojdyn M, Radek M. Retrospective analysis of operative treatment of a series of 100 patients with subdural hematoma. *Neurol Med Chir (Tokyo)*. 2013;53(1):26-33.
- Kolias AG, Chari A, Santarius T, Hutchinson PJ. Chronic subdural haematoma: modern management and emerging therapies. *Nat Rev Neurol*. 2014 Oct;10(10):570-8
- Mulligan P, Raore B, Liu S, Olson JJ. Neurological and functional outcomes of subdural hematoma evacuation in patients over 70 years of age. *J Neurosci Rural Pract*. 2013 Jul;4(3):250-6
- Nayil K, Altaf R, Shoaib Y, Wani A, Laharwal M, Zahoor A. Chronic subdural hematomas: single or double burr hole-results of a randomized study. *Turk Neurosurg*. 2014;24(2):246-8
- Okano A, Oya S, Fujisawa N, Tsuchiya T, Indo M, Nakamura T, Chang HS, Matsui T. Analysis of risk factors for chronic subdural haematoma recurrence after burr hole surgery: optimal management of patients on antiplatelet therapy. *Br J Neurosurg*. 2014 Apr;28(2):204-8.
- Park HR, Lee KS, Shim JJ, Yoon SM, Bae HG, Doh JW. Multiple Densities of the Chronic Subdural Hematoma in CT Scans. *J Korean Neurosurg Soc*. 2013 Jul;54(1):38-41.
- Tabuchi S, Kadowaki M. Chronic subdural hematoma in patients over 90 years old in a super-aged society. *J Clin Med Res*. 2014 Oct;6(5):379-83.
- Teale EA, Iliffe S, Young JB. Subdural haematoma in the elderly. *BMJ*. 2014 Mar 11;348:g1682
- Tseng JH, Tseng MY, Liu AJ, Lin WH, Hu HY, Hsiao SH. Risk factors for chronic subdural hematoma after a minor head injury in the elderly: a population-based study. *Biomed Res Int*. 2014;2014:218646