

## **Nerve sheath tumor, benign neurogenic slow-growing solitary neurilemmoma of the left ulnar nerve: A case and review of literature**

**Andra Elena Martin<sup>1,2</sup>, D. Martin<sup>1,2</sup>, Aurelia Mihaela Sandu<sup>3</sup>,  
Angela Neacsu<sup>3</sup>, Oana Rata<sup>3</sup>, Cristina Gorgan<sup>3</sup>, M.R. Gorgan<sup>3,4</sup>**

<sup>1</sup>PhD student, University of Medicine and Pharmacy “Carol Davila”, Emergency Clinical Hospital “Bagdasar Arseni”, Bucharest

<sup>2</sup>PhD student, University of Medicine and Pharmacy “Carol Davila”, Emergency Clinical Hospital “Bagdasar Arseni”, Bucharest

<sup>3</sup>Clinic of Neurosurgery, Emergency Clinical Hospital “Bagdasar Arseni”, Bucharest

<sup>4</sup>Professor of Neurosurgery, Clinic of Neurosurgery, Emergency Clinical Hospital “Bagdasar Arseni”, University of Medicine and Pharmacy “Carol Davila”, Bucharest

**Abstract:** This paper represent a report of a case with ulnar nerve schwannoma(neurilemmoma), benign neurogenic slow-growing, tumors originating from Schwann cells along the course of a nerve (1) (2) (3). Schwannomas are the most common tumors of the peripheral nerves which occur in the adults (0.8–2%) (5). Usually they progress slowly and so they can remain painless swellings for a few years before other symptoms appear. Most of these lesions could be diagnosed clinically, are mobile in the longitudinal plane along the course of the involved nerve but not in the transverse plane (7). EMG, MRI, and ultrasonography are useful tools in the diagnosis. The definitive treatment of benign peripheral nerve schwannomatosis is complete enucleation of the tumor mass without damaging the intact nerve fascicles followed by confirmatory hystopathological examination (12). We present the case of a 62 years old right hand-dominant female who notice a slow increasing bulge over the inner aspect of her distal volar left forearm superior to the wrist, for a longer period of time not exactly specified; this was tracked and associated by pain, tingling and numbness over inner one and half fingers of her left hand in progress until the presentations. A diagnosis of soft-tissue tumor was presumed clinically. The other investigations were ultrasonography (US), nerve conduction studies (NCSs) such as sensory nerve action potential (SNAP) and compound muscle action potential (CMAP). In this case IRM was suggestive of a benign growth in her left ulnar nerve in the forearm region. Microsurgical techniques were used for ample enucleation of the tumor the distal volar left forearm. Subsequent histopathological examination confirmed the presumed diagnosis of a benign cellular

schwannoma. At her last follow-up one month after surgery, the patient was neurological gradually improving sensory and motor function and she is highly satisfied with the results of surgery.

**Key words:** nerve tumor, schwannoma, ulnar nerve, enucleation

## Introduction

Ulnar nerve is a division of medial cord of brachial plexus with a root value of C8-T1. This nerve passes superficially to the flexor retinaculum and go into the palm of the hand through the Guyon's canal. In the hand, it provides motor (hypothenar, 3rd/4th lumbricals, palmar/dorsal interossei muscles) and sensory (fifth digit and the medial half of the fourth digit) innervations (17).

Nerve sheath tumor originate from the cells of the Schwann sheath and, thus, are also called Schwannomas (neurilemoma), is the most common benign neoplasm of peripheral nerve sheaths, are tumors that can affect any nerve in the body.

Microscopically they are composed of two cell patterns Antoni type A and Antoni type B. They usually arise from a single fascicle within the nerve sheath and grow circumferentially displacing the intact nerve fascicles, are located eccentrically on the nerve root and surrounded by a true capsule consisting the epineurium. Neurofibromas and schwannomas are two benign nerve sheath tumors that commonly occur in adults. Neurofibromas are more common than schwannomas.

Schwannomas affect all the age groups and grow very slowly most often, they are solitary tumors ranging from 1.5 to 3 cm in diameter

and are frequently located in the extremities, with upper extremity account for 12 to 19% and in the lower extremity for 13.5 to 17.5% of all cases (18) (19) (20) (11) (21) (22).

These tumors account for 5% of all soft tissue tumors (23) (24)

The typical clinical presentation triad (mass, positive Tinel's sign and differential motility) is infrequently encountered in daily practice. In most patients the lesion is detected as a painless bulk. Clinically it is extremely difficult to differentiate schwannoma from a neurofibroma, still intraoperative form of the tumor mass, its gross morphological appearances and the subsequent histopathological and immunohistochemical examination can set the diagnosis in almost all the cases.

Preoperative conclusion is sometimes difficult and the tumor may resemble a ganglion when it presents on the volar side near the wrist joint.

The important clinical differentials that are often confused with a benign solitary schwannoma of an extremity include traumatic neuroma, neurofibroma, lipoma, cold abscess muscle hernia, haemangioma and synovial cyst (25) (26) (27)

Magnetic resonance imaging (MRI) is a wanted imaging technique in the diagnosis of tumors of peripheral nervous system. On

imaging scans, benign tumor of peripheral nerve presents as well-defined mass, usually fusiform in shape located within a nerve, isointense to surrounding muscles on T1-weighted images, and hyperintense on T2-weighted images. Neurogenic tumors usually show signal enhancement after intravenous administration of contrast medium (28) (29).

They are typically located on the flexor surfaces of the extremities, and the upper extremities are twice as likely to be involved as the lower limbs. Neurolemmomas are mobile in a plane transverse to the course of the nerve but they show to be immobile in the longitudinal plane. There is a higher incidence in the flexor surface of the upper extremity, since the concentration of nerve fibres is higher over that region (11).

The treatment of choice is extracapsular or intracapsular removal under magnification or under operating microscope (6) (30) (31) (32) (31) (21). Satisfactory surgical outcomes can be achieved without the risk of recurrence. (27) (33)

### Case report

We present the case of a 62 years old right hand-dominant female who noticed a slow increasing bulge over the inner aspect of her distal volar left forearm superior to the wrist level for a longer period of time not exactly specified. She also presents paresthesia in the form of tingling and numbness in the distribution of left ulnar nerve.

There was no history of fever, weight loss or any preceding trauma. She had pain over the left forearm which radiated to the fingers.

On local examination, there was a swelling over the medial aspect of the forearm measuring 2 cm × 2 cm with ill-defined borders. The swelling was firm and tender on deep palpation with free mobility horizontally and restricted mobility vertically. The skin over the swelling was free of signs of inflammation. There was no axillary lymphadenopathy. A positive Tinel sign at the wrist and palm and a Phalen sign were noted. Superficial sensory function impairment (S3/S3+) and motor deficit BMRC (M2+/M3) preoperative were detected.

Clinical examination did not reveal café-au-lait spots, axillary and inguinal freckling, multiple cutaneous neurofibromas, learning disabilities, scoliosis, tibial dysplasia and vasculopathy (34).

A diagnosis of soft-tissue tumor was presumed clinically.

Ultrasonography (US) was made and it revealed an oval lesion, hyperperfused, hypoechoic, with dimensions of 14/10/18 mm, net contoured, along ulnar nerve, with peripheral vascular septa and with mass effect on the ulnar artery.

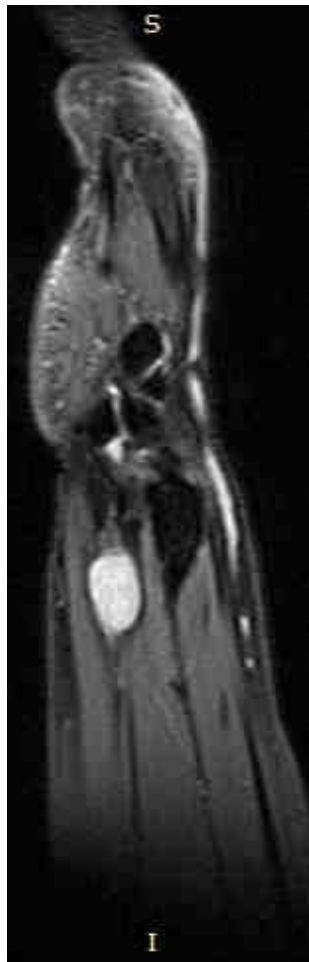Nerve conduction studies (NCSs) were performed:

- sensory nerve action potential (SNAP): conduction slowing with low amplitude on median nerve and absent on ulnar nerve.

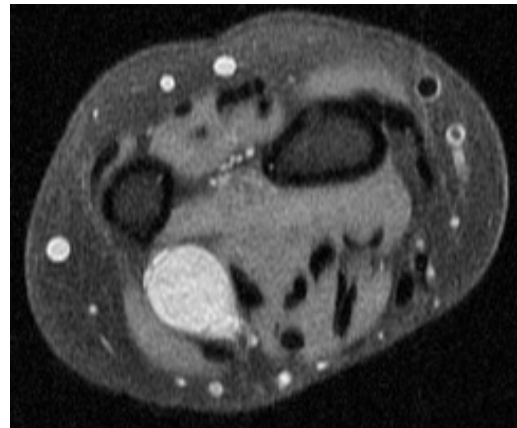
- compound muscle action potential (CMAP): amplitude and distal motor latency is normal in median and ulnar nerve bilateral.

A contrast magnetic resonance imaging (MRI) showed distal volar left forearm, 2.4 cm superior to the wrist, enhancing lesion measuring 1.2/1.9 cm, along ulnar nerve,

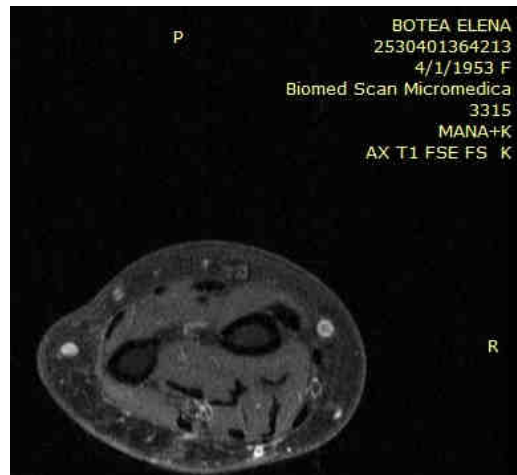between flexor carpi ulnaris muscle and flexor digitorum profundus with intermediate signal on T1-weighted images and hyperintense signal on T2-fat weighted images with the central portion of the lesion hyperintense T2 and hypointense T1. Characteristic “target sign” was also present on MRI. There was no infiltration into surrounding tissues, and there was no perilesional edema on MRI (figure 1, 2, 3).



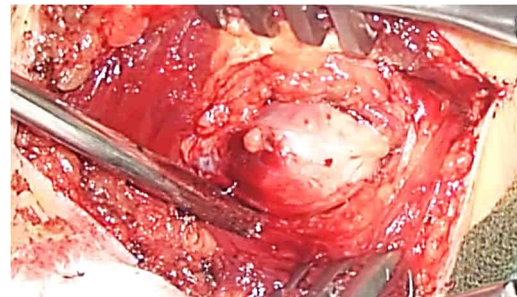
**Figure 1** - MR imaging of the nerve sheath tumor T1 weighted image coronal section: Isointense mass along median nerve



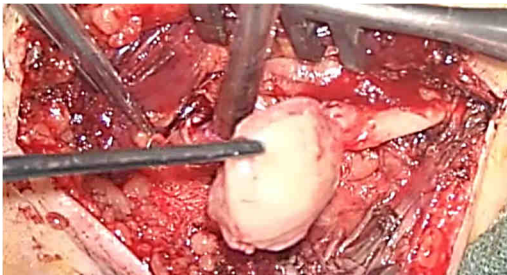
**Figure 2** - MRI imaging of the tumor (axial sections) T2 weighted axial section: hyperintense mass ulnar nerve



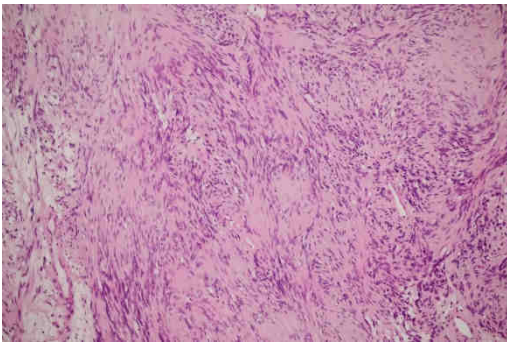
**Figure 3** - MRI imaging of the tumor (axial sections) T1 weighted axial section: hyperintense mass ulnar nerve



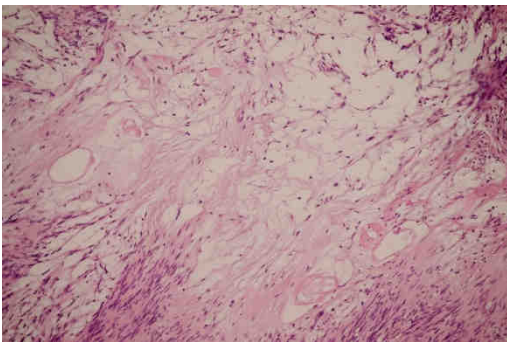
**Figure 4** - Intraoperative view of the ulnar nerve tumor



**Figure 5** - Tumor aspect after enucleation



**Figure 6** - Pathology slide peripheral nerve schwannoma with Antony A cells (the compact array with spindle cells) and palisading cells of Verocay body



**Figure 7** - Pathology image with Antony B cells (less compact array)

A complete surgical enucleation of the tumor mass followed by histopathological analysis was intended.

After general anesthesia being induced and the patient intubated and remain in supine

position, he is given intravenous Ceftriaxone sodium after being tested in advance. The entire left upper extremity is prepped with Betadine all the way to the axilla and draped in a sterile fashion. A sterile tourniquet was placed higher on the arm. The arm is then exsanguinated with Ace bandage and tourniquet inflated to 250 mmHg.

Under the operating microscope with microsurgical techniques the tumor mass was exposed through skin incision centered on the long axis of lesion at the level of the distal volar left forearm. Adequate exposure of the nerve both proximal and distal to the tumor was made. The nerve fascicles stretched over the tumor mass. A surgical plane was developed between the intact nerve fascicles and tumor mass, to expose the actual tumor mass. The complete enucleation of the tumor mass was possible without any obvious structural damage to the intact nerve fascicles.

Was conducted primary repair of the ulnar nerve segment involved after resection of tumor mass with perineural neurorrhaphy establishing the continuity of the Schwann sheath with a minimal number of monofilament 10-0 nylon sutures under the operating microscope.

The wound was then irrigated with normal saline and wound edges were reapproximated with interrupted with interrupted Vicryl subcutaneously and Monocryl to the skin. Meanwhile the patient is awakened and extubated in the operating room and returned to the recovery room in good condition.

Histopathological examination of the masses revealed typical features of benign schwannoma, that showed an encapsulated

hypercellular tumor of pleomorphic spindle cells with tapering nuclear ends, growing in the uniform fascicular pattern with prominent palisading at most places Antoni A pattern and areas Antoni B pattern.

At the last follow-up one month after surgery the patient was neurological gradually improving sensory and motor function and she highly satisfied with the results of surgery.

### Discussion

Schwannomas (neurilemmoma) are neurogenic slow-growing tumors, well-encapsulated which mostly develop as solitary tumors (35) (11) (36) (21).

Microscopically, two kinds of cells have been described namely Antoni A and Antoni B, which are found in archetypal schwannomas (24) (6). The tumor cells are considered to be strongly immunopositive for the S-100 protein (37). The pathological variants of schwannomas include the most common conventional variety followed by, cellular, plexiform and the melanotic schwannoma. Histological conditions that must differentiate from schwannomas include palisaded leiomyoma, palisaded myofibroblastoma of inguinal lymph nodes, gastro-intestinal stromal tumors, plexiform neurofibroma, palisaded encapsulated neuroma, neurotropic melanoma, clear cell sarcoma of soft parts etc. Excluding the conventional variant there is no risk of malignant transformation of schwannomas (25).

Lee SH et al. described that the (31) most frequently affected peripheral nerve in schwannoma is the median nerve (2). The

upper and lower extremity ratio of schwannoma is 2:1 as seen in major series (38) (33).

Commonly schwannomas present as sporadic solitary peripheral nerve mass and, when multiple are usually seen in association with NF2 or schwannomatosis (39).

Typical neurological symptoms of schwannomas are mentioned Tinel sign, numbness, and pain (4). Considered to be uncommon tumors, however they are still the most common primary nerve sheath tumors of the hand and wrist they account for about 5% of all the benign soft-tissue neoplasms because of this rarity they usually carriage a challenge to have correct preoperative diagnosis (40).

Siqueira et al. mentioned in the upper extremity 12 cases of tumor place in ulnar nerve, 12 cases of tumor location in median nerve, and 3 cases of tumor site in radial nerve (41).

Date et al. observed tumors of the upper extremity in descending order of frequency in ulnar, median and radial nerves (31).

In the opinion of Adani et al. the most common sites of tumor origin, in descending order of frequency are: ulnar nerve (14 tumors), median nerve (4 tumors), musculocutaneous nerve (3 tumors), and digital nerves (3 tumors) (11).

Correct clinical history and examination tracked by investigations like ultrasonography, MRI and electromyographic studies may sometimes help in a correct preoperative diagnosis, but this is not the truth in a substantial proportion of cases (42) (43).

The main reason why solitary benign peripheral nerve schwannoma can be

enucleated securely without any structural damage to the nerve trunk is that tumor mass is less intermingled with the normal tissue. Benign solitary schwannomas have first-rate prognosis and unless incompletely excised, there is no risk of recurrence (11).

MRI is considered to be the most important radiological imaging technique for diagnosing the nerve, that can detect the nerve of origin, dimensions, encapsulation, place of the nerve trunk in the tumor mass, perilesional edema, and the distinguishing target sign (28) (44).

Preoperatively the possibility of iatrogenic nerve injury with neurological deficits subsequent must be taken into account and discussed with the patient. Neurological deficits occurred postoperative urging to a careful clinical and imaging examinations are essential (45). An accurate surgical plane is essential to prevent any unwanted injury to the intact nerve fascicles with postoperative neurological deficit (11) (27) (26) (46)

Since schwannomas have an eccentric location, non-infiltrating growth it can often be excised without or with only slight damage to nerve structure (11) (47) (48) (49)

Surgical complication might be the result of a difficult enucleation, the correlation of operative findings with neurological symptoms and surgical complications were not fully discussed. Moreover, numbness goes on with small tumor had the strong impact on and the postoperative neurological deficit. Tumors arising in the extremities or those with a small volume (<4 cm<sup>3</sup>) are correlated with spontaneous pain and Tinel sign and the

location of tumor also might influence the symptomatology (50).

Postoperative neurological problems such as numbness, palsy, and sensory disturbances are severe problems, with a range of 0.05–76.7 % (51) (2) (52). Regarding early postoperative period, Adani et al. mentions worsening of paresthesias in 23 out of 24 patients with schwannomas enrolled in the study (11). It has been established by numerous studies that schwannomas can hardly induce damaged motor function and yet if this happens should always raise a high suspicion of malignancy of that neural tumors (21) (53).

Kang et al. described permanent sensory impairment present in 1 out of 20 patients (54). Knight et al. reports serious postoperative complications in 5 out of 198 treated patients (55).

Outlook of atraumatic tumor enucleation does not eliminate the risk of developing new postoperative neurological deficits, their contributing causes can be varied (56).]. Donner et al support a different opinion, claiming as argument intraoperative stimulation, that fascicles entering the tumor are ordinarily nonfunctional and their transection does not cause additional neurological deficits (57).

Park et al. advocate that 73.2 % of all tumors induce postoperative neurological symptoms and that the symptoms persist in 30 % cases (58).

Whitaker and Drouli as argue that temporary muscle weakness or diminished sensory perception occurs at the time when performing dissecting nerve fibers (59).

Kim et al. reported that extensive tumor growth is a predisposition in determining a higher percentage of postoperative neurological deficits, this being due to the fact that these lesions look to have a higher frequency of fascicular injury during dissection (51).

It is assumed on the basis of the results that schwannoma accompanying numbness correlated with the effort of the enucleation (50). The use of microscope and microsurgical techniques might contribute to facilitate the normal nerve and to avoid the postoperative neurological deficit (60).

Adani et al. in 2008, publish a study that included 24 schwannomas situated in the upper extremity, in 20 cases the authors were able to remove tumors without damage of the fascicular structure (11).

The surgical techniques described in the literature are also controversial.

Extracapsular tumor removal is an operative technique commonly used for removal of neurilemmoma (6) (30) (31) (32). However, Date et al. pick out the intracapsular technique (31) (21)

Hussain et al. underline "tumor release by incising the capsule far lateral to the path of the nerve and dissecting the tumor circumferentially from its capsule. The epineural capsule is then left behind and acts as a protective covering of the nerve" (32).

Regardless the reports of H.J. Kang (54) according to which the majority of schwannomas can be completely enucleated harmless the nerve because the nerve fibers are relocated and do not penetrate the tumor, Chris Yuk Kwan Tang et al. state that a large

amount of the fibers had fascicular involvement. More exactly, 75% of the involved nerve fascicles while 25% schwannoma could be completely enucleated without nerve fascicles involvement (61).

The actual data shows contradictory outcomes regarding the function of nerve fascicles running through the tumor. The study done by Donner et al. (57) indicate that there was no nerve action potential transmission through the tumor nerve fascicles, proposing that division of the affected ones will not induce neurological deficit. However, M. J. Park et al. (56) disclosed that 75% of patients had immediate neurological deficit once the tumor it has been removed.

## Conclusion

Schwannoma (neurilemmoma) located in extremities, a benign neurogenic slow-growing lesions is a rare nerve sheath tumor commonly diagnosed after a histopathological examination of a soft-tissue neoplasm most commonly of the ulnar and median nerves. Tumor enlargement causes amplification of compression on adjacent to nerve structure. Magnetic resonance imaging (MRI) is a wanted imaging technique in the diagnosis of tumors of peripheral nervous system and nerve conduction studies (NCSs): sensory nerve action potential (SNAP), compound muscle action potential (CMAP) can be helpful.

Microsurgical techniques for tumor resection with nerve preservation is the treatment of choice as chance of recurrences is very low, frequently progress in peripheral



nerve function after excision of schwannoma is reached.

The possibility of new permanent or transitional postoperative neurological deficits is low (16).

## References

- Gosk J, Zimmer K, Rutowski R (2004) Peripheral nerve tumors-diagnostic and therapeutical basics. *Folia Neuropathol* 42:31-35.
- Lee SH, Hg Jung, Park YC, Kim HS (2001) Results of neurilemoma treatment: a review of 78 cases. *Orthopaedics* 24:977-980.
- (Rosenberg AE, Dick HM, Botte MJ (1991) Benign and malignant tumors of peripheral nerve. In: Richard H, Gelberman (eds) *Operative nerve repair and reconstruction*, vol 2. JB Lipponcot Company 2, Philadelphia).
- (Zhou J, Man XY, Zheng M, Cai SQ (2012) Multiple plexiform schwannoma of a finger. *Eur J Dermatol* 22:149-150.
- (J. C. Harkin and R. S. Reed :, *Tumors of the Peripheral Nervous System*, Armed Forces Institute of Pathology, Washington, Dc, USA, 1968).
- (Ozdemir O, Ozsoy MH, Kurt C, Coskunol E, Calli I. Schwannomas of the hand and wrist: long term results and review of the literature. *J Ortho Surg (Hong Kong)*. 2005 Dec;13(3):267-72.
- (N. B.White, "Neurilemomas of the extremities," *Journal of Bone and Joint Surgery A*, vol. 49, no. 8, pp. 1605-1610, 1967.
- Rosenberg et al. 1991 ,Oberle et al. 1997; Pivlavaki et al. 2004.
- C. L. Forthman and P. E. Blazar, "Nerve tumors of the hand and upper extremity," *Hand Clinics*, vol. 20,no. 3, pp. 233-242, 2004.
- (D. S. Louis and F. M.Hankin, "Benign nerve tumors of the upper extremity," *Bulletin of the New York Academy of Medicine*, vol. 61,no. 7, pp. 611-620, 1985).
- Adani, A. Baccarani, E. Guidi, and L. Tarallo, "Schwannomas of the upper extremity: diagnosis and treatment," *La Chirurgia Degli Organi di Movimento*, vol. 92, no. 2, pp. 85-88, 2008.
- Ajay Pant, Julfiqar, Najmul Huda, M. Aslam Benign Solitary Schwannoma of Right Ulnar Nerve - A Case Report , *Acta Medica International*, Jan - Jun 2015, Vol 2 | Issue 1.
- A. L. Dellon, "The moving two-point discrimination test: clinical evaluation of the quickly adapting fiber/receptor system," *Journal of Hand Surgery*, vol. 3, no. 5, pp. 474-481, 1978.
- G. E. Omer Jr., "Report of the Committee for evaluation of the clinical results in peripheral nerve injury," *Journal of Hand Surgery*, vol. 8, no. 5, pp. 754-758, 1983.
- H. J. P"azold and K. Henkert, "Operative Behandlung von Verletzungen peripherer Nerven," *Zentralblatt f"ur Chirurgie*, vol. 115, pp. 677-684, 1990.
- Jerzy Gosk, Olga Gutkowska, Maciej Urban, Witold Wnukiewicz, Paweł Reichert, and Piotr Zióbkowski Results of Surgical Treatment of Schwannomas Arising from Extremities , , *BioMed Research International* Volume 2015, Article ID 547926).
- Bekler H, Wolfe VM, Rosenwasser MP. A cadaveric study of ulnar nerve innervation of the medial head of triceps brachii. *Clin Orthop Relat Res*. 2009;467:235-8, Polatsch DB, Melone CP, Jr, Beldner S, Incorvaia A. Ulnar nerve anatomy. *Hand Clin*. 2007;23:283-.
- Kang HJ, Shin SJ, Kang ES. Schwannomas of the upper extremity. *J Hand Surg Br* 2000;25:604-7.
- White NB. Neurilemomas of the extremities. *J Bone Joint Surg Am* 1967;49:1605-10.
- Tang JB, Ishii S, Usui M, Naito T. Multifocal neurilemomas in different nerves of the same upper extremity. *J Hand Surg Am* 1990;15:788-92.
- K. Malizos, M. Ioannou, and V. Kontogeorgakos, "Ancient schwannoma involving the median nerve: a case report and review of the literature," *Strategies in Trauma and Limb Reconstruction*, vol. 8, no. 1, pp. 63-66, 2013.
- M. J. Kransdorf, "Benign soft-tissue tumors in a large referral population: distribution of specific diagnoses by age, sex, and location," *American Journal of Roentgenology*, vol. 164, no. 2, pp.395-402, 1995.
- Mackinnon SE, Dellon AL. *Surgery of peripheral nerve*. New York: Thieme Medical Publishers; 1988: 535-40.); their incidence in the upper extremity varies as does their clinical presentation, Knight DM, Birch R, Pringle J. Benign solitary schwannomas: a review.
- Trăistaru R, Enăchescu V, Manu CD, Gruia C, Ghiluşi M. Multiple right schwannoma. *Rom J Morphol Embryol*. 2008;49(2):235-9.

25. O. Kurtkaya-yacipier, Bscthauer, J.M. Woodruff . The pathological spectrum of schwannomas. *Histol Histopathol* 2003;18:925-934.
26. Ekkernfkamp A, Wol JD, Muller KM, Wiebe V. Myxoid schwannoma of the forearm-a case report. *Handchir Mikrochir plast Chir* 1990 Nov; 22(6):316-20.
27. Di Lorenzo S, Corradino B, Cordova A, Moschella F. Unexpected Ulnar nerve schwannoma. The reasonable risk of misdiagnosis. *Acta Chir Plast* 2007;49(3):77-9.
28. T. Ergun, H. Lakadamyali, A. Derincek, N. C. Tarhan, and A.Ozturk, "Magnetic resonance imaging in the visualization of the benign tumors and tumor-like lesions of hand and wrist," *Current Problems in Diagnostic Radiology*, vol. 39, no. 1, pp. 1–16, 2010.
29. S. K. Thawait, V. Chaudhry, G. K. Thawait et al., "High resolution MR neurography of diffuse peripheral nerve lesions," *The American Journal of Neuroradiology*, vol. 32, no. 8, pp. 1365– 1372, 2011.
30. S. M. Kim, S.W. Seo, J. Y. Lee, and K. S. Sung, "Surgical outcome of Schwannomas arising from major peripheral nerves in the lower limb," *International Orthopaedics*, vol. 36, no. 8, pp. 1721– 1725, 2012.
31. R.Date, K.Muramatsu, K. Ihara, andT.Taguchi, "Advantages of intra-capsular micro-enucleation of schwannoma arising from extremities," *Acta Neurochirurgica*, vol. 154, no. 1, pp. 173–178, 2012.
32. M. A. Hussain, H. Jhattu, A. Pandya, Q. Chan, and W. C. A. Pandya, "A precise excision technique for schwannomas," *European Journal of Plastic Surgery*, vol. 36, no. 2, pp. 111–114, 2013.
33. Tapas K Das Gupta, Richard D Brasfield. Tumours of peripheral nerve origin-benign and malignant solitary schwannomas. *CA-A cancer journal for clinicians*. 1970 20; 4:228-233.
34. JM Friedman, MD, PhD (2014). Neurofibromatosis 1. GeneReviews® . Pagon RA, Adam MP, Ardinger HH, et al., editors.Seattle (WA): University of Washington, Seattle; 1993-2016.
35. Beaman FD, Kransdorf MJ ,Menke DM. Schwannoma: radiologic-pathologic correlation. *Radiographics*. 2004 Sep-Oct; 24(5):1477–81.
36. N. J. S. Kehoe, R. P. Reid, and J. C. Semple, "Solitary benign peripheral nerve tumors," *The Journal of Bone & Joint Surgery B*, vol. 77, no. 3, pp. 497–500, 1995.
37. Karamchandani, Jason R. MD \*; Nielsen, Torsten O. MD, PhD +; van de Rijn, Matt MD, PhD \*; West, Robert B. MD, PhD \*. Sox10 and S100 in the Diagnosis of Soft-tissue Neoplasms . *Applied Immunohistochemistry & Molecular Morphology*.20(5):445-450, October 2012.
38. Nicholas JH Kehoe, Robin P Reid, J Campbell Semple. Solitary benign peripheral nerve tumours-review of 32 years experience. *J Bone Joint Surg [Br]*. 1995;77-B; 3:497-500.
39. Harun Kütahya, 1 ,\* Ali Güleç, 2 Yunus Güzel, 3 Burkay Kacira, 4 and Serdar Toker 5 .Schwannoma of the Median Nerve at the Wrist and Palmar Regions of the Hand: A Rare Case Report. *Case Rep Orthop*. 2013; 2013: 950106.
40. VanHerendael B, Heyman S, Schepper Am, Gielen J, Parizel PM. Schwannoma of left ulnar nerve. *JBR-BTR*. 2006 May-Jun; 89(3):156–7.
41. M. G. Siqueira, M. Socolovsky, R. S. Martins et al., "Surgical treatment of typical peripheral schwannomas: the risk of new postoperative deficits," *Acta Neurochirurgica*, vol. 155, no. 9, pp. 1745–1749, 2013.
42. J. Gosk, K. Zimmer, and R. Rutowski, "Peripheral nerve tumours—diagnostic and therapeutical basics," *Folia Neuropathologica*, vol. 42, no. 1, pp. 31–35, 2004.
43. M. Pilavaki, D. Chourmouzi, A. Kiziridou, A. Skordalaki, T. Zarampoukas, and A. Drevelengas, "Imaging of peripheral nerve sheath tumors with pathologic correlation: pictorial review," *European Journal of Radiology*, vol. 52, no. 3, pp. 229–239, 2004.
44. Koga H, Matsumoto S, Definition of target sign and its use for diagnosis of schwannomas. *Clin Orthop Relat Res* 2007Aug;464:224- 229.
45. Kehoe NJS, Reid RP, Semple JC (1995) Solitary benign peripheral-nerve tumours. Review of 32 years' experience. *J Bone Joint Surg Br* 77:497–500 Kim SM, Sei SW, Lee JY, Sung KS (2012) Surgical outcome of Schwannomas arising from major peripheral nerves in t.
46. Boustany Ashley,McClellan, W. Thomas. Schwannoma of the ulnar nerve: a case report and review of the literature. *West Virginia Medical Journal*. March/April 2012 Vol 108, issue 2; p36.
47. G. M. Rockwell, A.Thoma, and S. Salama, "Schwannoma of the hand and wrist," *Plastic and Reconstructive Surgery*, vol. 111, no. 3, pp. 1227–1232, 2003.
48. G. Jerzy, R. Roman, and R. Jerzy, "Peripheral nerve tumours in own material," *Folia Neuropathologica*, vol. 42, no. 4, pp. 203– 207, 2004.

49. C. Y. K. Tang, B. Fung, M. Fok, and J. Zhu, "Schwannoma in the upper limbs," *BioMed Research International*, vol. 2013, Article ID 167196, 4 pages, 2013.
50. Kensaku Abe, Hiroyuki Tsuchiya (2015) Symptomatic small schwannoma is a risk factor for surgical complications and correlates with difficulty of enucleation. *SpringerPlus* (2015) 4:751 DOI 10.1186/s40064-015-1547-9.
51. Kim SM, Sei SW, Lee JY, Sung KS (2012) Surgical outcome of Schwannomas.
52. Sawada T, Sano M, Ogihara H, Omura T, Miura K, Nagano A (2006) The relationship between preoperative symptoms, operative findings and postoperative complications in schwannomas. *J Hand Surg Br* 31:629-634.
53. A. Ogose, T. Hotta, T. Morita et al., "Tumors of peripheral nerves: correlation of symptoms, clinical signs, imaging features, and histologic diagnosis," *Skeletal Radiology*, vol. 28, no. 4, pp. 183-188, 1999.
54. H. J. Kang, S. J. Shin, and E. S. Kang, "Schwannomas of the upper extremity," *Journal of Hand Surgery*, vol. 25, no. 6, pp. 604-607, 2000.
55. D. M. Knight, R. Birch, and J. Pringle, "Benign solitary schwannomas: a review of 234 cases," *The Journal of Bone & Joint Surgery B*, vol. 89, no. 3, pp. 382-387, 2007.
56. M. J. Park, K. N. Seo, and H. J. Kang, "Neurological deficit after surgical enucleation of schwannomas of the upper limb," *Journal of Bone and Joint Surgery—Series B*, vol. 91, no. 11, pp. 1482-1486, 2009.
57. T. R. Donner, R. M. Voorhies, and D. G. Kline, "Neural sheath tumors of major nerves," *Journal of Neurosurgery*, vol. 81, no. 3, pp. 362-373, 1994.
58. Park MJ, Seo KN, Kang HJ (2009) Neurological deficit after surgical enucleation of schwannomas of the upper limb. *J Bone Joint Surg Br* 91:1482-1486. doi:10.1302/0301-620X.91B11.22519.
59. Whitaker WG, Droulias C (1976) Benign encapsulated neurilemoma: a report of 76 cases. *Am J Surg* 42:675-678.
60. Omezzine SJ, Zaara B, Ben Ali M, Abid F, Sassi N, Hamza HA (2009) A rare cause of non discal sciatica: schwannoma of the sciatic nerve. *Orthop Traumatol Surg Res* 95:543-546. doi:10.1016/j.otsr.2009.05.007.
61. Chris Yuk Kwan Tang, Boris Fung, Margaret Fok, and Janet Zhu. Schwannoma in the Upper Limbs. *BioMed Research International*, Volume 2013, Article ID 167196.