

Traumatic extradural lumbar haematoma due to a pathological metastatic vertebral body fracture L3. Case report and review of the literature

Daniel Balasa¹, Gabriela Butoi², Radu Baz³, Anca Hancu⁴

¹Department of Neurosurgery, Clinical County Hospital, Constanta

²Medimar, Private Radiological Clinic, Constanta

³Pozimed, Private Radiological Clinic, Constanta

⁴Department of Neurology, Clinical County Hospital, Constanta

Abstract: Spinal epidural haematoma (SEH) is a rare entity. We present the case of a 45 years old patient with lumbar epidural hematoma produced by a L3 vertebral tumoral (metastatic) fracture. Neurological status: cauda equina syndrome with sphincterian deficits, incomplete paraplegia (Frankel C), with neurological level L1. Emergency surgery was performed (L3-L2-bilateral laminectomy, L1 left laminectomy, posterior stabilization L2-L4 by titan screws) offering the possibility to progressive motor, sensitive and sphincterian deficits recovery. *Abbreviations:* Computer Tomography -CT, Magnetic resonance Imaging-MRI, Spinal epidural haematoma-SEH, Visual analogue scale of pain-VAS. *Conclusion:* We present a patient with a compressive subacute extradural haematoma, due to a traumatic fracture on a vertebral metastatic tumor who produced cauda equina syndrome. Surgical emergency intervention was mandatory for a good neurological outcome.

Key words: spinal extradural haematoma, pathological vertebral fracture

Introduction

Spinal extradural haematoma (SEH) is a rare pathology and represents an important cause of neural (spinal cord or cauda equina) compression (2). SEH could be produced spontaneously, by spine trauma, iatrogenic (postoperative, by lumbar puncture, epidural anesthesia), spinal epidural malformation,

pregnancy, coagulation abnormalities (2), spinal tumors.

SEH is very rare and represents near 1% from the complication of spine injuries (2) and between 0,3-0,9% of all space-occupying lesions of the spinal canal(12). SEH is complicate with serious morbidity, if the surgical treatment is delayed.

Case report

A 45 years old male patient suffered a car accident with direct spinal lumbar impact. Immediately after the accident he started feeling vertebral pain of high intensity (VAS 9/10) which improved after the use of painkiller drugs and few days of bed rest.

Two weeks after, while the patient was having a sexual intercourse he reported sudden paresthesia, incomplete paraplegia (score Frankel C), progressive loss of sphincter control.

Radiography and MRI scan of the spine revealed an extradural subacute anterior haematoma L1, L2, L4, compressive on the cauda equina, cominutive fracture of a pathological (tumoral) vertebral body of L3. Tumoral lesions where also detected (few mm) within the vertebral bodies of T9, T10, T11, T12, L1, L5 and the first rib, sacrum and iliac wing. The tumors had the aspect of hematogenous metastasis. The patient did not previously use anticoagulant drugs.

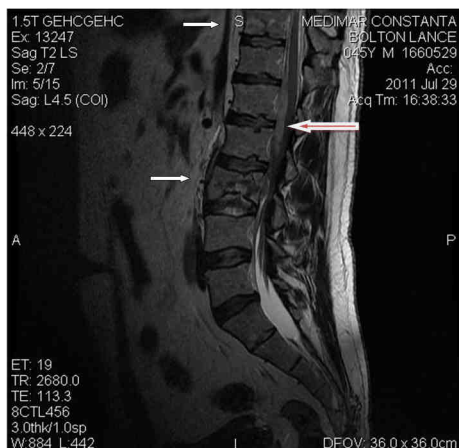

Figure 1 - MRI scan , T2 , sagittal view: 2 vertebral lesions relevant for hematogenous metastasis, in L3

and T11. Heterogenous hyperintensity of the vertebral body L3 (small white arrows), anterior extradural collection L1-L2-L3 with aspect of a subacute haematoma, compressive on the cauda equina - white-red arrow

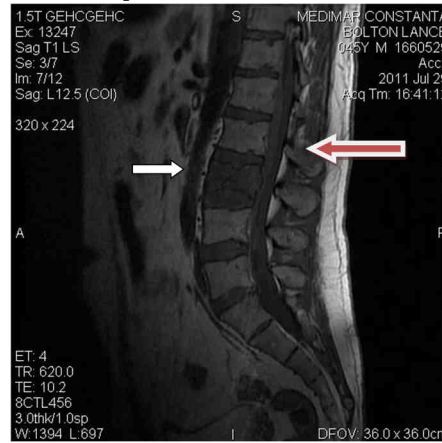

Figure 2 - MRI scan, T1 with gadolinium, sagittal view: Heterogenous hypointensity of the vertebral body L3 (white arrow), anterior extradural collection L1-L2-L3 with aspect of a subacute haematoma, compressive on the cauda equina – white-red arrow

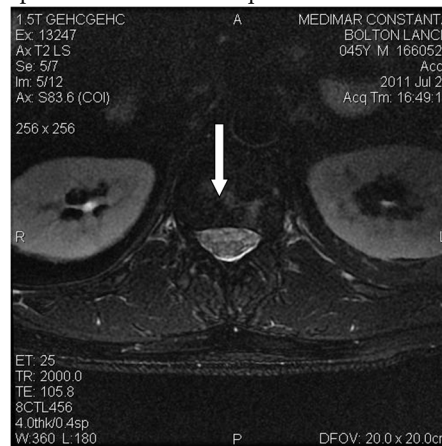


Figure 3. MRI scan , T2 , axial view: L1 extradural anterior heterogenous hyperdense lesion (subacute haematoma) - white arrow -
Emergency surgery was performed (L3, L2 bilateral laminectomy, -L1 left laminectomy, removal of haematoma, vertebral bilateral posterior fusion L2- L4, transpedicular with titanium screws)

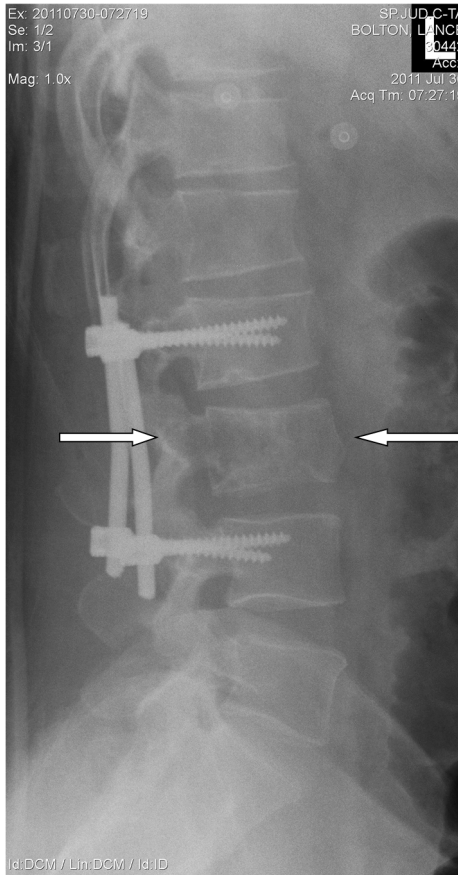


Figure 4 - Posterior transpedicular bilateral rhesisynthesis L4-L2. Pathological aspects can be seen on vertebral body of L3 and the pedicle of L3 (heterogenous aspect hypertransparecies with lythical aspect, cuneiforme fracture of the body L3) - white arrows

Postoperative evolution was favorable. The patient showed progressive motor improvement with normalisation of crural strenght within 2-3 days, paresthasias decreased significantly within the following 6 days. Sphincter control was regained partially, but slower than the motor and sensitive functions.

The patient chose to treat the remaining

tumoral pathology in his native country (USA).

Discussion

The causes of SEH are vertebral fractures, iatrogenic (lumbarpuncture, surgical procedures, epidural anesthesia), bullet injuries, obstetric birth trauma, spinal epidural malformation, spinal tumors. In this case the etiology was spine trauma and spine tumor of the vertebral body of L3 (4).

Spinal EDH can occur throughout the spine but is most common in the cervicothoracic region, usually posterior to the thecal sac over 2-4 vertebral levels (1, 4).

According to Klekamp and Samii (10) 80% of metastasis are located in the vertebral bodies with spinal cord compression from anterior. The spinal cord compression may be increased from vertebral fracture (10) and haematoma as in this case.

Anterior extradural lumbar subacute haematoma secondary to a cominuted pathological (metastatic) vertebral body fracture is an extremely rare case. I didn't find another case in international literature.

MRI is the golden standard for diagnosing the SEH. According to Boukobza (1) the specific signals are isointense in T1 and hyperintense in T2.

The cause of SEH may be considered bleeding from valve less venous plexus in the epidural space, produced by blunt vertebral lumbar trauma (3), in a patient with a cominutive vertebral fracture, with multiple bony vertebral metastasis.

The patient presented in this case report accused intense pain in the vertebral area,

followed in few hours by a cauda equina syndrome.

The golden standard for the patients with symptomatic SEH is rapid decompression, laminectomy (11) and for asymptomatic SEH is corticosteroids and close observation (6, 9)

In this case the emergency was cauda equina syndrome produced by the SEH which imposed emergent decompression (laminectomy) and, due to the associated comminuted fracture metastatic L3, the transpedicular stabilization.

Postoperative outcome is generally favorable with a great percentage of improvement. According to Lawton and co. (12) the percentage of improvement of 30 patients with SEH was 87%. According to Hosono and co. (8), there was a 94% postoperative pain relief, and 81% motor improvement.

In this case the patient had a fast improvement in sensibility and motor strength. The sphincter control improved slower than motility and sensibility.

Correspondence

Daniel Balasa

daniel_balasa@hotmail.com

References

1. Boukobza M, Guichard JP, Boissonet M, George B, Reizine D, Gelbert F, et al. Spinal epidural haematoma: report of 11 cases and review of the literature. *Neuroradiology*. 1994;36(6):456-9
2. Cuenca PJ, Tulley EB, Devita D, Stone A. Delayed traumatic spinal epidural hematoma with spontaneous resolution symptoms. *J Emerg Med*. 2004;27(1):37-41.
3. Foo D, Rossier AB. Preoperative neurological status in predicting surgical outcome of spinal epidural hematomas. *Surg Neurol*. 1981;15(5):389-401.
4. Foo D, Rossier AB. Post-traumatic spinal epidural hematoma. *Neurosurgery*. 1982;11(1 Pt 1):25-32.
5. Fukui MB, Swarnkar AS, Williams RL. *AJNR Am J Neuroradiol*. 1999;20 (7): 1365-72., Acute spontaneous spinal epidural hematomas.
6. Hentschel S, Woolfenden AR, Fairholm DJ. Resolution of spontaneous spinal epidural hematoma without surgery: report of two cases. *Spine*. 2001;26(22):E525-7
7. Hsieh CT1, Chiang YH, Tang CT, Sun JM, Ju DT., *Am J Emerg Med*. 2007 Jan;25(1):69-71., Delayed traumatic thoracic spinal epidural hematoma: a case report and literature review
8. Hosono N, Yonenobu K, Fuji T, Ebara S, Yamashita K, Ono K (1995) Vertebral body replacement with a ceramic prosthesis for metastatic spinal tumors. *Spine* 20:2454-2462
9. Jamjoom ZA. Acute spontaneous spinal epidural hematoma: the influence of magnetic resonance imaging on diagnosis and treatment. *Surg Neurol*. 1996;46(4):345-9
10. Klekamp J, Samii M., *Surgery of spinal tumors*, 2007, 450-481
11. Luciano Miller, Reis Rodrigues, Felipe Abreu, Edison Noboru Fujiki, Carlo Milani, Einstein (São Paulo) vol.8 no.4 São Paulo Oct./Dec. 2010, Delayed traumatic spinal epidural hematoma with neurological deficits
12. Lawton MT, Porter RW, Heiserman JE, Jacobowitz R, Sonntag VK, Dickman CA. Surgical management of spinal epidural hematoma: relationship between surgical timing and neurological outcome. *J Neurosurg*. 1995;83(1):1-7.
13. Robert Z. Tashjian, MD, Michael P. Bradley, MD, Phillip R. Lucas, MD, Brown Medical School, Rhode Island Hospital, Department of Orthopaedic Surgery, 2 Dudley Street, Providence, RI 02905, USA, Spinal epidural hematoma after a pathologic compression fracture: an unusual presentation of multiple myeloma