

## Cystic Trigeminal Schwannoma. Case presentation

**Cherkaoui Mandour, Miloudi Gazzaz, Brahim El Mostarchid**

Department of neurosurgery – military hospital Mohammed V – Rabat – Morocco

**Abstract:** Trigeminal schwannoma is the second commonest intracranial schwannoma; they remain rare. A minority exhibit cystic changes, with even fewer an intracystic fluid level. We report a case of a 45-year-old man, presented with a progressive hearing loss, worsening right-sided facial spasms and facial numbness in the region of the right trigeminal nerve. Neurological examination revealed hypoesthesia in the right facial region and intermittent right-sided hemi-facial spasms, without signs of raised intracranial pressure or involvement of the mixed nerves or neurological deficit. A Magnetic resonance imaging of the brain revealed a cystic mass in the right cerebello-pontine angle with extension forward towards the cavum meckel. The patient was operated by retro sigmoid approach, with a total resection of the tumor.

Intracranial cystic schwannomas constitute an uncommon subset of tumors with a distinct clinico-biological behavior. The presence of fluid–fluid levels within the tumors, although rare, confirms the cystic nature of the neoplasms. Cystic areas are usually secondary to the coalescence of mucinous or microcystic regions in Antoni B tissues. The treatment is surgical in the majority of cases and stereotactic radiosurgery has a clear role for adjuvant treatment of post-surgical recurrence of the tumor or residue.

**Key words:** Cystic, Trigeminal, Schwannoma

### Introduction

Schwannomas are uncommon nerve sheath tumors that may originate from any peripheral, cranial or autonomic nerve of the body with the exception of the olfactory and optic nerve.

Trigeminal schwannoma is the second commonest intracranial schwannoma; they remain rare. A minority exhibit cystic changes, with even fewer an intracystic fluid level (4).

We report a case of this atypical histological presentation.

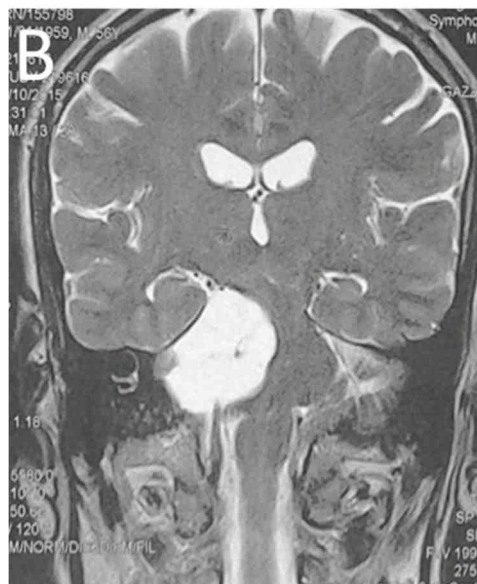
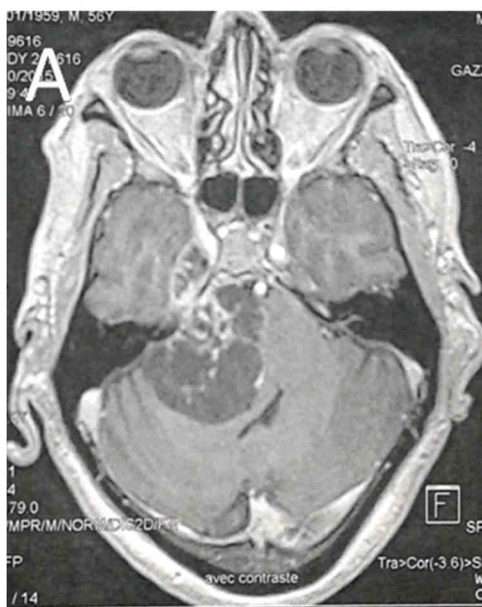
### Case report

A 45-year-old man, presented with a 2 year history of symptoms, of progressive hearing loss, worsening right-sided facial spasms and facial numbness in the region of the right trigeminal nerve. Neurological examination revealed hypoesthesia in the right facial region

and intermittent right sided hemi-facial spasms.

There were no signs of raised intracranial pressure and it did not achieve the mixed nerves or neurological deficit. A Magnetic resonance imaging of the brain revealed a cystic mass in the right cerebello-pontine angle with extension forward towards the cavum meckel (figure: Panel A and B). The patient was operated on lateral position by retro sigmoid approach. The removal of the capsule was easy, after draining the cystic part. He was not of adhesions with vascular and nerve structures of the cerebello-pontine angle. Seen extending into the middle cranial fossa, the exeresis was subtotal.

Post-operative course was favorable with no neurological sequelae and it was indicated radiosurgery for the remaining part. The final histopathology confirmed the diagnosis of a cystic schwannoma.



**Figure: Panel A: Axial B: Coronal:** brain magnetic resonance imaging scan showing a cystic mass of the right cerebellar pontine angle

## Discussion

Schwannomas usually arise from Schwann cells and grow along cranial, peripheral, and autonomic nerves (9). They predominantly stem from sensory nerves rather than motor nerves (2).

Trigeminal schwannomas although rare, are the second commonest intracranial schwannoma (6). Intracranial cystic schwannomas constitute an uncommon subset of tumors with a distinct clinico-biological behavior (4). The presence of fluid-fluid levels within the tumors, although rare, confirms the cystic nature of the neoplasms (5).

Cystic cranial nerve schwannomas are exceptionally uncommon (7). Cystic areas are usually secondary to the coalescence of mucinous or microcystic regions in Antoni B

tissues of the schwannoma. Speculative mechanisms include an insufficient vascular supply resulting in necrosis and cystic changes, hemorrhage into the tumor with blood resorption causing cyst formation, and hyaline degeneration leading to cyst formation (8, 10).

The treatment is surgical to avoid progressive neurological deficits and the need to have a histological diagnosis. Stereotactic radiosurgery (SRS) has a clear role for adjuvant treatment of post-surgical recurrence of the tumor or residue (3). In addition, some advocate SRS as a primary treatment modality for tumors less than 15 cm (1, 3).

### Conclusion

Schwannoma of the trigeminal nerve is a benign tumor but dangerous by its topography and its relationship to vascular and nerve elements. We need to include cystic schwannoma in the list of differential diagnosis of cystic masses of the cerebello-pontine angle.

### Correspondence

*Cherkaoui Mandour*

*E-mail: mandour1978@hotmail.com*

*Telephone: 212 06 45 76 34 23*

*Miloudi Gazzaz*

*E-mail: gazzaznch@hotmail.com*

*Telephone: 212 06 40 46 34 20*

*Brahim El Mostarchid*

*E-mail: elmostarchidnch@hotmail.com*

*Telephone: 212 06 48 34 89 45*

### References

1. Vikas Acharya, Adam Williams, William Adams, David Hilton, Peter C Whitfi eld. Middle cranial fossa cystic schwannoma. *BMJ Case Reports* 2012;10.1136.
2. G. S. Carroll, B. G. Haik, J. C. Fleming, R. A. Weiss, and M. F. Mafee, "Peripheral nerve tumors of the orbit. *Radiologic Clinics of North America*. 1999;37, 1,195–202,.
3. Yasuhiko Hayashi, Takuya Watanabe, Daisuke Kita, Yutaka Hayashi, Masayuki Takahira, and Jun-ichiro Hamada. Orbital Cystic Schwannoma Originating from the Frontal Nerve. *Case Reports in Ophthalmological Medicine*. 2012, Article ID 604574, 4 pages.
4. Colreavy MP, Lacy PD, Hughes J, et al. Head and neck schwannomas—a 10 year review. *J Laryngol Otol*. 2000; 114 : 119 – 24 .
5. H. Kato, et al. Fluid-Fluid Level Formation: A Rare Finding of Extracranial Head and Neck Schwannomas. *AJNR Am J Neuroradiol* 2009 0: ajnr.A1511.
6. Hasegawa T, Kida Y, Yoshimoto M, et al. Trigeminal schwannomas: results of gamma knife surgery in 37 cases. *J Neurosurg* 2007; 106 : 18 – 23 .
7. K. Gündüz, R. A. Kurt, and E. Erden, "Orbital schwannoma with fluid-fluid levels on MRI, *Ophthalmic Plastic & Reconstructive Surgery*, 2011; 27, 3, pp. 51–54.
8. N. Pushker, R. Meel, S. Sharma, M. S. Bajaj, S. Kashyap, and S. Sen, "Giant orbital schwannoma with fluid-fluid levels, *British Journal of Ophthalmology*, 2011; 95, 8, pp. 1180–1181.
9. Fundová P, Charabi S, Tos M, et al. Cystic vestibular schwannoma: surgical outcome. *J Laryngol Otol* 2000 ; 114 : 935 – 9.
10. MacNally SP, Rutherford SA, Ramsden RT, et al. Trigeminal schwannomas. *Br J Neurosurg* 2008 ; 22 : 729 – 38.