

Article

# Isolated traumatic intraventricular hemorrhage in adult with good prognosis

S.V. Rege, Harshad Patil  
INDIA



DOI: 10.1515/romneu-2016-0081

## Isolated traumatic intraventricular hemorrhage in adult with good prognosis

S.V. Rege<sup>1</sup>, Harshad Patil<sup>2</sup>

Department of Neurosurgery, Sri Aurobindo Medical College and PG Institute, Indore, Madhya Pradesh, INDIA

<sup>1</sup>Professor & Head of Department; <sup>2</sup>Senior resident

**Abstract:** Isolated intraventricular hemorrhage of traumatic origin (tIVH) is a rare finding. Mostly found in paediatric age group and rarely reported in adults. Intraventricular hemorrhage is associated with poor outcome. Despite of this, our patient recovered well. We have herein presented a rare case of isolated tIVH in an adult.

**Key words:** traumatic intraventricular hemorrhage, severe head injury, adult

### Introduction

Traumatic intraventricular hemorrhage (tIVH) is usually associated with other lesions such as intracerebral contusion or hemorrhage, subarachnoid hemorrhage, and diffuse brain edema. The presence of IVH indicates that a severe force has been applied to the head and generally is a sign of severe head injury and has a poor prognosis. The incidence of IVH in nonpenetrating head injury is 1.5 to 3% and 10 to 25% of patients with severe head injury (GCS less than 8). (1)

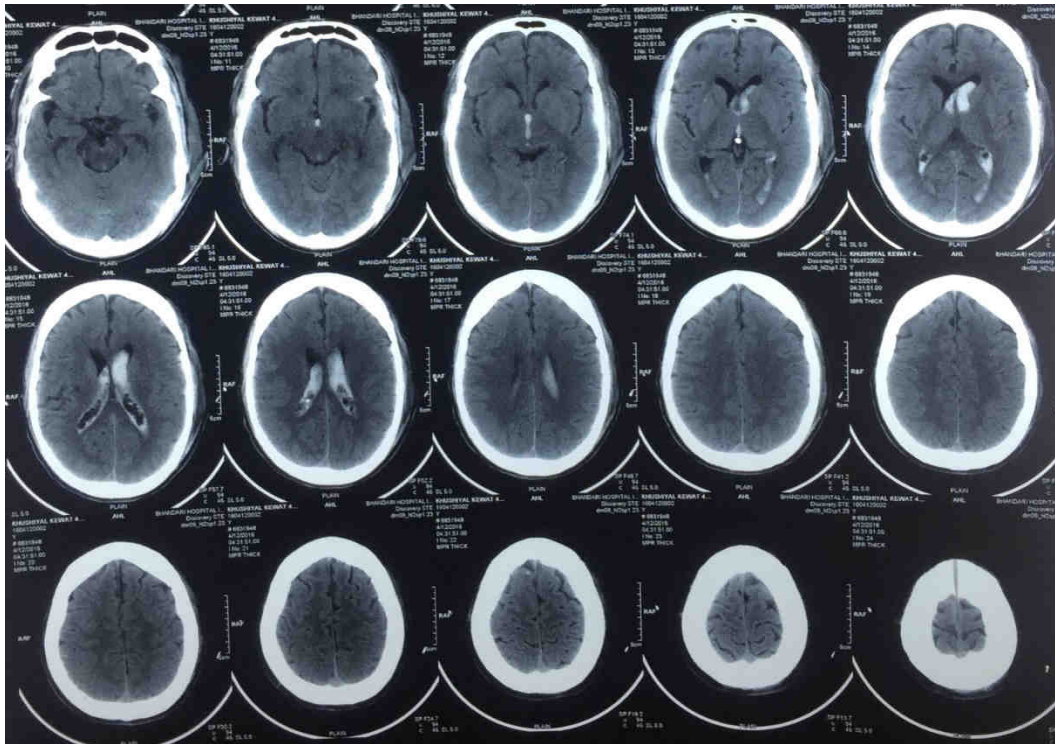
Isolated traumatic intraventricular hemorrhage (tIVH) is a rare finding. It commonly found in paediatric population but rarely reported in adults. Herein author reported a rare case of isolated tIVH in adult.

### Case Report

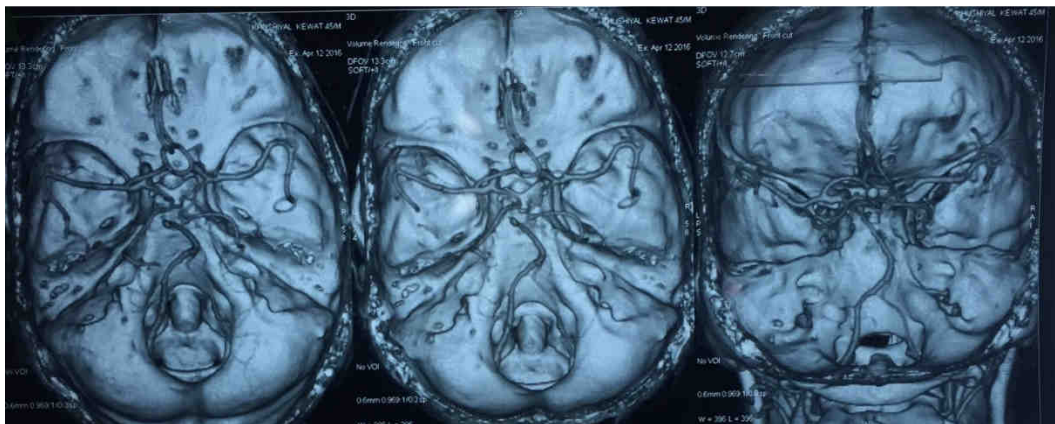
A 60 years old male admitted in neurosurgery department after road traffic accident. He had history of loss of consciousness for 30 minutes with vomiting 2 episodes. At the time of admission his Glasgow Coma Score (GCS) was E2 M4 V2 and his pupils were miotic and sluggishly reacting to light. There was no neurological deficit. On the day of admission patient developed seizure. Patient was intubated, antiedema and anticonvulsant drugs were started. Computed tomography (CT) on admission showed an isolated hemorrhage in the lateral ventricles and third ventricle without hydrocephalus (figure 1). CT angiography was performed in order to rule out any vascular pathology. There were no vascular or tumoral lesion was found (Figure 2).

The follow-up CT scans showed a progressive improvement of the tIVH (figure 3) and ten days after his admission, patient was

extubated and returned to the ward. The patient was discharged from the hospital three weeks after his admission with GCS of 15.



**Figure 1** - CT Brain showing an isolated hemorrhage in the lateral ventricles and third ventricle without hydrocephalus



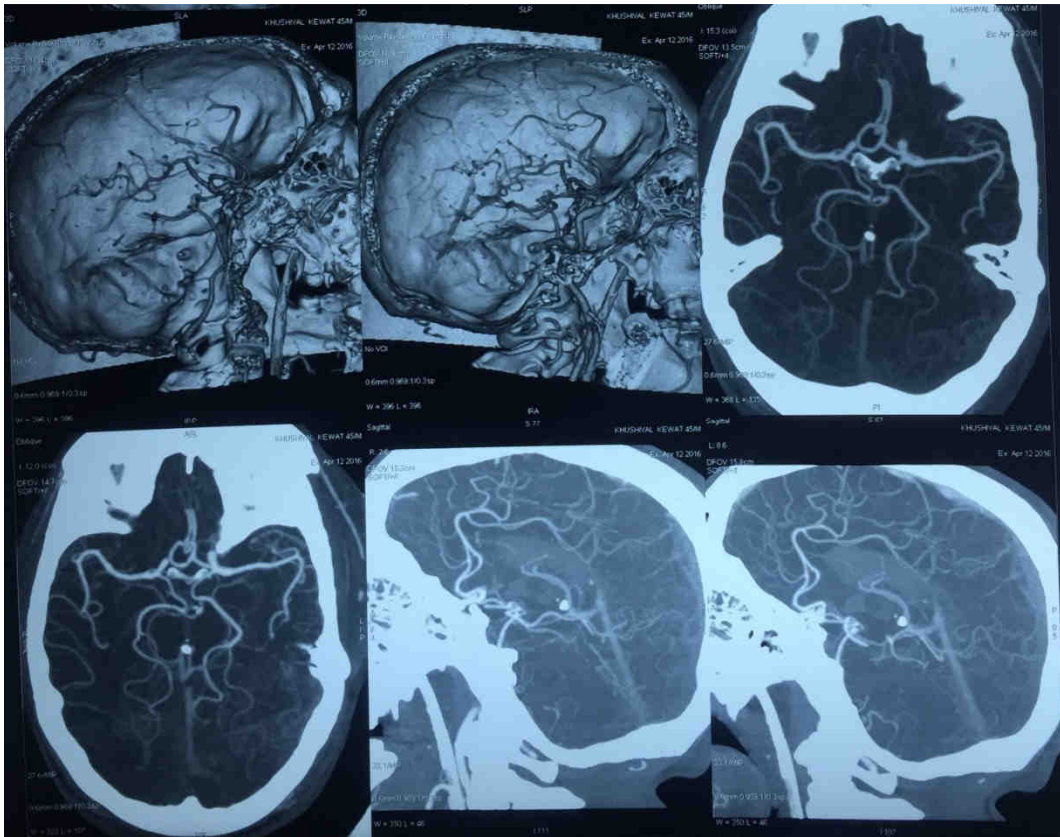
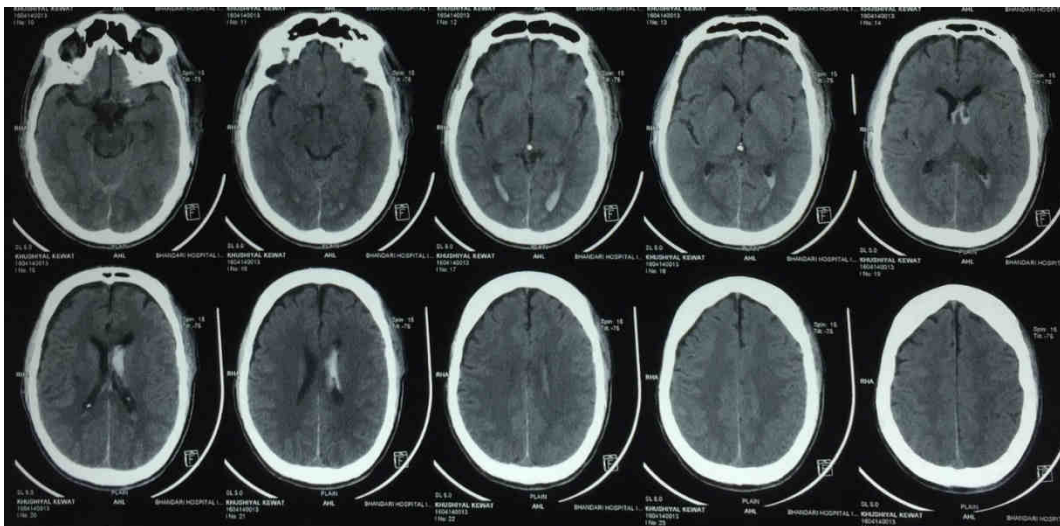
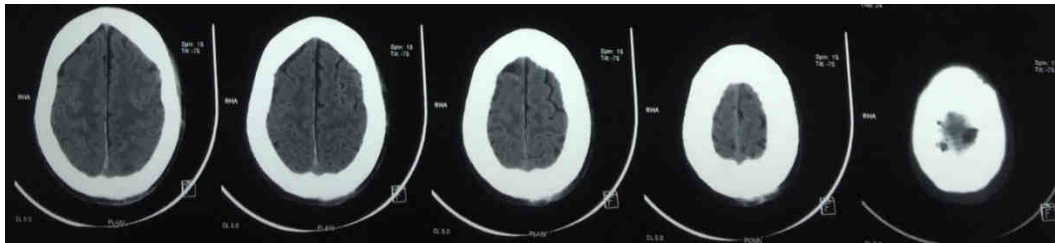

Figure 2 - Normal CT angiogram





**Figure 3** - Follow up CT scan showing resolution of bleed

## Discussion

Isolated tIVH is extremely rare, and its outcome is unclear. The prevalence of tIVH ranges from 0.4 to 4% in all head trauma patients who undergo CT scanning. (1) The presence of IVH indicates that a severe force has been applied to the head and generally is a sign of severe head injury.

In evaluating intraventricular hemorrhage other causes such as hypertensive intracerebral hemorrhage extending to the ventricles, rupture of the intracranial aneurysms, and vascular malformation, systemic bleeding tendencies and neonatal germinal matrix hemorrhage should be considered and differentiated from pure traumatic IVH. In the absence of intraparenchymal hemorrhage IVH is most often caused by tearing of the subependymal veins in the fornix, septum pellucidum or choroid plexus found in autopsy studies. (2, 3) In our patient there were no co-morbid conditions presents so the probable cause of isolated tIVH may be due to tearing of the subependymal veins.

Due to deficient fibrinolysis and hemolysis of CSF the spontaneous resolution of IVH is very slow. Current treatment modalities include external ventricular drainage and more recently the controversial administration of fibrinolytics such as tissue plasminogen activators. Although both

treatments can expedite the clearance of IVH but no conclusion can be drawn from the effect on clinical outcome. (4)

Seizures are well known complications of any kind of intracranial lesions including tIVH. Antiepileptic medications should be started because an epileptic fit might cause the deterioration of the patient. Prophylaxis is also used in trauma patients who have hemorrhagic lesions because of the irritating effect of the blood. (5)

Atzema et al. reviewed 8,374 patients with blunt head trauma and the prevalence of tIVH was 1.41% among all trauma patients. In this study among tIVH patients, 70% had a "poor outcome" and 76% had a "combined outcome." The authors concluded that the prognosis of tIVH was determined by associated brain injuries, rather than by the tIVH itself. (1)

Lee JP et al studied 25 patients of acute post-traumatic intraventricular hemorrhage (IVH) after closed head injury. In this series 6 patients were of isolated tIVH and aurther found good outcome in isolated tIVH. (6)

Is M. et al reported isolated tIVH in paediatric patient with good prognosis. (7) We reported isolated tIVH in adult with good outcome.

The exact cause of poor prognosis in these patients is not known. It can be due to the presence of blood in the ventricle, due to

induced hydrocephalus or increased intracranial pressure. (8) In our patient antiepileptic and antiedema drugs were given and our patient recovered well.

### **Conclusion**

Isolated tIVH is extremely rare and its outcome is unclear. Although our patient was admitted with a low GCS, he had a good clinical outcome without requiring any surgical intervention. Therefore the motto of treatment in such patients is “one should treat the patient not the radiological investigations”.

### **Correspondence**

*Dr. Harshad Patil*

*Address: Department of Neurosurgery,  
Sri Aurobindo medical College and PG Institute,  
Indore, Madhya Pradesh, India  
Email: dr.harshadpatil@gmail.com  
Phone: +919893894242*

### **References**

1. Atzema C, Mower WR, Hoffman JR, Holmes JF, Killian AJ, Wolfson AB: National Emergency X-Radiography Utilization Study (NEXUS) II Group: Prevalence and prognosis of traumatic intraventricular hemorrhage in patients with blunt head trauma. *J Trauma* 60: 1010-1017, 2006
2. Karavelis A, Sirmos C: Primary post-traumatic intraventricular hemorrhage. *J Neurosurg Sci* 39: 253-256, 1995.
3. Hashimoto T, Nakamura N, Ke R, Ra F. [Traumatic intraventricular hemorrhage in severe head injury]. *No Shinkei Geka*. 1992 Mar;20(3):209-15.
4. Machdonald, R Louch MD. PhD: Thrombolysis for intraventricular hemorrhage. *Neurosurgery Quarterly* 15 (4): 211-222, Dec 2005.
5. Brain Trauma Foundation: Guidelines for the management of severe traumatic brain injury 3rd edn. *Journal of Neurotrauma* 24 (Suppl 1):S1-S106, 2007
6. Lee JP, Lui TN, Chang CN. Acute post-traumatic intraventricular hemorrhage analysis of 25 patients with emphasis on final outcome. *Acta Neurol Scand*. 1991 Aug;84(2):85-90.
7. Is M, Gezen F, Akgul M, Dosoglu M. Traumatic intraventricular hemorrhage with a good prognosis. *Turk Neurosurg*. 2011 Jan;21(1):107-9.
8. LeRoux PD, Haglund MM, Newell DW, Grady MS, Winn HR: Intraventricular hemorrhage in blunt head trauma: an analysis of 43 cases. *Neurosurgery* 31(4): 678-84; discussion 684-5, Oct 1992.