

Article

Conus medullaris dermoid tumour. Uncommon presentation of conus medullaris dermoid as an exophytic mass lesion

Guru Dutta Satyarthee, Ashwini Kumar, Luis Rafael Moscote-Salazar
INDIA, COLOMBIA



Conus medullaris dermoid tumour. Uncommon presentation of conus medullaris dermoid as an exophytic mass lesion

Guru Dutta Satyarthee¹, Ashwini Kumar¹, Luis Rafael Moscote-Salazar²

¹Department of Neurosurgery, Neurosciences Centre, AIIMS New Delhi, INDIA

²Neurosurgeon-Critical Care, RED LATINO, Latin American Trauma & Intensive Neuro-Care Organization, Bogota, COLOMBIA

Abstract: Authors report an extremely uncommon case dorsally exophytic conus dermoid in a three- years old boy, who underwent meningocele repair locate at lumbosacral region at an age of one month. The boy presented with low backache and difficulty in passing urine. Magnetic resonance imaging evaluation of spine revealed presence of a large exophytic mass located dorsally in the conus and the features suggestive of dermoid. He underwent surgical intervention during surgery lesion was dorsally exophytic containing cheesy material with hairs, excision of dermoid along capsule was carried our successfully. Pertinent literature and management of exophytic conus dermoid is discussed briefly.

Key words: Conus dermoid, barrel gun like mass, conus mass, exophytic, signet ring

Introduction

Dermoid represent the rare midline tumors and constitute about 1-2% of the spinal tumors [1]. Dermoid are thought to arise from ectopic ectodermal tissue inclusion during embryonic CNS development [2]. Dermoids are usually extramedullary tumors and mostly occurs during the first and second decade of life. The most common location for spinal dermoid is conus medullaris. Our case is rare as the dermoid was intramedullary and had exophytic growth.

The lumbosacral region spina bifida may be associated with intradural spinal dermoid

tumours. However exophytic dermoid is very uncommon occurrence.

Was present, the patient was operated and the intra op findings were consistent with dermoid. Histopathological examination confirmed the diagnosis.

Case Illustration

A-3-year - boy, delivered at term of non-consanguinous marriage presented with history of insidious onset slowly progressive low backache and difficulty in micturition with progressive paraparesis of lower limbs. Significant history include surgery for

lumbosacral meningocele at age of two months. On examination the patient was conscious and alert with grade one power in both lower limbs. A graded sensory loss below umbilicus. Presence of transverse scar at lower lumbar region of previous surgery was present. He had no past history of trauma or meningitis. Signs were present MRI of dorsolumbar spine revealed presence of a single large exophytic mass located dorsally at L1-L3 level (figure 1) and cauda equina roots were pushed anteriorly and existing nerve root exiting ventral to the conus mass lesion large dorsally helophytic tumor in the conus). And the features suggestive of dermoid, showing hypointense signal on T1 weighted image (figure 2 and hyperintense signal on T2 weighted image (figure 3), sagittal section image showing the tumour.

He underwent D12 to fourth lumbar vertebral level re-exploration of wound, after lamina removal, bulging dura was observed. midline durotomy was done (figure 4). A large cyst like gun barrel was seen, pushing cauda equina nerve roots anteriorly along spinal cord. A midline myelotomy was made and dermoid cyst decompression started and complete removal was carried out. Filum terminate was also divide, dermoid tumour was removed; It consisted of hair interspersed in the cheesy material. The cyst wall was thin. Histopathological examination of the resected specimen revealed typical feature of dermoid. Postoperative period was uneventful. At the last follow-up after three month following surgery, with improvement of power in lower limbs was noticed, he was playing and attending school.

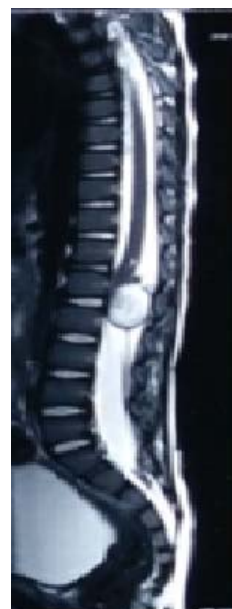

Figure 1 - Magnetic resonance imaging T2 weighted dorsolumbar spine, sagittal section image showing large hyperintense intramedullary conus lesion like gun barrel appearance

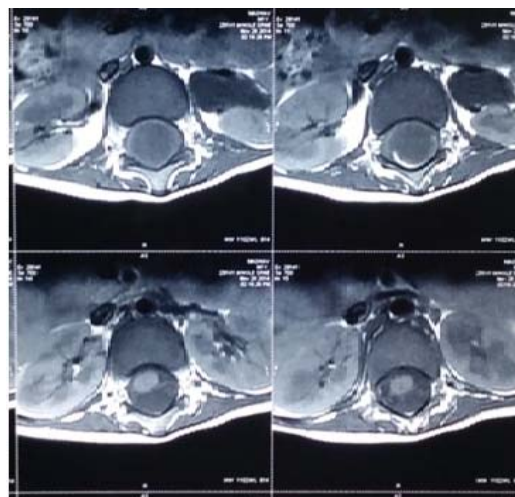


Figure 2 - Magnetic resonance T1 weighted dorsolumbar spine, axial section image of three-year-boy showing large hyperintense intramedullary conus lesion like signet ring appearance

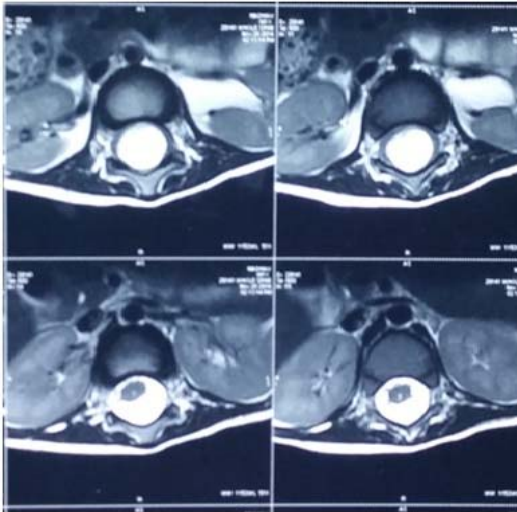


Figure 3 - Magnetic resonance imaging T2 weighted dorsolumbar spine, axial section image showing large hyperintense intramedullary conus lesion like signet ring appearance

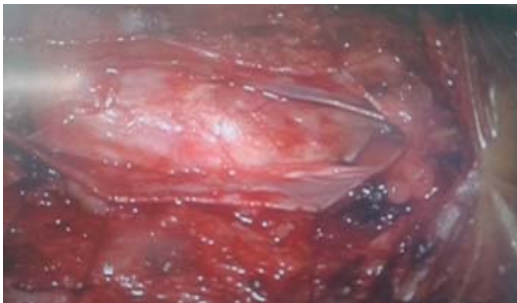

Figure 4 - Intraoperative photograph showing conus dermoid after dural opening

Discussion

Dermoid are the midline tumors can occur anywhere along neurospinal axis. Dermoid can be congenital as well as acquired in origin. They account for about 1.1% of the spinal tumors [3]. They are slowly growing tumor and usually present in second decade of life [4]. Mostly these tumors are intra spinal and rarely occur

intramedullary.

Dermoid represent the rare midline tumors and constitute about 1-2% of the spinal tumors [1]. Intracranial dermoid cysts are uncommon, it accounts for about 0.1 to 0.7 % of all intracranial tumours [5]. The intracranial dermoid cyst arises from ectoderm, probably derived from cell nest included during the closure of neural tube. The cyst wall is lined with stratified squamous epithelium and mixed appendages of ectodermal origin including sebaceous gland, sweat gland, and hair follicles. The cyst content is mixture of decomposed epithelial cells containing keratin, glandular secretion, lipid metabolites, and cholesterol. Rarely dental enamels are also observed [7]. Dermoid cysts are found in supratentorial and infratentorial compartment and within the spinal canal [8]. The commonest location of intracranial dermoid cyst is posterior fossa. The more common supratentorial tumours are located on skull base, frontal or temporal or suprasellar region. It can present at any age, but most common at 2nd and 3rd decades, of life.

The clinical symptomatology is variable rarely it may be detected incidentally [9]. However, most patients presents with seizure, longstanding headache [7], [8]. It may present with cyst rupture, meningiomas, vasospasm, increased intracranial pressure, dementia and possible focal neurological deficits. Death can be consequence of rupture of dermoid cyst [8]. Intracranial dermoid cyst can be associated with complete or incomplete sinus tract, usually ending in an intracranial location of dermoid [6]. Patient may even present with repeated episodes of meningitis

or cerebellar abscess [5].

X-ray of spine may show widening of spinal canal with thinning of lamina. Calcification and rarely fat-fluid level. A spinal computed tomography may show associated bone defect, spina bifida, vertebral body abnormality or associated bony spur. However, CT scan is usually not advised unless a suspicion of co-existing bony spur is suspected. The MRI spine clearly delineates soft tissue with size shape, relation to conus, shift of spinal cord and cauda equina nerve roots and thickening of filum terminale or lipoma, calcification if present have shell like appearance. The management of this associated pathology should be based on pathology causing neurological deficit [10] [11] [12] [13] [14]

Conclusion

The patient presenting with cervical spine fusion anomaly, the imaging of posterior fossa is advised to exclude congenital posterior cranial fossa dermoid cyst and associated congenital craniovertebral junction anomaly. The aim of surgery should be directed to pathology, which is symptomatic. However, the surgical management has to be tailored for individual patient.

Correspondence

Guru Dutta Satyarthee,

E-mail: drguruduttaaiims@gmail.com

References

- Rapoport RJ, Flanders AE, Tartaglino LM. Intradural extramedullary causes of myelopathy. *Semin Ultrasound CT MR* 1994; 15(3):189-225.
- Netsky MG. Epidermoid tumors. Review of the literature. *Surg Neurol* 1988; 29:477-83.
- Lunardi P, Missori P, Gagliardi FM, Fortuna A. Long-term results of the surgical treatment of spinal dermoid and epidermoid tumors. *Neurosurgery* 1989; 25:860-4.
- Egelhoff JC. Pediatric head and neck imaging. In: Haaga JR, editor. *CT and MR imaging of the whole body*. 4th ed. London: Mosby; 2003. p.696.
- Diekmann-Guiroy B, Huang PS. Kippel-Feil syndrome in association with a craniocervical dermoid cyst presenting as aseptic meningitis in adult: A case report. *Neurosurg* 1989; 25: 625-655.
- Schijman E, Monges J, Craganz R. Congenital dermal sinuses, dermoid and epidermoid cysts of the posterior fossa. *Child's Nerv Syst* 1986; 2: 83-89.
- Smith AS, Benson JE, Blaser SI, Mizushima A, Tarr RW, Balon EM. Diagnosis of ruptured intracranial dermoid cyst: Value of MRI over CT. *AJNR* 199; 12: 175-180.
- Lunardi P, Missori P. Supratentorial dermoid cysts. *J Neurosurg* 1991; 75: 262-266.
- Hamer J. Diagnosis by computerized tomography of intradural dermoid with spontaneous rupture of dermoid cyst. *Acta Neurochir* 1980; 51; 219-226.
- Sivrioglu AK, Kara K, Tutar S, Sönmez G. Pedicle thinning finding on X-ray imaging of the lumbar spine: a case of spinal conus dermoid cyst. *Spine J*. 2016 Jun;16(6):e395-6.
- Sharma M, Mally R, Velho V. Ruptured conus medullaris dermoid cyst with fat droplets in the central canal [corrected]. *Asian Spine J*. 2013 Mar;7(1):50-4
- De Maio PN, Mikulis DJ, Kiehl TR, Guha A. AIRP best cases in radiologic-pathologic correlation: Spinal conus dermoid cyst with lipid dissemination. *Radiographics*. 2012; 32(4):1215-21.
- Liu H, Zhang JN, Zhu T. Microsurgical treatment of spinal epidermoid and dermoid cysts in the lumbosacral region. *J Clin Neurosci*. 2012;19(5):712-7.
- Klekamp J. Tethered cord syndrome in adults. *J Neurosurg Spine*. 2011 Sep; 15(3):258-70.
- Falavigna A, Righesso O, Teles AR. Concomitant dermoid cysts of conus medullaris and cauda equina. *Arq Neuropsiquiatr*. 2009; 67(2A):293-6.
- Tufan K, Cekinmez M, Sener L, Erdogan B. Infected lumbar dermoid cyst presenting with tetra paresis secondary to holocord central lesion. *J Child Neurol*. 2008 Aug; 23(8):934-7.
- Muthukumar N, Srisaravanan J. Intramedullary dermoid in a low lying conus tethered by a fatty filum - embryological implications. *Acta Neurochir (Wien)*. 2007 Nov;149(11):1173-