

Article

# Microsurgical clipping of giant thrombosed aneurysm

A. Chiriac, Georgiana Ion, Z. Faiyad, I. Poată  
ROMANIA



DE GRUYTER  
OPEN

## Microsurgical clipping of giant thrombosed aneurysm

A. Chiriac, Georgiana Ion<sup>1</sup>, Z. Faiyad<sup>1</sup>, I. Poată

“Gr. T. Popa” University of Medicine and Pharmacy, Iași, ROMANIA

<sup>1</sup>“Prof. Dr. N. Oblu” Clinic Emergency Hospital, Iași, ROMANIA

**Abstract:** Treatment of giant thrombosed aneurysm is still a challenge for most of neurosurgeons. We present our experience of a patient with a thrombosed giant middle cerebral artery aneurysm manifesting as headache that developed over a 15-year period. Magnetic resonance (MR), computed tomographic angiography (CTA), and digital subtraction angiography (DSA) have clarified the vascular lesion and directed the therapeutic protocol. An open craniotomy with direct clipping and thrombectomy was performed successfully with an uneventful postoperative course.

**Key words:** giant thrombosed aneurysm, direct clipping

### Introduction

Intracranial giant thrombosed aneurysms have been described as a rare subgroup of large aneurysms characterized by a partial or total filling of thrombus in the sac. Giant thrombosed aneurysms are still considered among the most difficult and technically challenging cerebrovascular lesions. Due to the presence of a large thrombus with calcification in aneurismal sac, these lesions may create a mass effect, intracranial nerve compression or a source of emboli. Complete aneurysm obliteration by direct clipping with or without thrombus resection was considered most of time the ideal treatment for such complex aneurysms. However, as the microsurgical or endovascular techniques have evolved, neurosurgeons are now given alternative treatment options to treat these lesions. We experienced an interesting case of

giant thrombosed aneurysm which was treated by direct clipping with partial thrombus resection by CUSA fragmentation.

### Case Report

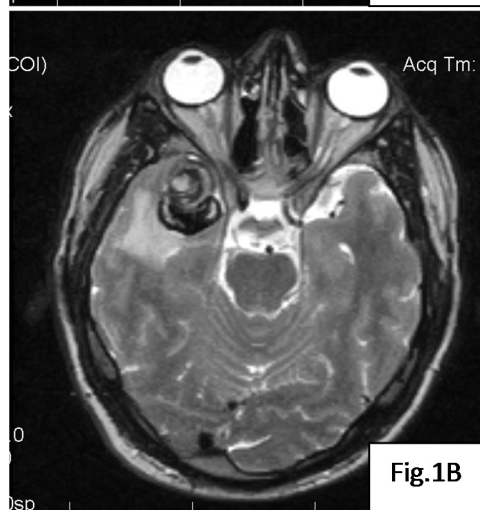
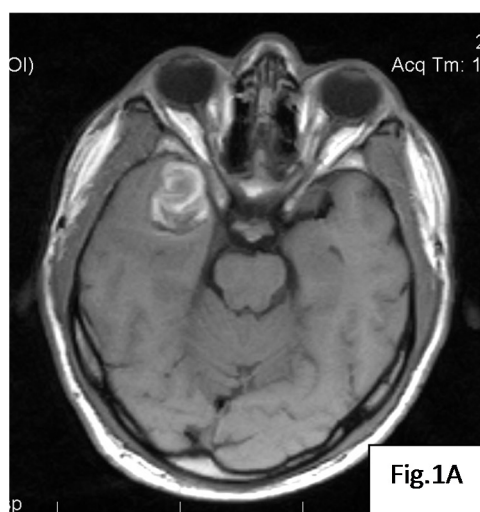
A 43-year-old man presented with headache from one week. He had a history of meningitis, 15 years previously, followed by intermittent episodes of headache. Magnetic resonance (MR) imaging performed at admission revealed a round mass of 3 cm diameter in the right temporal lobe appearing as mixed signal intensity with increased perifocal edema (Figure 1 A, B). Computed tomographic angiography (CTA) identified an aneurysm of the right MCA and one small associated aneurysm at the left MCA bifurcation (Fig.2). Three-dimensional CTA confirmed these findings and showed an aneurysm with a larger external diameter than

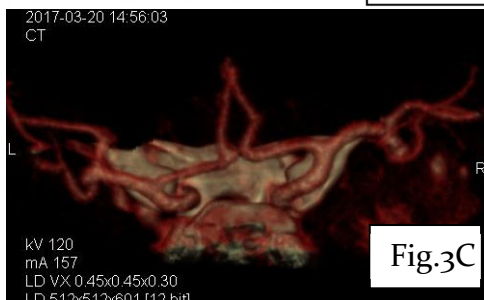
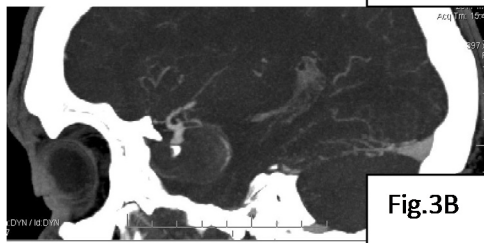
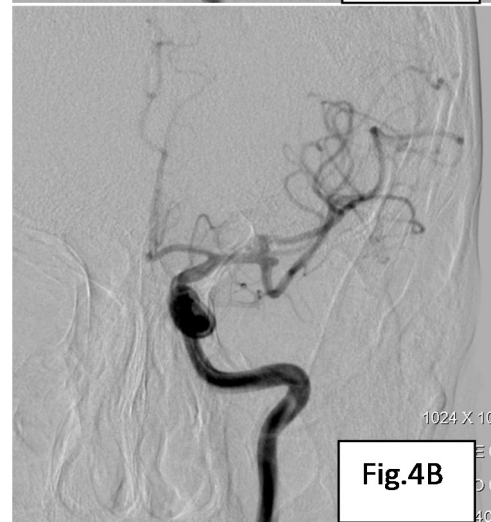
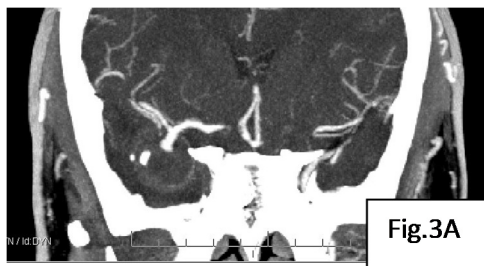
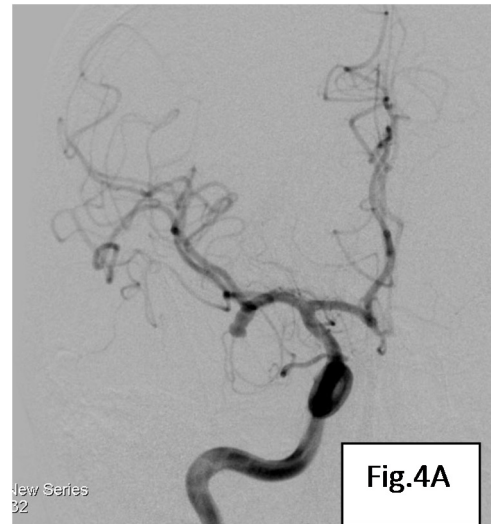
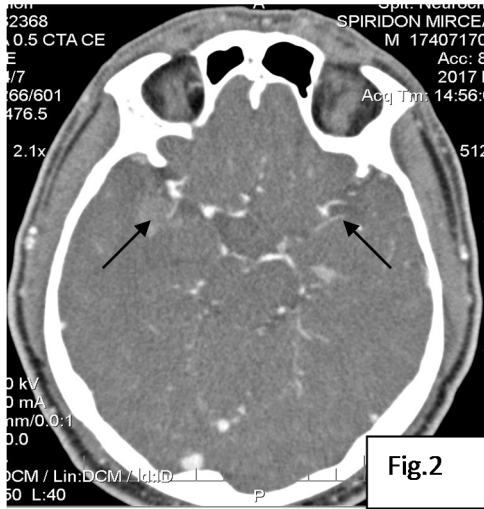
internal luminal diameter (Figure 3A, B, C). Digital subtraction angiography (DSA) revealed an active aneurysm of 1 cm at the right MCA bifurcation (Figure 4 A, B). Our diagnosis was giant thrombosed aneurysm with concentric thrombus at the right MCA bifurcation.

The proposed therapeutic management for this lesion was direct aneurysm neck clipping with total or partial thrombosed mass removing. A superficial temporal artery (STA) – M2 anastomosis was also planned to be performed if trapping of the aneurysm was required.

Right frontotemporal craniotomy was performed with right STA preservation at the time of skin incision. The STA was prepared for a potential anastomosis to right MCA. Then the right sylvian fissure was dissected with exposure of the MCA bifurcation. A giant thrombosed aneurysm sac is microsurgically exposed with an apparent permeable neck (Figure 5A). First, a straight clip was applied to the neck, but the clip has a tendency to smoothly slip towards onto the parent artery (Figure 5B). In this condition we decided to try to evacuate the thrombus for a safety final clip application. The initial clipping of aneurysm neck was maintained for bleeding control in order to avoid temporary occlusion of the MCA. The bottom aneurysm wall was incised over the thrombus and the distal part of the thrombus was detached. Then intraaneurysmal thrombus has been fragmented with the cavitron ultrasonic surgical aspirator (CUSA) without opening of the vessel lumen. The power of the CUSA was initially set to less than 20% of maximum and then gradually reduced to 10% at the thrombus part closer to the aneurysm neck. Finally,

successful clipping of the aneurysm neck was obtained with preservation of all branches of the right MCA (Figure 5C). CT control performed next day after surgery showed a total removal of thrombotic mass (Figure 6). The patient was discharged home 7 days after the operation in perfect neurological status.





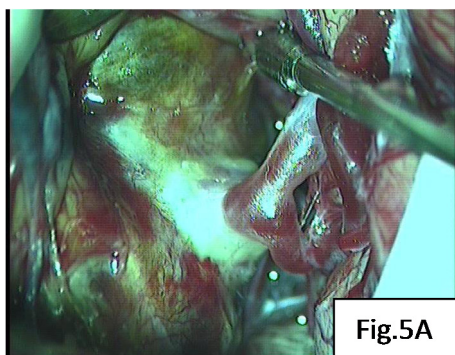


Fig.5A

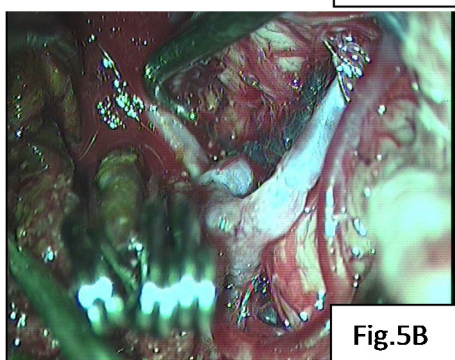


Fig.5B

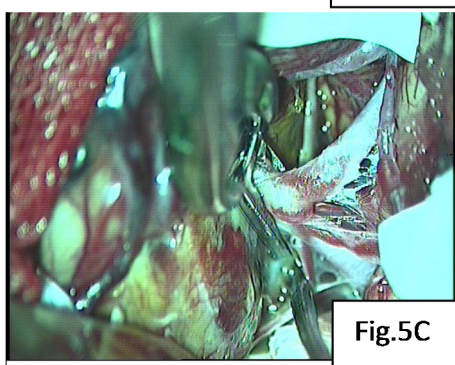


Fig.5C

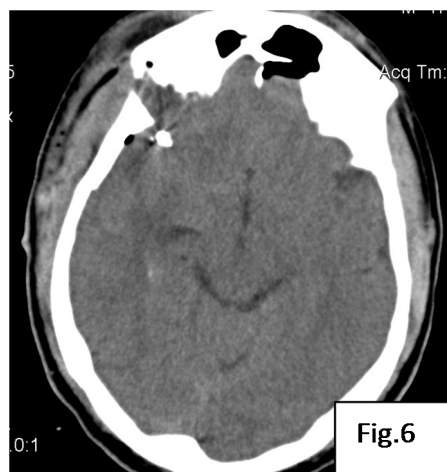


Fig.6

### Discussion

A giant thrombosed aneurysm has been defined as those that are greater than 25 mm in greatest dimension and having a solid organized intraluminal thrombus. The thrombotic mass can fully or partially occupy the volume of aneurysm.

Black et al [5, 6, 8] have stated that the rate of blood in aneurysm is inversely proportional to the volume of aneurysm, and the development of thrombosis in aneurysm is related to the critical ratio between the aneurysmal volume and the size of its neck. In addition, other hemodynamic parameters linked to the fluid dynamics of the jet stream of blood from the parent artery and the front wall conformation to it, also contribute to the development of intra-aneurysmal thrombosis.

Lawton et al classified the thrombotic aneurysms in six types on the basis of the thrombus and lumen morphology: 1. aneurysm with concentric thrombus, with a spherical lumen within the body of the aneurysm surrounded on all side by thrombus;

2. aneurysm with eccentric thrombus, with an elliptical lumen within the body of the aneurysm that is bordered on one or more side by a cap of thrombus; 3. aneurysm with saccular morphology with multiple lobes, and thrombus confined to one or more lobes; 4. aneurysm with saccular morphology and complete thrombosis; 5. aneurysm with fusiform or dolichoectatic morphology and canalized thrombus that forming longitudinal channel connecting inflow and outflow arteries; 6. aneurysm endovascular treated with intraluminal thrombus and iatrogenically deployed foreign material [5, 6].

Most giant thrombosed aneurysm show clinical symptoms as the mass effect. Also, subarachnoid haemorrhage and more less ischemic stroke are the follow clinical manifestation mentioned in the clinical reports. Sever headache similar to aneurysmal rupture has been described by a number of patients. The imaging evaluations, although they did not show a haemorrhage in the subarachnoid space, an increased volume of the thrombotic aneurysm, an enlargement of the non-thrombotic (active) portion of the aneurysm, or a fresh blood extravasations in the thrombotic layers of the aneurysm have been described.

Most of the clinical studies showed that microsurgical techniques are the optimal approach for the treatment of giant thrombosed aneurysm. Strategies for aneurysm microsurgical management are direct clipping, thrombectomy with clip reconstruction, bypass with aneurysm trapping or occlusion and parent artery occlusion. Placement of an imperfect

permanent clip was an alternative to temporary clipping as proximal and distal control. Additional factors than thrombus or aneurysm morphology were identified as conditioned elements of clip application – neck atherosclerosis, calcification, and arterial dysplasia.

More recently, specialized studies have described adjunctive techniques and principles in the surgical management of giant thrombosed aneurysms. These are the use of thrombus ultrasonic aspirator, intraoperative angiography, clipping under hypothermic circulatory arrest, judicious use of temporary clips, use of tandem clips and endovascular suction decompression of the aneurysmal dome [6, 8].

Complete treatment of thrombosed aneurysm by direct clipping depends on the volume, consistency, and location of the thrombus. Direct aneurysm clipping with temporary occlusion was optimized by MEP monitoring witch showed that in some cases even a short period of blood flow arrest may induce ischemic symptoms.

The intraaneurysmal thrombus removal is closely related to its consistency. Usually, the structure of intraaneurysmal thrombus consists on fresh clot, partial and total organized thrombus. If initially the microsurgical technique of intraaneurysmal clot removing consisted in the use of bipolar coagulation and piecemeal resection, it changed with the introduction of ultrasonic aspiration (CUSA). The thrombus evacuation with CUSA requires special attention in proper adjustment of suction and vibration power. Such meticulously reduction of the

power of the CUSA is essential in the thinning of the thrombus layer, in order to prevent interference with neck clipping without bleeding. Also, the CUSA parameters adjustment reduces the risk of displacing the thrombus into the parent arteries. The experience of numerous studies has shown that removing of embolus emerging into the parent artery lumen cannot be obtained without a controlled bleeding.

### Conclusion

Despite major advances in endovascular options the use of microneurosurgical techniques in the treatment of giant thrombosed aneurysms continues to be effective for successful outcomes. This treatment seems to be carried out with minimal morbidity and mortality using intraoperative MEP monitoring, CUSA thrombus removing and a prepared bypass option. We consider that judicious use in both microsurgery and endovascular neurosurgery is the key to improving the results of treating these lesions.

### References

1. Drake, C. G., & Peerless, S. J. (1997). Giant fusiform intracranial aneurysms: review of 120 patients treated surgically from 1965 to 1992. *Journal of neurosurgery*, 87(2), 141-162.
2. Hosobuchi, Y. (1979). Direct surgical treatment of giant intracranial aneurysms. *Journal of neurosurgery*, 51(6), 743-756.
4. Iwashita, T., Tanaka, Y., Koyama, J., Kobayashi, S., & Hongo, K. (2001). A giant thrombosed aneurysm of the anterior communicating artery which developed 18 years after clipping: A case report. *No shinkei geka. Neurological surgery*, 29(5), 427-431.
5. Kato, Y., Sinha, S., Sano, H., Watabe, T., Oda, J., Oguri, D., & Imizu, S. *Microsurgical Management of Thrombotic Aneurysms. World*, 6(1).
6. Lawton, M. T., Quiñones-Hinojosa, A., Chang, E. F., & Yu, T. (2005). Thrombotic intracranial aneurysms: classification scheme and management strategies in 68 patients. *Neurosurgery*, 56(3), 441-454.
7. Park DH, Chung YG, Shin IY, Lee JB, Suh JK, Lee HK. (2008) Thrombosed giant aneurysm of the pericallosal artery with inconclusive findings of multiple neuroimaging studies. *Neurol Med Chir (Tokyo)*. 2008 Jan;48(1):26-9.
8. Sughrue, M. E., Saloner, D., Rayz, V. L., & Lawton, M. T. (2011). Giant intracranial aneurysms: evolution of management in a contemporary surgical series. *Neurosurgery*, 69(6), 1261.
9. Sugita, M., Kinouchi, H., Nishiyama, Y., Kanemaru, K., Yoshioka, H., & Horikoshi, T. (2009). Direct Clipping of a Thrombosed Giant Cerebral Aneurysm After Thrombectomy Without Bleeding to Minimize the Temporary Occlusion Time. *Neurologia medico-chirurgica*, 49(12), 600-603.