

# HEMIPLEGIC CHILDREN WITH A THUMB-IN-PALM DEFORMITY: AN EVALUATION OF SURGICAL TREATMENT USING 8 MM CINE FILMS AND VIDEO RECORDINGS

R Sinclair-Smith, LJ Arens\*

## SUMMARY

The pre- and post-operative 8mm cine-films and video films taken of seven hemiplegic children were reviewed. All seven have received regular and intensive physiotherapy but required surgery to obtain a good supportive functional hand. Video recordings provided a very useful method of assessing the outcome of hand surgery.

## OPSOMMING

Die voor- en na-operatiewe 8mm films en videobande van sewe hemipleגיעse kinders is evalueer. Al sewe het gereelde en intensiewe fisioterapie ontvang, maar het chirurgie nodig gehad vir 'n goed-ondersteunende, funksionele hand. Video-opnames is 'n goeie metode om die resultate van handchirurgie te bepaal.

## INTRODUCTION

The thumb-in-palm posture is common in spastic hemiplegic children, however it is not often that the thumb contracture is so fixed that it requires surgical intervention. Over the past 16 years, 7 hemiplegic children at Vista Nova Cerebral Palsy School had a surgical procedure between the ages of 3 and 6 years for the release of the thumb. The number of patients is too small to allow statistical analysis of the merits of any of these operative procedures. Far larger numbers have been reported in the literature. In 1980, Chait<sup>1</sup> suggested that surgery performed early (18 months to 5 years) would obviate the necessity for more extensive tendon transfers at a later date as well as give a better cosmetic appearance. Both he and Goldner<sup>2</sup> recommend post-operative splintage and intensive therapy. However Bleck<sup>3</sup> in 1987 noted that the most experienced surgeons in this field recommended deferring surgery until the age of 5 years or older so that the child can co-operate in the pre-operative analysis and the post-operative regimens. Smith<sup>4</sup> described the successful results of surgery in 7 patients with increased tone of flexor pollicis longus but these were an older group (8-35 years). Zancolli<sup>5</sup> noted that the child must be sufficiently intelligent to understand the surgical goals and that some ability to extend the fingers as well as active wrist flexion assures a better result.

The results of hand surgery are generally recorded through written descriptions and the use of still photographs. We feel, however, that it is not sufficient to record what movements of the fingers and thumb are possible; of even more importance is to record how the hand is used and the quality of the movement. In this paper, 7 case studies are given to confirm that hand surgery can be very successful and that

video recordings should be used in all cases for pre- and post-operative assessment of hand function. We also draw attention to some of the pitfalls if a standardized technique is not used for accurate comparison.

All the patients presented here received regular and intensive neurodevelopmental therapy but surgical intervention became necessary to obtain a good functional supportive hand. All seven have astereognosis and various degrees of increased muscle tone. Three are in a normal academic class, three are in a special class for slow learners, and one has subsequently been placed in a training centre for the more retarded child. Pre- and post-operative 8mm cine-films and video recordings of the seven were reviewed and the findings are presented. In the early cases using 8mm cine-films, standardized testing was not employed but in the later video recordings identical blocks (3cm square) and wooden sticks (0,5cm square by 5cm long) were used.

## CASE 1

This patient, a 6 year old girl, is in sub A. At 16 months of age she developed a right sided hemiplegia following a massive infarct in the distribution of the left middle and anterior cerebral arteries. She was treated at Forest Town School, Johannesburg before transfer to Vista Nova School. The pre-operative films showed her extreme frustration at not being able to use her right hand even in a supportive role. She had to remove the right thumb from her palm manually in order to grasp an object and release was impossible. Active wrist extension was present with grasp and the forearm was held in the midposition (figure 1).

At 5 years of age the first dorsal interosseus was released from the first and second metacarpals and the adductor

\* Rosalie Sinclair-Smith DIP (Physiotherapy), Physiotherapist, Vista Nova School, Cape Town.  
Leila J Arens BSc, MBChB, Part-time Lecturer, Department of Paediatrics and Child Health, University of Cape Town and Chief Medical Officer, Vista Nova School.

pollicis was released from its insertion into the proximal phalanx of the thumb.



Figure 1: A pre-operative photograph of Case 1 showing the thumb in the palm of the hand. All photographs were taken from video recordings

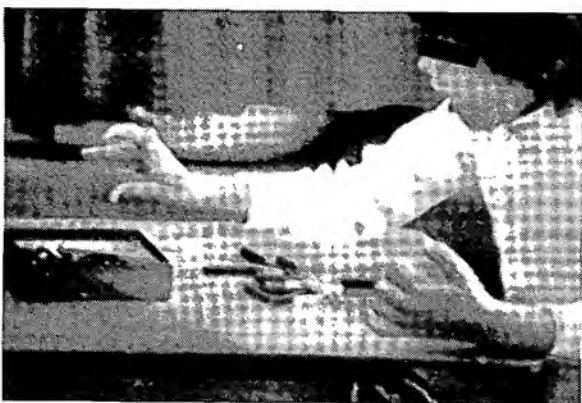


Figure 2: A post-operative photograph showing the thumb out of the palm.

The post-operative videos demonstrated that both grasp and release were now possible (figure 2). Active abduction of the thumb could be achieved.

#### CASE 2

This 10 year old right hemiplegic boy is one of twins born by Caesarian section at 7 months gestation. A porencephalic cyst was demonstrated on CT scan.

He has received physiotherapy since 8 months of age. An old 8mm cine-film showed the right thumb to be held firmly in the palm and the hand was totally ignored.

A capsulodesis was performed on the metacarpophalangeal joint of the right thumb at 3 years of age. Post-operative films at 3 months and 5 years are available. Initially, at 3 months post-operatively, a good grasp and release was noted although much encouragement was needed before the hand was used. The second video showed a good supportive hand with grasp and release present. Wrist flexion was needed for finger extension but wrist extension was present once the grasp was achieved. This child is now in standard 3.

#### CASE 3

The patient is a 10 year old left hemiplegic boy born by Caesarian section to a 17 year old mother. His Apgar score was low at birth and he required intubation and resuscitation. Gross speech problems are present. He received physiother-

apy from under 1 year of age.

A pre-operative 8mm cine-film showed difficulty in picking up small pegs. The thumb was adducted and flexion of the distal phalanx of the index finger further hampered function. An adequate grasp and release was present for larger objects.

At 5 years of age, he had a partial release of his flexor pollicis brevis and adductor pollicis brevis, release of his adductor pollicis from the 2nd and 3rd metacarpal shafts, and the 1st dorsal interosseus was released from its origin. The post-operative video taken at 10 years of age showed less adduction of the thumb allowing easier grasp of small objects. This child relies on slight wrist flexion to extend his fingers. At present he is in standard 3.

#### CASE 4

This 14 year old boy is a left hemiplegic with gross speech problems. His parents noted that he was not using his left arm from infancy. He was treated from an early age in the Transvaal and more recently at Vista Nova School. An early cine film shows the hand fisted with the thumb out of sight. The operative procedures performed at 4 years of age were release of adductor pollicis, first dorsal interosseus and flexor pollicis brevis, plication of the capsule of the metacarpophalangeal joint and the release of flexor carpi ulnaris at the wrist.




Figure 3: Case 4. Tying shoelaces successfully.

The post-operative video, taken 10 years later, shows a hand with good grasp and release. The wrist is held in the midposition with hyperextension of the metacarpo-phalangeal joints. The hand plays a good supportive role in many functional activities such as tying shoe laces (figure 3). This boy has been placed in special class.

#### CASE 5

This is an 8 year old girl with acquired left hemiplegia following TB meningitis in infancy.

The pre-operative video shows the thumb firmly in the palm with severe wrist flexion (figure 4). Surgery was performed at 6 years of age which included capsulodesis of the left metacarpophalangeal joint of the thumb and transference of adductor pollicis brevis to extensor pollicis brevis with the distal stump being transferred to flexor carpi radialis. The results of the operation were poor. No movement was seen in the thumb and severe wrist flexion with a swan neck deformity of the distal interphalangeal joint of the index finger was seen (figure 5). This child is now in a training centre.



Figure 4: A pre-operative picture showing marked wrist flexion and finger extension. The thumb is not visible.



Figure 5: Case 5. The post-operative result was poor.

#### CASE 6

This is a 17 year old girl with a left hemiplegia following birth complications. She received physiotherapy from 17 months of age. A pre-operative 8mm cine-film showed a tightly fistled hand which was not used at all.

At 3 years of age she underwent surgery. The first dorsal interosseus was released from the thumb metacarpal and the abductor pollicis longus tendon, having been divided at the level of the radial styloid, was transferred across the eminence of the thumb to be attached to the divided flexor carpi radialis tendon. 13 years later a video shows the thumb to be out of the palm but weakness and minimal active movement was seen. However, she is able to use her hand in many daily activities including knitting as the thumb does not hinder function. She is in a special class.

#### CASE 7

This is a 22 year old right hemiplegic girl who, after many years in a special class, has now left school. She was born by forceps delivery and was placed in an incubator for 24 hours. Her parents noticed that she was not using her right hand at two months of age but she did not receive physiotherapy until 4 years of age. Early pre-operative 8mm cine-films show marked ulnar deviation, wrist flexion, and the thumb firmly in the palm.

At 6 years of age, the right flexor carpi radialis was transferred to the abductor pollicis brevis. Subsequent 8mm cine-films show good abduction of the thumb only if the wrist was held passively in extension. In order to reduce the wrist flexion which hampered functional movement, further surgery was performed 4 years later. The flexor carpi ulnaris

was transferred to extensor carpi radialis brevis and pronator teres was released. This, however, resulted in a wrist fixed in extension with no functional use of the thumb which rests on top of the index finger.

#### DISCUSSION

Pre- and post-operative evaluation by 8mm cine-filming and, in more recent years, video filming, is an extremely valuable tool for more accurate assessment of surgical results although the recording of muscle tone remains a problem. The filming of this series of children with a thumb-in-palm deformity was originally started in order to allay the fears of anxious parents and to prove to them that progress was being made. As experience was gained, it was realized that the technique had tremendous potential for more accurate assessment of the patients following surgery. Five out of the seven children clearly showed a good result in spite of the fact that all seven underwent different surgical procedures.

The aim of the surgery was to provide a good supportive hand in everyday functional activities, for instance, tying shoelaces, taking off the cap of a pen or ruling lines in a schoolbook. With the thumb out of the palm, the older girls are able to assist in housework and are even able to knit.

All the children have different degrees of astereognosis. Most hemiplegic children use their affected hand only as an assisting hand. Even where astereognosis is present, if reasonable function is possible the child will use the hand for bilateral activities despite the diminished perception. Astereognosis was therefore considered not to be a contraindication to surgery.

A careful assessment of active movement and degree of increased muscle tone, particularly at the wrist, is essential pre-operatively as these are the possible cause of failure of treatment in two of the cases.

Good post-operative rehabilitation with the active co-operation of the child is important; age and the intelligence of the child play a significant role in successful management.

Care should be taken when filming to show what active movement is present because frequently, as in one of our cases, only a fistled hand was filmed, making assessment difficult. However, with a little care and practice, the basic skills of filming can be acquired. The same equipment for determining function should be used both pre- and post-operatively.

#### CONCLUSION

The main objective of hand surgery for thumb-in-palm deformity is to achieve a useful supportive hand for functional activities. Video filming should be carefully planned and executed to ensure accurate comparison of pre- and post-operative hand function.

#### REFERENCES:

1. Chait LA, Kaplan I, Stewart-Lord B, Goodman M. Early surgical correction in the cerebral palsied hand. *J Hand Surg* 1980; 5:122-126.
2. Goldner JL. Surgical treatment for cerebral palsy. In: McCollister-Evarts C, Carlson DH (eds). *Surgery of the Musculoskeletal System (vol 1)*. Churchill Livingstone, New York, 1983; 2:439.
3. Bleck EE. *Orthopaedic Management in Cerebral Palsy*. JB Lippincott Co., Philadelphia. 1987:228.
4. Smith RJ. Flexor pollicis longus abductor-plasty for spastic thumb-in-palm deformity. *J Hand Surg* 1982; 7:327-334.
5. Zancolli EA, Goldner JL, Swanson AB. Surgery of the spastic hand in cerebral palsy; report of the committee on spastic hand evaluation. *J Hand Surg* 1983; 8:766-772. ♥