

Potential pitfalls – pips or polyps?

I van de Werke, FRCR
A T du Plessis, MB ChB

Department of Radiology, Kalafong Hospital, University of Pretoria

Z Lockhat, FFRad (D)

Department of Radiology, Pretoria Academic Hospital, University of Pretoria

A variety of pips and chewed nuts can simulate disease by appearing as multiple filling defects on the double-contrast barium enema. The unwary and untrained eye might interpret these filling defects as multiple polyps, leading to the wrong diagnosis and unnecessary further investigations or treatment.

A case of multiple linseeds mimicking polyposis coli on double-contrast barium enema has been described by Petty and Mannion.¹ The following similar cases were noted.

Case 1. A 73-year-old woman presented with abdominal pain. A double-contrast barium enema showed multiple pointed oval-shaped filling defects (Fig. 1a, white arrows). On retrospective enquiry, the patient confirmed taking linseed regularly for constipation and also ingested grapes during the 3 days prior to the examination. The filling defects noted were not consistent with linseed size and shape, and most likely represent filling defects from grape seed. To simulate the picture of linseed and grape pip filling defects, linseeds (Figs 1b and c), grape pips (Fig. 1d) and liquid barium were placed in latex surgical gloves and X-rayed to simulate double-contrast barium study. Prior to the study, the linseeds and grape pips were soaked overnight in tepid water to account for natural seed swelling occurring during bowel transit.

Case 2: Two cases of mealie pips simulating polyps (Figs 2a - c, white arrows) were seen during double-contrast barium enema studies. Both male patients confirmed ingestion of mealies prior to the investigation.

Case 3: A 54-year-old-female patient underwent a double-contrast barium enema study for rectal bleeding and change in bowel habits fol-

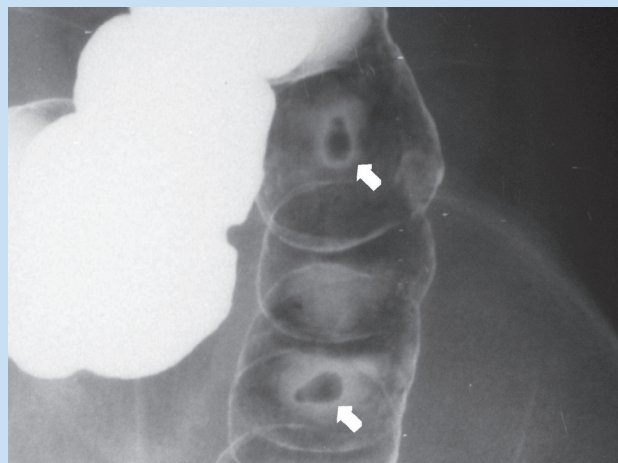


Fig. 1a. Grape pips (arrows) simulating polyps.

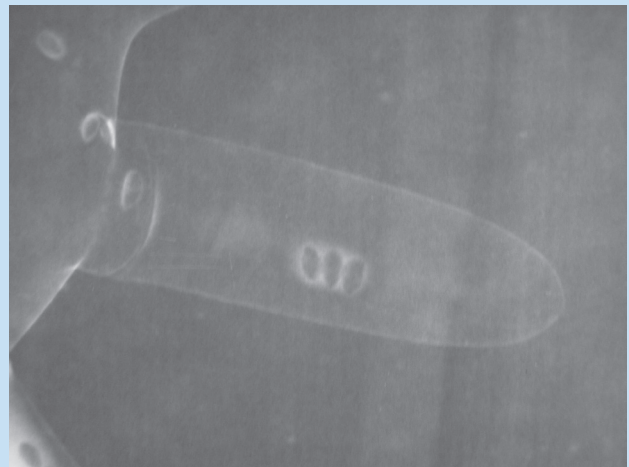


Fig. 1b. Multiple linseed shadows during simulation in latex glove.

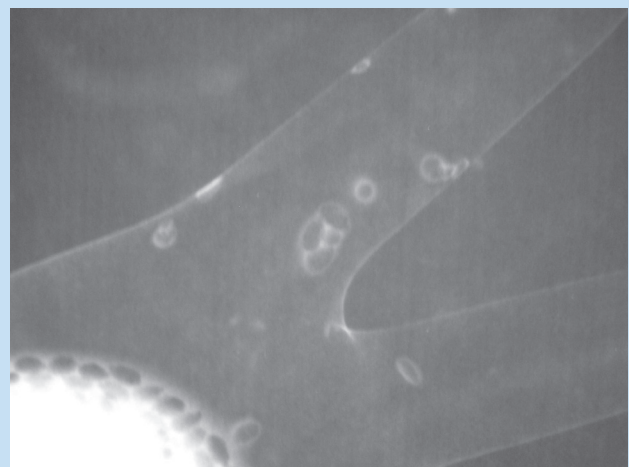


Fig. 1c. Multiple linseed shadows during simulation in latex glove.

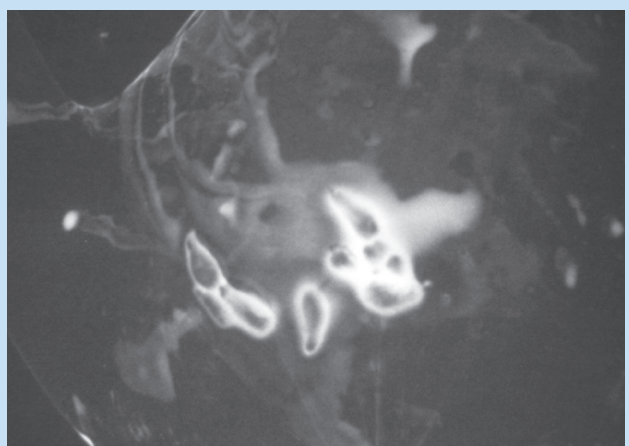


Fig. 1d. Multiple grape pip shadows during simulation in latex glove.

PICTORIAL INTERLUDE

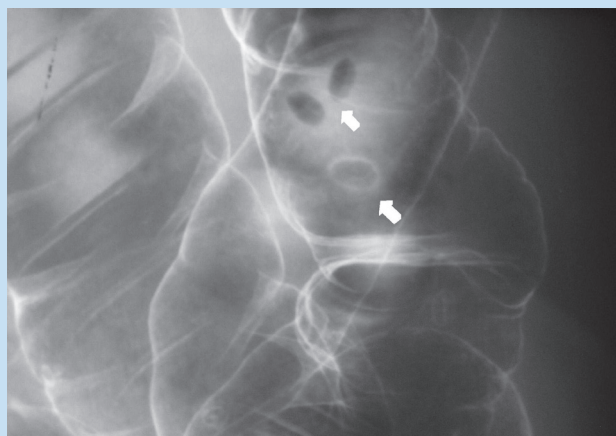

Fig. 2a. Mealie pips (arrows) simulating polyps.

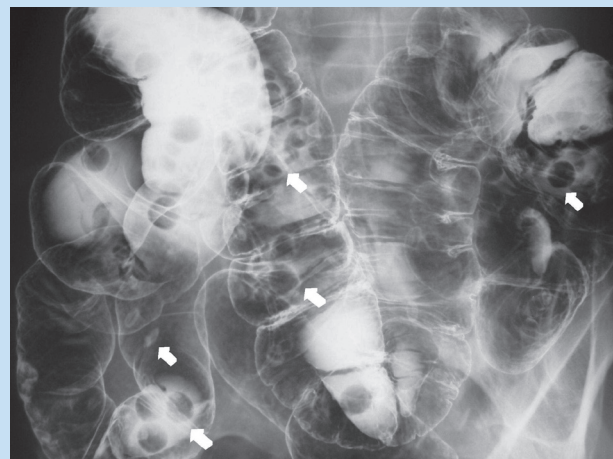


Fig. 2b. Mealie pips (arrows) simulating polyps.

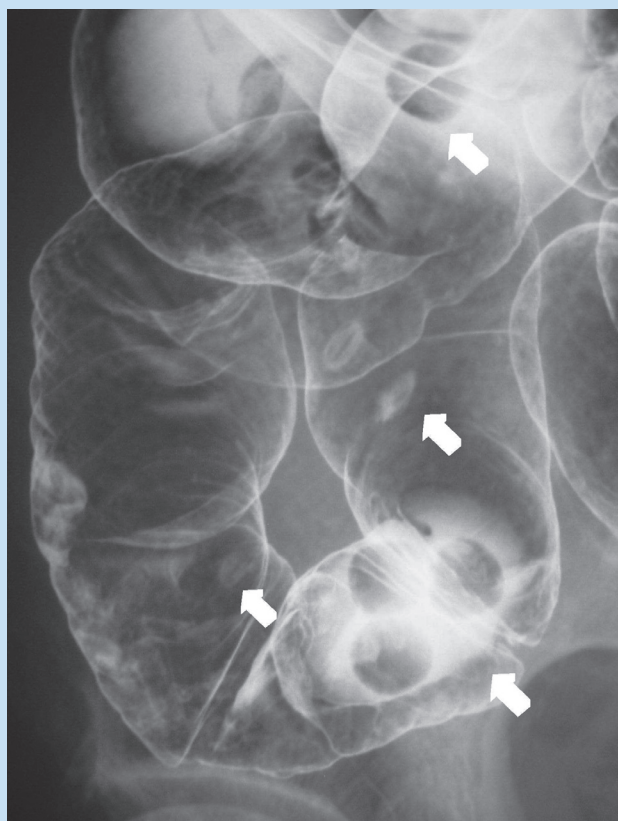


Fig. 2c. Mealie pips (arrows) simulating polyps.

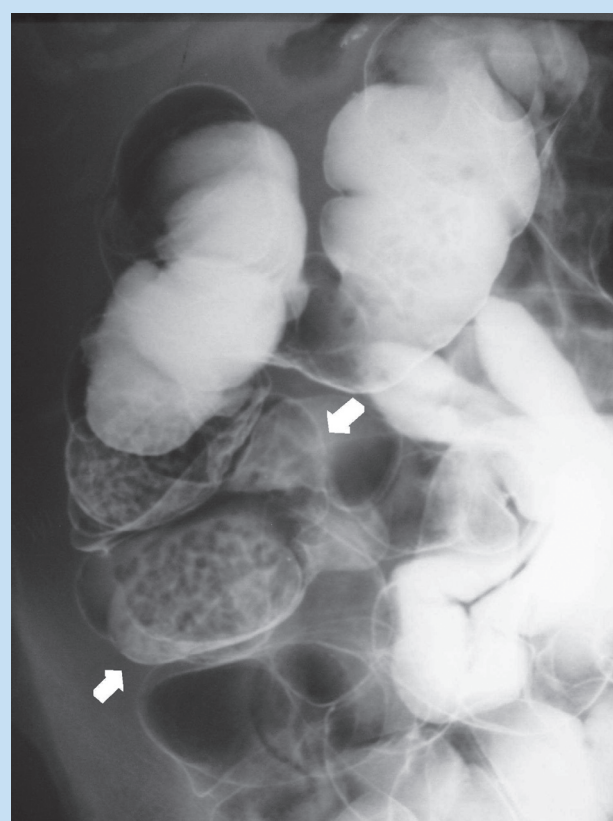


Fig. 3. Chewed cashew nuts (arrows) simulating polyps.

lowing strangulated incisional hernia repair. Multiple small, irregular filling defects (Fig. 3, white arrows) were noted in the dependent parts of the colon. The patient confirmed that large amounts of cashew nuts were ingested during the 2 days prior to the investigation.

As illustrated by the above cases, seed and pip filling defects mimicking multiple polyps must be kept in mind when interpreting double-

contrast barium enema studies. This underlines the importance of proper history taking and retrospective enquiry about the dietary habits of patients, after identifying such filling defects during interpretation of double-contrast barium enema studies.

1. Petty D, Mannion R. Case of multiple linseeds mimicking poliposis coli on double contrast barium enema. *Clin Radiol* 2003; 58: 87-88.