

Post-traumatic cholesteatoma ... a rare occurrence

Logeshini Naidoo, *FC Rad (Diag) SA*
A Nanan, *FCS (Orl) SA*

Helen Joseph and Coronation Hospitals, Johannesburg

Abstract

Temporal bone fractures and their acute complications have been well described in radiology and ENT journals; this is in contrast to the delayed and rare complication of implantation cholesteatomas. We present the computed tomographic (CT) findings of two cases of infiltrating cholesteatomas that developed many years after temporal bone trauma.

Introduction

Post-traumatic cholesteatomas are well recognised albeit rare late complications of temporal bone injuries. They were first described in German literature by doctors reviewing World War I blast victims,¹ with the first definitive series by Eckel in 1966.² He described three cases of post-traumatic cholesteatomas and made postulations on their origin.

Since then, there have been sporadic reports describing mainly cholesteatomas in the middle ear and mastoid,³ although external ear lesions have also been mentioned.⁴ CT plays an invaluable role in the evaluation of this condition owing to its ability to delineate bony anatomy. Pre-operative CT establishes the type of surgical procedure as it determines the extent of the cholesteatoma, ocular chain involvement, facial canal

integrity, and tegmen tympani and dural plate involvement.⁵

We report two cases of post-traumatic cholesteatomas that caused extensive middle ear destruction that developed many years following trauma.

Case 1

A 13-year-old boy presented with a 10-month history of a foul discharge from his left ear. He had sustained a gunshot wound to the left side of his face at the age of 3 that had resulted in temporal bone injury and subsequent hearing loss. The exact extent of the injury was not known. Otological examination was unhelpful due to severe external auditory canal stenosis.

Case 2

A 30-year-old man presented with a longstanding offensive left-ear discharge and non-pulsatile tinnitus. He had sustained a gunshot injury with temporal bone injury 10 years before. A protruding mass was noted extending into the distal external auditory meatus on otological examination.

In both cases, temporal bone CT scans were performed prior to surgery. Case 1 revealed a non-enhancing soft-tissue mass (Fig. 1) that had engulfed the epitympanum with extrusion through the aditus ad antrum into the mastoid air cells. Ossicles were medially displaced with erosion of the malleus and incus body (Fig. 2). Vestibular and semi-circular canal erosions were noted (Figs 3 and 4). Tegmen tympani, jugular foramen as well as condylar fossa and lateral semi-circular wall dehiscence were noted. A longitudinal fracture through the external auditory canal, middle ear and mastoid bone was present.

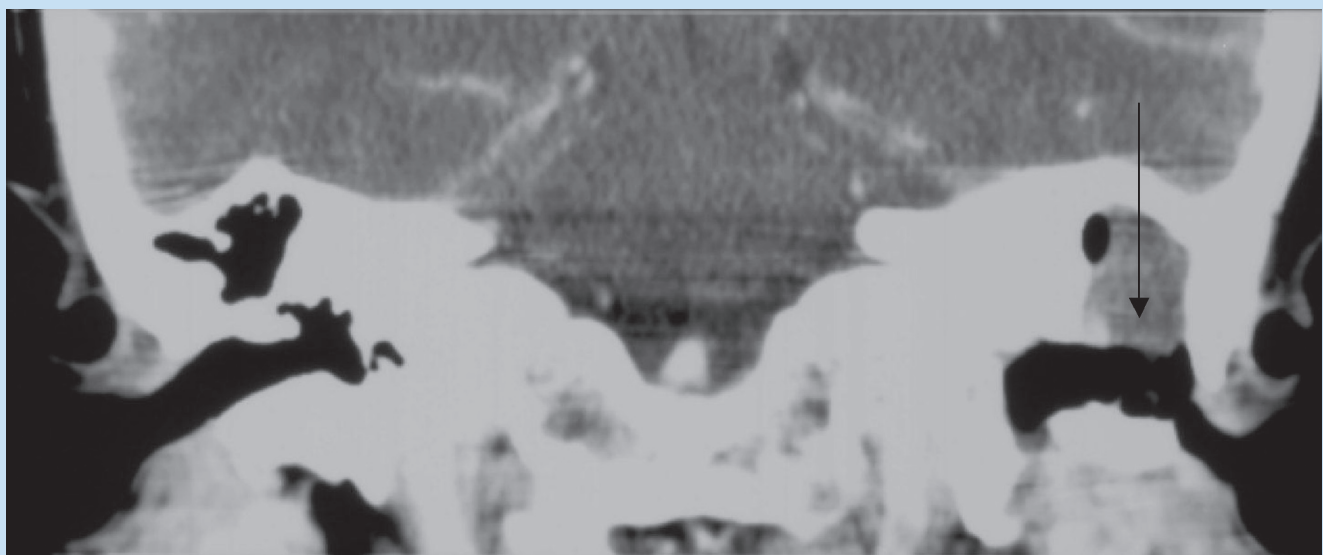


Fig. 1. Coronal CT using soft-tissue windowing, depicting a non-enhancing soft-tissue mass (arrow).

CASE REPORT

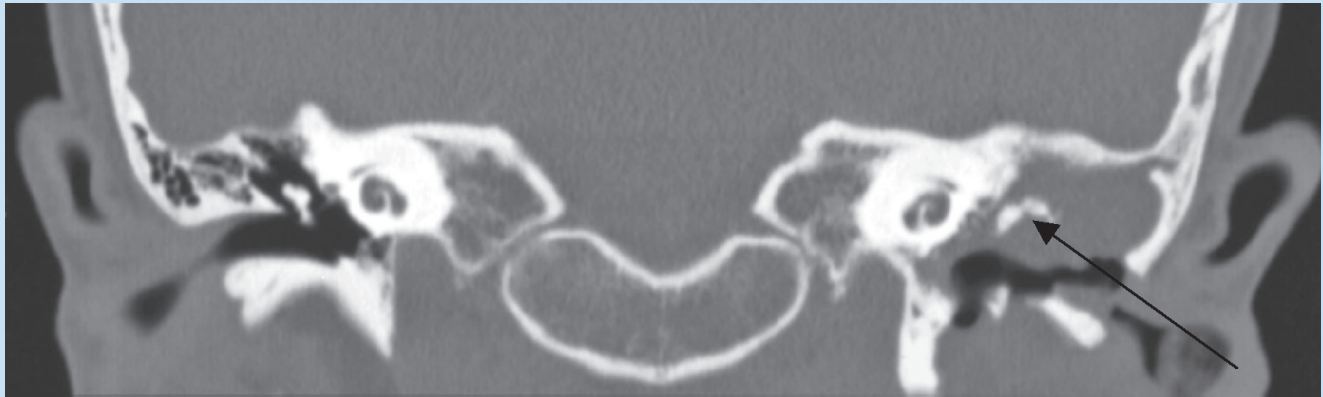


Fig. 2. Coronal CT with bony windows showing the invasive cholesteatoma eroding and displacing the incudo-malleolar complex (arrow).

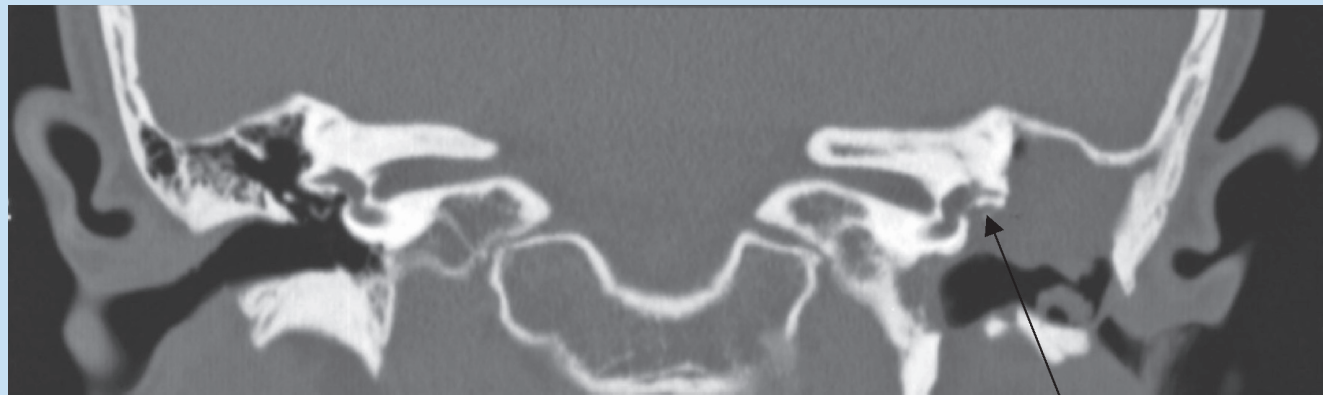


Fig. 3. Coronal CT displaying erosions adjacent to the vestibule (arrow).

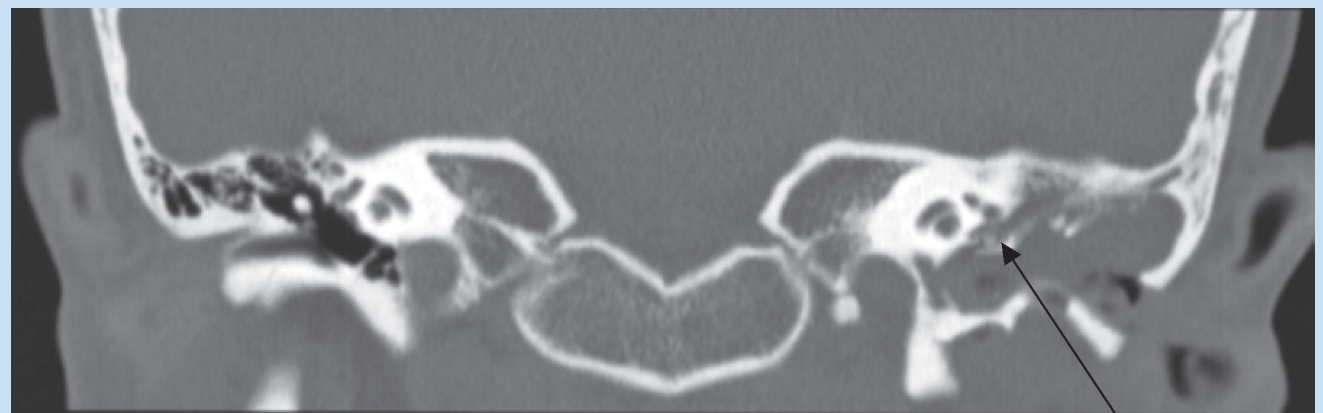


Fig. 4. Coronal CT with semi-circular erosions (arrow).

Case 2 displayed a similar mass with marked middle ear extension. Artifact from a bullet lodged in the mastoid was present (Fig. 5). The lesion, although extensive, also seemed to arise from the epitympanum. Tegmen tympani and lateral semi-circular wall dehiscence were also visible (Fig. 6). Ossicles were not visible. A transverse fracture through the external ear and mastoid air cells was present.

Surgery was consistent with CT findings. In both cases, radical mastoidectomies with cholesteatoma excision were performed.

Discussion

Cholesteatomas are non-neoplastic but destructive lesions consisting of desquamating keratin epithelium.⁵ The keratin is shed continu-

CASE REPORT

ally by an envelope surrounding the cholesteatoma called the matrix.⁵ They occur mainly in the middle ear cleft but have also been reported intracranially and in the external auditory canal.⁶ There are two types of cholesteatomas: congenital and acquired. Congenital cholesteatomas develop behind an intact tympanic membrane; acquired cholesteatomas are associated with defects in the tympanic membrane.⁶ Acquired cholesteatomas are more common and may develop by various mechanisms, including trauma.⁶

Eckel recognised that traumatic cholesteatomas occurred as a complication of different types of injury to the temporal bone.² He suggested central tympanic membrane rupture, external meatal fractures with marginal tympanic membrane injury, soft-tissue and bony defects of the mastoid and, lastly, meatal stenosis as causes of cholesteatomas. He postulated that central tympanic membrane rupture allowed foreign body implantation in the middle ear, resulting in localised chronic inflammatory reactions and squamous metaplasia; and hence cholesteatomas. External meatal fractures and soft-tissue and bony fragment displace-

ment predispose to soft tissue and blood organising in fracture lines, thus providing a good substrate for bacterial growth.^{1,2} In traumatic meatal stenosis, the medial canal skin continues to grow, casting off sheets of desquamation, and ultimately leads to cholesteatomas.

The question arises as to why post-traumatic cholesteatomas are rare. It appears that straightforward, uncomplicated fractures as seen in the majority of patients, generally heal with callus formation that forms a strong barrier against epithelial migration and thus implantation cholesteatomas. In our series, both patients displayed extensive tympanic membrane rupture and external and mastoid bone fractures. Patient 1 also had meatal stenosis. These findings are consistent with Eckel's theory of post-traumatic cholesteatoma development.

The time interval between injury and diagnosis of post-traumatic cholesteatoma is very variable and may range from 1 to 25 years.^{1,2} In most of the cases reported, time to presentation was more than 10 years.² In our series, the latent interval averaged 10 years. Growth rates depend on numerous factors, including vascular status, age and site.² Rates seem faster in children and with concurrent infection.²

High-resolution temporal bone CT depicts cholesteatomas as non-enhancing, soft-tissue masses.⁷ Bony erosion adjacent to the soft-tissue mass, with/without intramural bony fragments, forms the mainstay of the diagnosis, and distinguishing the lesion from granulation tissue and fluid and pus.⁷ Bony erosions may be smooth or irregular, secondary to necrotic bone.⁷

Other CT findings include: erosions of scuta, destruction and displacement of the ossicular chain, labyrinthine fistulas, facial canal erosions, tegmen tympani dehiscence, and destruction of the mastoid.⁵

It is important to evaluate for extension into mastoid air cells, tegmen tympani integrity and facial nerve canal delineation, as these features may change the surgical management. Pre-operative knowledge is helpful in planning the surgical approach. CT is the preferred investigation owing to its superior imaging of bony anatomy.⁵ The role of MRI is limited to differentiating cholesteatomas from granulation tissue and scar tissue, which display enhancement post-contrast.⁵ MRI may also show intracranial extensions, and be used for intra- and extratemporal complications as well as post-surgical follow-up.⁵

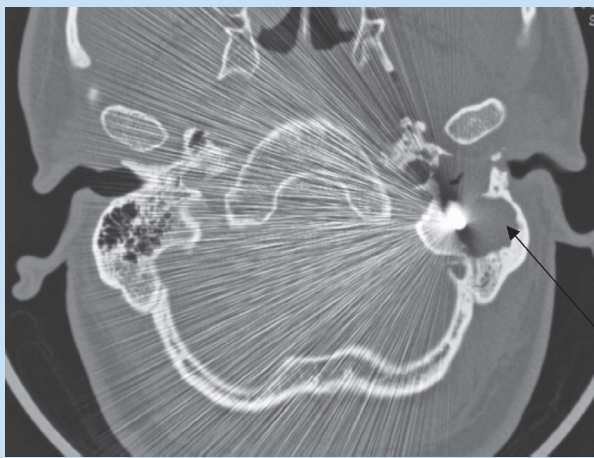


Fig. 5. Axial CT displaying a bullet lodged in the mastoid secondary to the old trauma. Note the cholesteatoma extending into the mastoid (arrow).

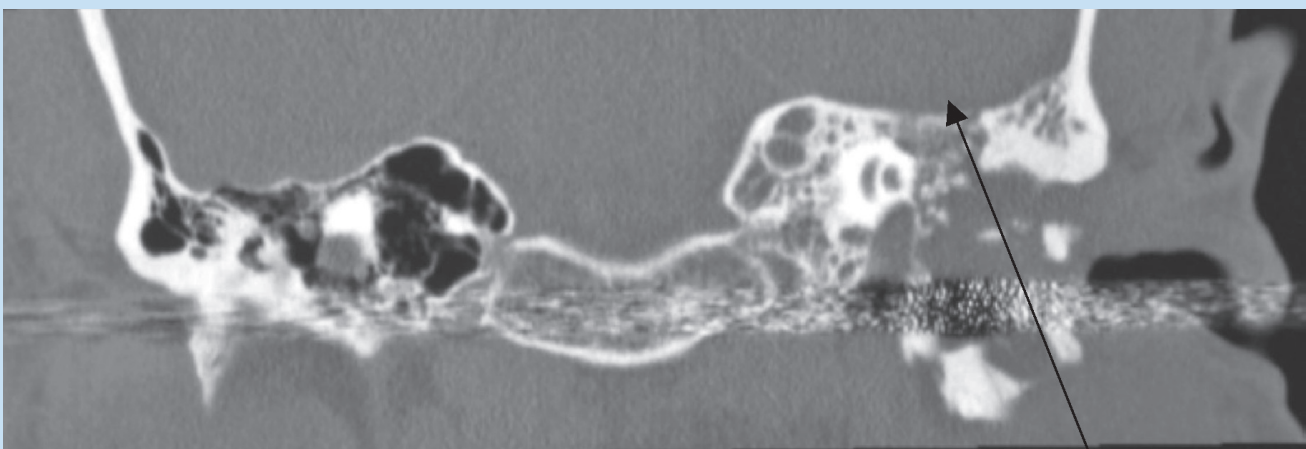


Fig. 6. Coronal CT showing the infiltrating cholesteatoma, extending into the middle ear with tegmen tympani dehiscence (arrow).

CASE REPORT

Conclusion

Post-traumatic cholesteatomas are rare entities and tend to develop after severe temporal bone trauma. CT displays a non-enhancing soft-tissue mass in the background of previous trauma and delineates the anatomy and variants, which is essential for pre-surgical planning.

1. Brookes G. Post-traumatic cholesteatoma. *Clin Otolaryngol* 1983; 8: 31-38.
2. Eckel W. Traumatic cholesteatoma of the hearing organ. *Z Laryngol Rhinol* 1966; 45: 265.

3. Wallwork B, Black B. Middle cranial fossa cholesteatoma following temporal bone trauma. *Aust J Otolaryngol* 2002; 5: 128-130.
4. Tsuyoshi K, Yoshiro Y, Norikuni K, et al. Post-traumatic cholesteatoma of the external auditory meatus: 2 case reports. *Practica Otologica* 2000; 93: 201-205.
5. Waizel S, Grandvallet J, Vargas A, et al. Temporal bone acquired cholesteatomas. [http://www.emedicine.com/RADIO/topic\[updated 1 May 2007\]](http://www.emedicine.com/RADIO/topic[updated 1 May 2007]) (accessed 30 May 2008).
6. Persaud R, Hajioff D, Trinidad A, et al. Evidence-based review of aetiopathogenic theories of congenital and acquired cholesteatoma. *J Laryngol Otol* 2007; 121(11): 1013-1019.
7. Heilburn M, Salzman K, Glastonbury C, et al. External auditory canal cholesteatoma: clinical and imaging spectrum. *Am J Neuroradiol* 2003; 24: 751-756.

Radiology Secrets, 2nd edition With STUDENT CONSULT Online Access



By **E. Scott Pretorius** and **Jeffrey A. Solomon**
ISBN 0323034055 / 9780323034050 · Paperback
· **656 Pages** · **679 Illustrations**
Mosby · **Published November 2005**

Health & Medical Publishing Group
Private Bag X1, Pinelands, 7430
Tel: 021 - 6578200
Fax: 021- 6834509
e-mail: carmena@hmpg.co.za / brents@hmpg.co.za

The smart way to study! Elsevier titles with STUDENT CONSULT will help you master difficult concepts and study more efficiently in print and online! Perform rapid searches. Integrate bonus content from other disciplines. Download text to your handheld device. And a lot more. Each STUDENT CONSULT title comes with full text online, a unique image library, case studies, USMLE style questions, and online note-taking to enhance your learning experience.

Features

- Uses bulleted lists, tables, short answers, and a highly detailed index to expedite reference.
- Features pearls, tips, memory aids, and secrets from the experts.
- Covers all of today's most common conditions and their treatment.