

Lemierre's syndrome – the uncommon cold

R Such

MB MCh, FCRad (Diag)

E Joseph

MB BCh, FFRad (Diag)

*Department of Radiology
University of the Witwatersrand
Helen Joseph and Chris Hani, Baragwanath Hospitals
Johannesburg*

Abstract

Lemierre's syndrome (postanginal sepsis/necrobacillosis) is a rare clinical entity characterised by the triad of acute oropharyngeal infection, with secondary thrombophlebitis of the internal jugular vein and metastatic septic emboli. A high degree of clinical suspicion is needed to diagnose the syndrome and the radiologist's awareness of it may expedite the diagnosis and therefore the appropriate treatment for these potentially fatal sequelae of a 'sore throat'.

We present a case of a 20-year-old man admitted to Helen Joseph Hospital in July 2004 with multiple lung abscesses, in whom internal jugular vein thrombophlebitis was subsequently diagnosed. Chest radiographic and computed tomography (CT) images accompany a brief review of this largely forgotten syndrome

Introduction

Lemierre's syndrome is a rare form of postanginal septicaemia, usually caused by gram-negative oral anaerobes, the most common pathogen being *Fusobacterium necrophorum* (necrobacillosis).¹ Bacterial oropharyngeal infection, such as pharyngitis or tonsillitis, is followed by local invasion of the lateral pharyngeal space and septic thrombosis of the internal jugular vein, and finally the occurrence of metastatic complications.² The entity was first described in detail by Lemierre in 1936.³ Before the advent of antibiotics, Lemierre's syndrome was common, often following a fatal course, with a 90% mortality rate.^{3,4} More recently, however, the widespread use of antibiotics in the treatment of oropharyngeal infections has led to a marked decline in prevalence and Lemierre's has become a largely forgotten disease.^{3,5}

The syndrome typically occurs in previously healthy adolescents and young adults, with a short interval between the oropharyngeal infection and the onset of septicaemia.^{6,7} The most common sites of secondary septic emboli are the lungs (79.8%)² and large joints,⁷ whilst less commonly documented sites include the liver, spleen and brain.^{1,3,8} Today the prognosis is relatively favourable with early, directed antimicrobial therapy.^{4,9} The radiologic findings in Lemierre's syndrome are integral to its diagnosis.

Case report

A 20-year-old man was admitted to Helen Joseph Hospital with a 2-week history of increasing left-sided facial swelling and mild neck stiffness, followed by a productive cough of 1 week's duration.

On examination he was pyrexial, with mild neck stiffness, left-sided facial swelling and scattered crepitations throughout both lungs on auscultation. ENT and cardiac examinations were documented as normal.

The admission chest X-ray (Fig.1) revealed multiple, bilateral, poorly defined nodules with central breakdown or cavitation in the majority, a small right-sided pleural effusion and cervical soft-tissue prominence. The differential diagnosis at this stage included infectious causes, e.g. tuberculosis, Staphylococcus, Klebsiella and septic emboli, with Wegener's granulomatosis, rheumatoid nodules and metastases less likely.¹⁰

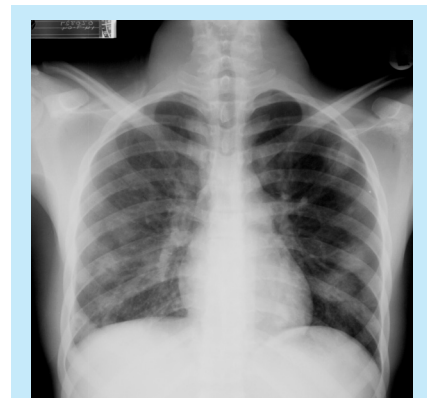


Fig.1 Chest X-ray demonstrates cavitating nodules, a small right-sided pleural effusion and soft-tissue fullness in the neck bilaterally.

The patient had no history of rheumatic heart disease or intravenous drug abuse.

Investigations yielded the following results.

Full blood count revealed a neutrophil leucocytosis (white cell count

CASE REPORT

23.8 x 10⁹/l) and thrombocytopenia (platelets 39 x 10⁹/l). The HIV ELISA was negative and the cerebrospinal fluid specimen was normal. Echocardiography and abdominal ultrasound examinations were also unremarkable. Serial sputum specimens were collected for MC & S and acid-fast bacillus which eventually yielded *Escherichia coli*, whilst blood cultures were contaminated by a coagulase-negative *Staphylococcus* (*Staphylococcus epidermidis*).

Initial treatment was commenced with intravenous cefuroxime and gentamicin, a second-generation cephalosporin and an aminoglycoside respectively, for synergistic broad spectrum β -lactam and gram-negative cover.¹¹

However, the patient remained intermittently pyrexial and described increasing neck pain and dysphagia, prompting further investigation with a pre- and post-contrast axial CT scan of the neck, utilising 100ml Jopamiron 300 at a rate of 2 ml/s (Figs 2 and 3) This revealed a small left-sided parapharyngeal abscess, ipsilateral internal jugular vein (IJV) thrombosis with enhancement of the vessel wall and numerous pulmonary nodules in the visible lung apices, with varying degrees of cavitation. These were situated predominantly in the lung periphery and were associated with a right-sided pleural effusion.

The diagnosis of oropharyngeal abscess with secondary IJV thrombophlebitis and septic emboli was made and metronidazole was added to the existing treatment regimen in order to cover anaerobic pathogens. In addition warfarin anticoagulation was commenced.

Favourable clinical response was obtained, and follow-up chest X-ray and CT scan of the neck after a 3-week

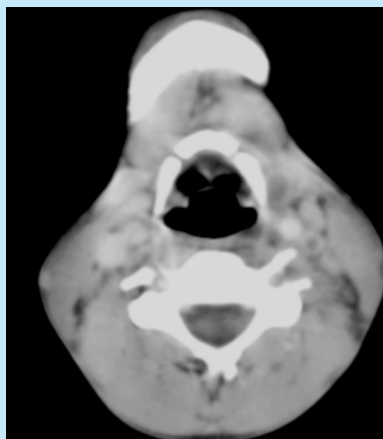


Fig.2. CT scan demonstrates a left IJV hypoattenuating filling defect and a thickened enhancing wall, as well as a small abscess lateral to the hyoid on the ipsilateral side.

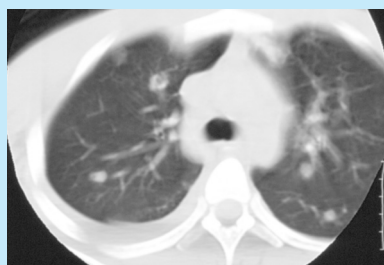
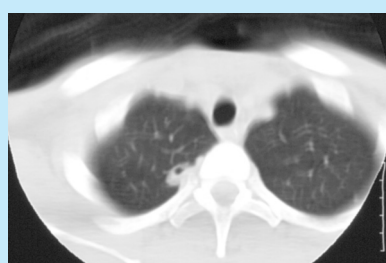

Fig.3. CT scan of the lung apices confirms peripheral cavitating nodules and a right pleural effusion.

interval revealed supporting radiologic improvement. The abscess had resolved, the left IJV remained thrombosed but without mural enhancement, and the pulmonary nodules and pleural effusion were decreasing in number and size (Figs 4 and 5).

Discussion

Whilst gram-negative anaerobes including *Fusobacterium necrophorum* (a commensal organism) are documented as the most common

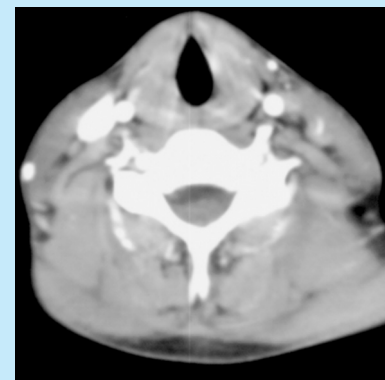


Fig.4. Repeat CT scan of the neck demonstrates ongoing left IJV thrombosis, without the presence of parietal contrast fixation.

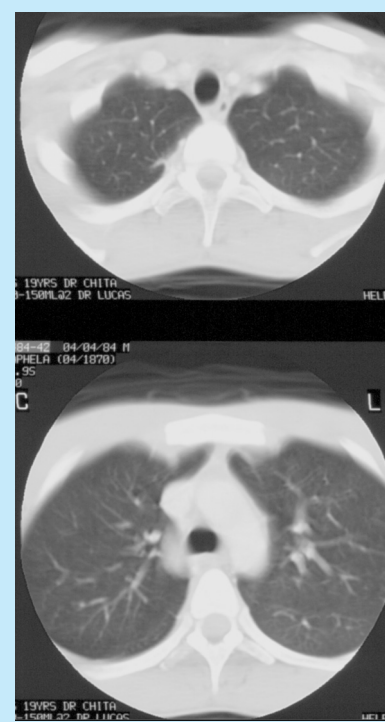


Fig.5. Repeat CT scan of the lung apices confirms resolution of pulmonary nodules and pleural effusion

pathogens associated with Lemierre's syndrome,^{1-3,5-9} postanginal sepsis has been linked to other organisms including *Eikenella corrodens*¹² and *Salmonella*, which may act as an oxygen consumer and facilitate the growth of anaerobes.¹³ We postulate that the *Escherichia coli* (like *Salmonella*, an aerobic, gram-negative, enteric rod) cultured from the sputum of this patient, may have played a similar role in the pathogen-

esis of Lemierre's syndrome.¹⁴

As the offending anaerobe was not definitively cultured, appropriate anaerobic antibiotic therapy was not instituted until the CT investigation documented evidence of oropharyngeal infection and secondary internal jugular vein thrombophlebitis, thus suggesting the diagnosis of Lemierre's.

It is interesting to note that infection of the parapharyngeal space may affect not only the IJV in the carotid space, but also cranial nerves IX - XII and the cervical sympathetic chain, with consequent neurologic signs and symptoms including hoarseness and dysphagia, collectively known as Villaret's syndrome.^{3,15}

Many patients with Lemierre's present with nonspecific signs and symptoms ranging from acute pharyngitis to fever and malaise with the onset of systemic sepsis.³ IJV thrombosis typically causes tenderness and swelling in the neck, along the line of the sternocleidomastoid muscle,⁵ however these findings may be minor and readily overlooked.³ Chest X-ray findings may be normal, or may exhibit nonspecific infiltrates early in the evolution of the syndrome, with the classic features of septic emboli developing only later.^{2,3}

The triad of pharyngitis, a tender or swollen neck and a pulmonary infiltrate, should alert the clinician to the possibility of Lemierre's.² Typical associated radiographic findings may prove integral in the diagnosis.

IJV thrombus may be demonstrated at colour doppler ultrasound as non-compressible clot, frequently associated venous distention, and the absence of phasic flow.³ Contrast CT diagnostic signs include widening of the vein calibre, inhomogeneous or absent luminal opacification, and

parietal contrast fixation.¹⁶

Chest X-ray or CT findings characteristic for septic emboli are multiple, peripheral, round and wedge-shaped opacities that progress rapidly to cavitation, often with associated pleural effusions. These features may be readily appreciated at CT, when the additional finding of a 'feeding vessel' sign (pulmonary artery leading to a nodule) may be seen.^{3,10}

Radiologic investigations may therefore be instrumental in reaching a specific diagnosis of Lemierre's.

Treatment

The management of Lemierre's requires a prolonged course of high-dose, intravenously administered antibiotics, including adequate anaerobic activity.¹³ The role of anticoagulation remains controversial, but may enhance resolution of the source of septic embolisation.³

If signs of sepsis persist, with propagation of the infected thrombus, ligation or excision of the IJV may be required.¹⁷ More recently, hyperbaric oxygen has been investigated as a potential adjunctive therapy in postanginal sepsis.¹⁷

Conclusion

Today morbidity and mortality in Lemierre's syndrome is caused mainly by a lack of knowledge of the syndrome.¹⁸ It follows that awareness of this syndrome on the part of the radiologist should lead to the suggestion of Lemierre's, whether by demonstration of IJV thrombosis by ultrasound or CT, or through findings indicative of septic emboli in the correct clinical setting, as this may expedite the correct treatment. Early directed antibiotic therapy with anaerobic cover is

mandatory to ensure recovery without sequel.

References

- Venkataraman MT, Policar M. Fever, sore throat and pulmonary infiltrates in a 20-year-old man. *Chest* 1997; **112**: 268-270.
- Chironos JA, Lichtstein DM, Garcia J, Tamariz LJ. The evolution of Lemierre syndrome: report of 2 cases and review of the literature. *Medicine* (Baltimore) 2002; **81**: 458-465.
- Screation NJ, Ravenel JG, Lehner PJ, Heitzman ER, Flower CDR. Lemierre syndrome: forgotten but not extinct - report of four cases. *Radiology* 1999; **213**: 369-374.
- Ma M, Jauch EC, Johnson MC. A case of Lemierre's syndrome (abstract). *Eur J Emerg Med* 2003; **10**: 139-142.
- Ritter M, Tebbe J, Battmann A, Gorg C. Lemierre's syndrome: the forgotten disease. An unusual presentation of sepsis (abstract). *Ultraschall Med* 2004; **25**(1):70-73.
- Shaham D, Sklair-Levy M, Weinberger G, Gomori JM. Lemierre's syndrome presenting as multiple lung abscesses (abstract). *Clin Imaging* 2000; **24**: 197-199.
- Golpe R, Marin B, Alonso M. Lemierre syndrome (necrobacillosis) (abstract). *Postgrad Med J* 1999; **75**: 141-144.
- Clarke MG, Kennedy MJ, Kennedy K. Serious consequences of a sore throat (abstract). *Ann R Coll Surg Engl* 2003; **85**: 242-244.
- Auber AE, Mancuso PA. Lemierre syndrome: MRI and CT appearance (abstract). *Mil Med* 2000; **165**: 638-640.
- Dahnert W. *Radiology Review Manual*. 4th ed. Baltimore: Lippincott Williams and Wilkins, 2000.
- Gibbon CJ, Swanepoel CR. *South African Medicines Formulary*. 4th ed. Cape Town: South African Medical Association, 1997.
- Celikel TH, Muthuswamy PP. Septic pulmonary emboli secondary to internal jugular phlebitis (postanginal sepsis) caused by *Eikenella corrodens* (abstract). *Am Rev Respir Dis* 1984; **130**: 510-513.
- Leiberman A, Tovi F, Barki Y, Alkan M. Salmonella neck abscess with jugular vein thrombosis (abstract). *J Laryngol Otol* 1991; **105**: 966-967.
- Murray PR, Baron EJ. *Manual of Clinical Microbiology*. 6th ed. Washington, DC : ASM Press, 1995.
- Boon P, de Reuck J, van de Velde E. Villaret's syndrome due to thrombosis of the jugular vein (abstract). *Clin Neurol Neurosurg* 1990; **92**: 337-341.
- Pereira M, Van Beers B, Pringot J. Diagnosis of internal jugular vein thrombosis by x-ray computed tomography (abstract). *J Radiol* 1985; **66**: 797-800 (Abstract).
- Hodgson R, Emig M, Pisarello J. Hyperbaric oxygen (HBO2) in the treatment of Lemierre's syndrome (abstract). *Undersea Hyperb Med* 2003; **30**: 87-91.
- Gong J, Garcia J. Lemierre's syndrome (abstract). *Eur Radiol* 1999; **9**: 672-674.