

Proceedings of Sultan Qaboos University Clinical-Pathological Conferences

2009–2010

وقائع مؤتمرات علم الأمراض السريري
في جامعة السلطان قابوس

2010–2009

Pulmonary Sarcoidosis: One diagnosis, two different presentations

B Jayakrishnan,¹ Fatma Ben Abid,¹ Ana Maria A Serrano,² Aisha Al-Hamdani³*Departments of ¹Medicine, ²Family Medicine & Public Health and ³Pathology, Sultan Qaboos University Hospital, Muscat, Oman. Email: drjayakrish@hotmail.com*

Even 140 years after the initial description, the aetiology of sarcoidosis, a multisystem disorder, remains elusive, the diagnostic tests remain largely nonspecific and treatment produces inconsistent results.

Case One: A 69 year-old Omani female with hypertension, diabetes mellitus, depression and blindness was referred for evaluation of bilateral opacities on a chest radiograph. She had a three-month history of dry cough, exertional breathlessness, chest discomfort and weight loss. She denied any history of fever, night sweats, haemoptysis or recent travel. Clinical examination revealed a few small lymph nodes in the axillae. Basic blood tests, including serum calcium, were normal. The serum angiotensin converting enzyme (SACE) level was also normal. The sputum smear was negative for acid fast bacilli (AFB) by direct smear. The Mantoux test was negative. The chest radiograph showed bilateral parenchymal infiltrates. A computed tomography (CT) of the chest revealed bilateral extensive perihilar airspace consolidation with significant mediastinal lymph nodes. Spirometry results were as follows: forced expiratory volume 1 (FEV1) - 0.66 L (37%), forced vital capacity (FVC) - 1.01L (47%), FEV1/FVC - 65%. A bronchoscopy showed hyperaemic mucosa with diffuse granular changes and a few nodular lesions. An endobronchial biopsy revealed features of non-caseating granuloma confirming a diagnosis of sarcoidosis.

Case Two: A 42 year-old Omani female presented with a dry cough, generalised itching and extreme tiredness of 6 months duration. On examination, there were well demarcated hyperpigmented brown nodular skin lesions over the breast, abdomen, lower back and both thighs. Some showed central ulceration with healing and post-inflammatory hypopigmented and hyperpigmented patches and superficial mild depressed scars. Routine blood tests, including serum calcium and SACE level, were normal. The Mantoux test was positive, 24 mm. The chest radiograph and computed tomography (CT) scan revealed bilateral hilar and mediastinal lymphadenopathy. Pulmonary function test results were as follows: FEV1- 1.87 L (78%), FVC - 2.29 L (81%), FEV1/FVC - 82%, carbon monoxide diffusing capacity (DLCO) -75%, and carbon monoxide transfer coefficient (KCO) - 96%. The bronchoscopy did not show any abnormality; the bronchoalveolar lavage and sputum were negative for AFB by stain and culture. Skin lesions were biopsied, as well as a mediastinoscopy and mediastinal lymph node biopsy. Both skin and lymph node biopsies showed non-caseating granulomas suggestive of sarcoidosis.

Both the patients received prednisolone leading to symptomatic and radiological improvement. Since the Mantoux test was positive, the second patient received anti tuberculosis treatment prior to the initiation of steroids.

Despite advances in the knowledge of the immunopathogenesis of sarcoidosis, no single aetiologic agent or genetic locus has been clearly identified in the development of the disease.¹ The disease varies in incidence and presentation among geographical regions.² Any organ can be involved, the most commonly affected sites being the lungs (approximately 90% of patients), lymph nodes, skin, eyes, and the liver. Cutaneous involvement is common presenting as macular, nodular, maculopapular, ulcerative or plaque like lesions; it can also present as verrucous, ichthyosiform, hypomelanotic, or psoriasiform lesions.³ They can be divided into specific lesions and nonspecific lesions based on the characteristics and histology,⁴ the classic specific and nonspecific lesions being Lupus pernio and Erythema nodosum respectively. Spontaneous remission is common in sarcoidosis so not all patients require treatment. Generally, treatment is indicated when there are debilitating symptoms or evidence of significant or progressive end-organ damage. Glucocorticoids are the commonest treatment agents for pulmonary sarcoidosis. Refractory disease may require other agents such as immunosuppressive, cytotoxic, antimalarial drugs or anti-tumour necrosis factor (TNF) antibodies.

REFERENCES

1. Baughman RP, Culver DA, Judson MA. Concise Review of Pulmonary Sarcoidosis. *Am J Respir Crit Care Med* 2010, Oct 29. [Epub ahead of print]
2. Behbehani N, Jayakrishnan B, Khadadah M, Farrah Y, Hawa H. Clinical Presentation of Sarcoidosis in a Mixed Population in the Middle East. *Respir Med.* 2007; 101:2284–8.
3. Macrophage/Monocyte disorders In: James WD, Berger TG, Elston DM, Eds. *Andrews' Diseases of skin, Clinical Dermatology.* 10th ed. Philadelphia: W.B. Saunders, 2005. Pp. 708–14.
4. Rose AS, Tielker MA, Knox KS. Hepatic, ocular, and cutaneous sarcoidosis. *Clin Chest Med* 2008; 29:509–24.

These cases were presented at the Sultan Qaboos University Clinical-Pathological Conference on 7th April 2010 with the title "To Be or not To Be..." The title represents the uncertainties in the aetiology, diagnosis and the treatment of sarcoidosis as well as the diagnostic confusion in differentiating it from tuberculosis.

Girl with T-Cell Leukaemia and Severe Central Nervous System Involvement

Yasser Wali,¹ *Mathew Zachariah² Ismail El Beshlawi,² Nancy Reyes² and Nasser S. Al-Hajari²

¹Department of Child Health, College of Medicine & Health Science Sultan Qaboos University, Muscat, Oman. Departments of ¹Child Health, ²Nursing, ³Physiotherapy, Sultan Qaboos University Hospital, Muscat, Oman. Email: mathewz@squ.edu.om

Remarkable advances have been achieved in the treatment of acute lymphoblastic leukemia (ALL) in children in the last decades. However, still 20% of children ultimately relapse, and the cure rate after relapse is only 25% to 40%. T-cell acute lymphoblastic leukemia (T-ALL) accounts for 10% to 15% of newly diagnosed cases of childhood acute lymphoblastic leukemia (ALL). Age, total white blood cell count at diagnosis, immunophenotype, chromosomal aberrations, speed of treatment response, minimal residual disease, are all very important factors in determining the prognosis of the diseases. An eight year-old Omani girl was admitted to Sultan Qaboos University Hospital (SQUH) referred from a peripheral hospital with fever and poor school performance of more than one month's duration. The child had developed convulsions, septic shock and was ventilated and was therefore transferred to SQUH as a suspected case of leukaemia. In SQUH she was labelled as T-Cell leukaemia with central nervous system (CNS) involvement and was completely aphasic. Despite repeated magnetic resonance imaging (MRI) brain scans that confirmed white matter changes and demyelination initially and widely extended on repeated imaging, her cerebrospinal fluid (CSF) was repeatedly clear. After successful induction with a POG 9404 T3 protocol, she had a severe episode of febrile neutropenia that rapidly progressed to septic shock, deteriorating neurological status and respiratory distress. She had recurrent episodes of febrile neutropenia, sepsis with ELBS E.Col , coagulase negative Staphylococcus and Candida. Her condition deteriorated with severe mucositis and respiratory distress which needed an emergency tracheostomy and later she was put on mechanical ventilation. She remained in very critical situation for 4 weeks and she was labelled as DNR (Do Not Resuscitate) status. Her chemotherapy was withheld for two and a half months due to her grave clinical condition. Of interest, she maintained her remission status on a repeat bone marrow aspiration; however, she had extensive haemophagocytosis (secondary haemophagocytic lymphohistiocytosis [HLH]) that needed to be treated with partial induction for 6 weeks (HLH 2004). After all these stormy events child ended up in a devastating state with severe weight loss (skin on bones), aphasia, and inability to walk. With extensive nursing support and physiotherapy, she improved remarkably, started to gain weight, her speech recovered and the tracheostomy was closed. Her MRI brain scan was almost normal. After one year of an uneventful course of maintenance chemotherapy, she suddenly developed facial palsy. Other CNS examinations were normal and the CSF was still clear. Unfortunately, her bone marrow showed 80% blasts of the initial phenotype confirming a combined bone marrow and CNS relapse. The brain images were obviously normal. She was started on UK ALL relapse protocol and planned for early bone marrow transplantation. During the induction phase she had another episode of febrile neutropenia, herpes simplex virus lesions that further deteriorated and progressed to septic shock. After a long severe prolonged course she expired. Everyone has got only one life; however, in our case she was labelled as DNR once and all the treating team members lost hope that she would survive. Such a courageous young girl made it through and came out of this tragedy learning again how to talk and walk.

This case was presented at the Sultan Qaboos University Clinical-Pathological Conference on 5th May 2010 with the title "You Only Live Twice"

Between the Loins and the Ribs - A case of a germ cell tumour

Ibtisam H. Al-Shuaili,¹ Aisha Al-Hamdani,² Sinan Al-Azzawi,³ Ibrahim Inuwa⁴ and Ikram A Burney¹

Departments of ¹Medicine, ²Pathology, ³Radiology & Molecular Imaging, Sultan Qaboos University Hospital, Muscat, Oman; ⁴Department of Human & Clinical Anatomy, College of Medicine & Health Science Sultan Qaboos University, Muscat, Oman. Email: ibtisamsh@hotmail.com

A 21 year-old boy, previously well, presented at Sultan Qaboos University Hospital, Oman, with a 2-month history of low grade fever, malaise, weight loss of about 3–4 kg, and haemoptysis. There was no history of shortness of breath, palpitation, recent travel, or contact with patients suspected to have tuberculosis or HIV. The physical examination was unremarkable apart from a dull percussion note with reduce breath sounds on left side of the chest. Vital signs were temperature 38 °C, pulse rate 128 bpm, respiratory rate 14/min, blood pressure 97/50 mmHg. A blood investigation revealed mild anaemia with an Hb of 9 g/dl, normochromic normocytic, and normal white cell and platelet counts. The coagulation profile, urea and electrolytes, liver function tests and the bone profile were all within the normal limits. A chest X-ray was done and reported a large mediastinal mass. A differential diagnosis of a germ cell tumour was entertained and a serum alfa-fetoprotein (AFP) was found to be markedly elevated at 20,142 KIU/L, whereas, serum lactate dehydrogenase (LDH) was

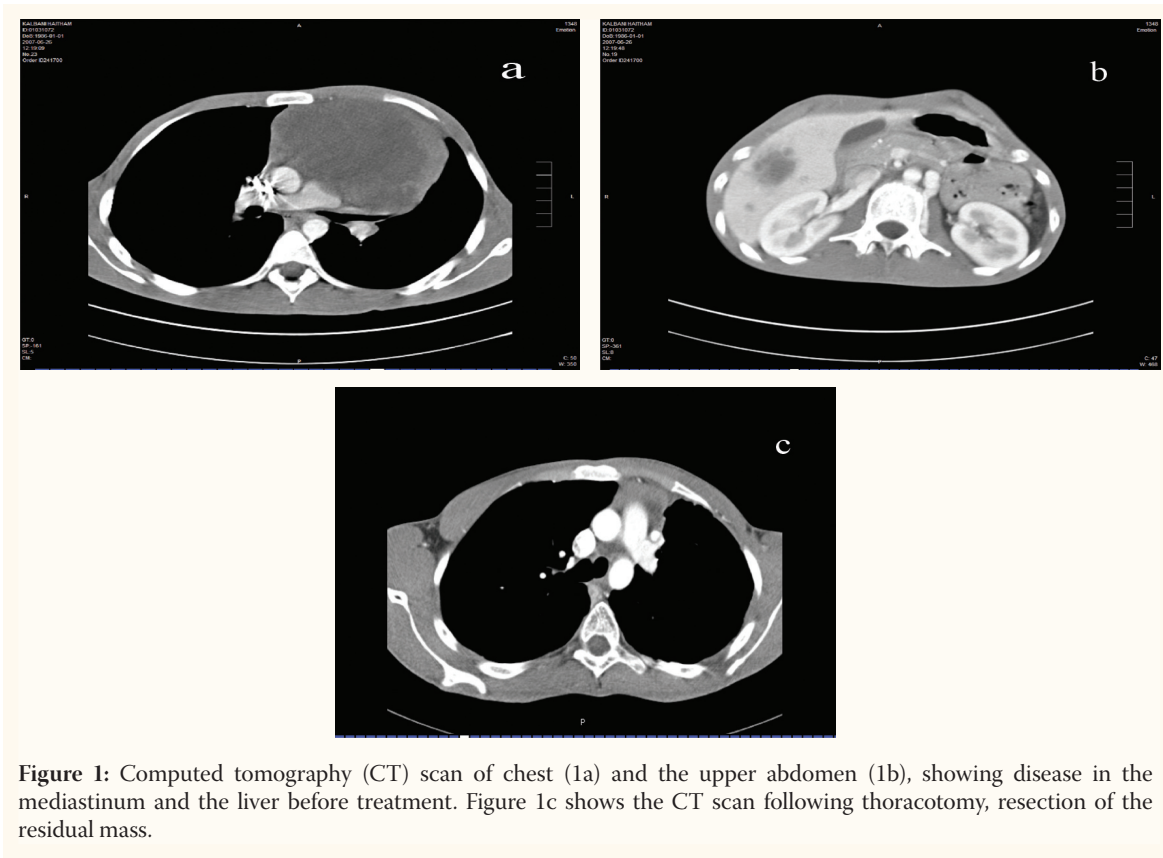


Figure 1: Computed tomography (CT) scan of chest (1a) and the upper abdomen (1b), showing disease in the mediastinum and the liver before treatment. Figure 1c shows the CT scan following thoracotomy, resection of the residual mass.

minimally elevated to 698 U/L (up to 248 IU/L). Serum and urine β -human chorionic gonadotropin (HCG) were within the normal limits. An ultrasound scan of the testis was unremarkable, and a computed tomography scan of chest [Figure 1a] showed a large ill-defined lobulated anterior mediastinal mass in the superior mediastinum, extending into the left hemithorax. The mass was seen displacing the mediastinal vascular structures to the right and posteriorly, with significant compression of the left main pulmonary artery and possible infiltration of the main pulmonary artery. The left upper lobe bronchus was collapsed with loss of volume of the left upper lobe. The liver was found to be enlarged and showed numerous focal lesions predominantly in the right lobe with central necrosis and thick enhancing rims [Figure 1b]. A biopsy revealed an extensively necrotic poorly differentiated malignant neoplasm with the immunohistochemical profiles in keeping with mixed germ cell tumor. The patient was treated with combination chemotherapy consisting of bleomycin, etoposide and cisplatin (BEP). The tumour marker response is shown in Figure 2. Because of a lack of marker normalisation after three cycles of the combination chemotherapy, the treatment was changed to a combination of vinblastine, ifosfamide and cisplatin,

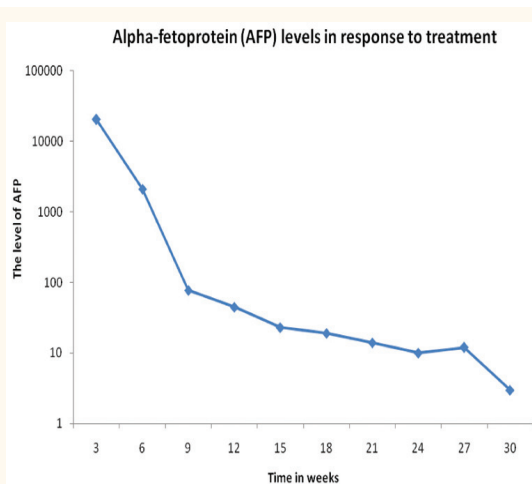


Figure 2: Alpha-fetoprotein (AFP) levels in response to treatment and over time. The X-axis shows time in weeks, and the Y axis shows the level of AFP on a logarithmic scale. BEP = bleomycin, etoposide and cisplatin; VeIP = vinblastine, ifosfamide and cisplatin; GemOx = gemcitabine and oxaliplatin.

which he received four cycles. The treatment was further changed to third line chemotherapy consisting of gemcitabine and oxaliplatin because of lack of marker remission. Owing to no further marker decline, the patient was referred for a positron emission tomography (PET) scan, which revealed increased uptake in the mediastinum, but not in the liver. The patient underwent thoracotomy with resection of the residual mass lesion, the histopathology of which showed mainly necrosis. Following the thoracotomy, the alpha-fetoprotein (AFP) dropped to normal limits, and the patient has been in continuous complete remission since March 2008.

This case was presented at the Sultan Qaboos University Clinical-Pathological Conference in DATE? April 2009 with the title "Between the Loins and the Ribs".