

Laparoscopic Reimplantation for Single-System Ectopic Ureter

Abbas Basiri,¹ Faramarz Mohammad Ali Beigi,² Hamidreza Abdi,¹ Nastaran Mahmoudnejad¹

Keywords: urogenital abnormalities, ectopic ureter, laparoscopy, reimplantation

Urol J. 2007;4:174-6.
www.uj.unrc.ir

INTRODUCTION

Ureteral anomalies, ectopic ureter being one of them, are of the most important urogenital abnormalities because they directly affect kidney function.⁽¹⁾ Several techniques have been used for treatment of ectopic ureter. The goal of obstruction relief can be achieved by either ureteropyelostomy or common sheath ureteral reimplantation for a duplicated system, or reimplantation for a single system.⁽¹⁾ Heminephrectomy and ureteropyelostomy are well described elsewhere, but several technical points deserve emphasis.⁽¹⁾ Laparoscopic procedures putatively offer reduced morbidity due to less postoperative pain, earlier return of gastrointestinal function, earlier

discharge, and a quicker return to work. To our knowledge laparoscopic reimplantation for ectopic ureter has not been reported, yet. We performed laparoscopic ureteral reimplantation on a 29-year-old man with ectopic ureter.

CASE REPORT

A 29-year-old man was referred with dysuria, frequency, postvoid dribbling, and left flank pain. Urinalysis and urine culture showed urinary tract infection (UTI). After the treatment of UTI, ultrasonography revealed severe left kidney hydroureteronephrosis and partial reduction in parenchymal thickness of the left kidney. A single system was also confirmed on intravenous urography (Figure 1).

¹Department of Urology, Shaheed Labbafinejad Medical Center and Urology and Nephrology Research Center, Shaheed Beheshti Medical University, Tehran, Iran
²Department of Urology, Shahrekord University of Medical Sciences, Shahrekord, Iran

Corresponding Author:
Abbas Basiri, MD
Urology and Nephrology Research Center, 9th Bostan, Pasdaran Ave, Tehran, Iran
Tel: +98 21 2256 7222
Fax : +98 21 2256 7282
E-mail: basiri@unrc.ir

Received October 2006
Accepted May 2007

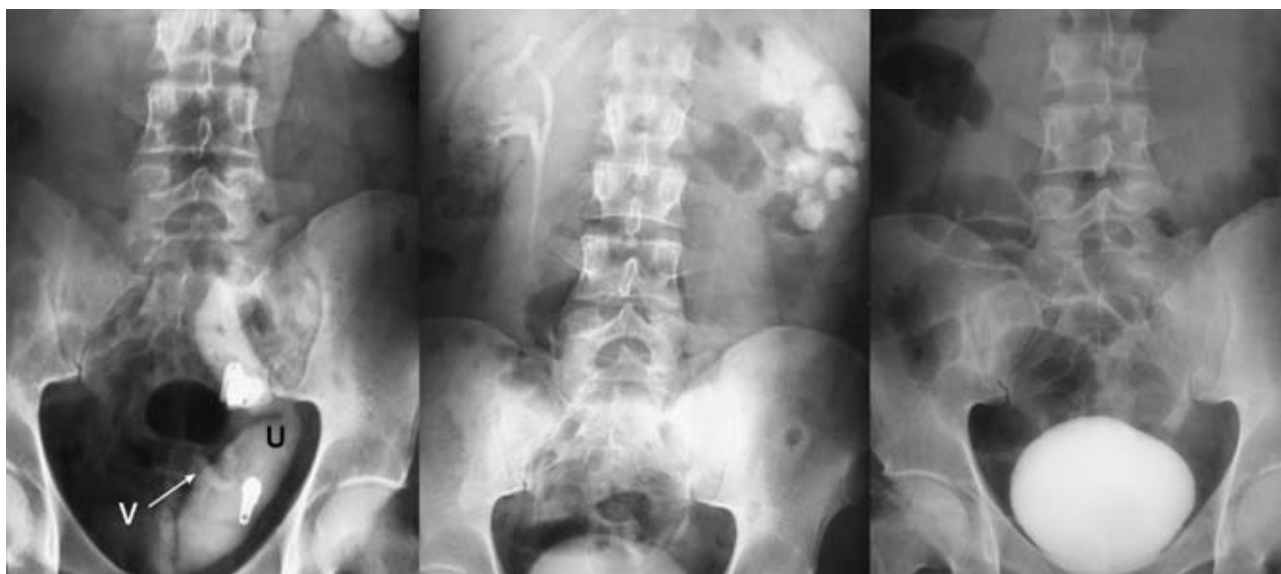

Figure 1. Left, Preoperative intravenous urography revealed hydroureteronephrosis of the left kidney with reflux of the contrast medium into the vas deferens. Middle, Significant reduction of hydroureteronephrosis and ureteral diameter was revealed by intravenous urography postoperatively. Right, Postoperative voiding cystourethrography showed no vesicoureteral reflux. V indicates vas deferens and U, ureter.

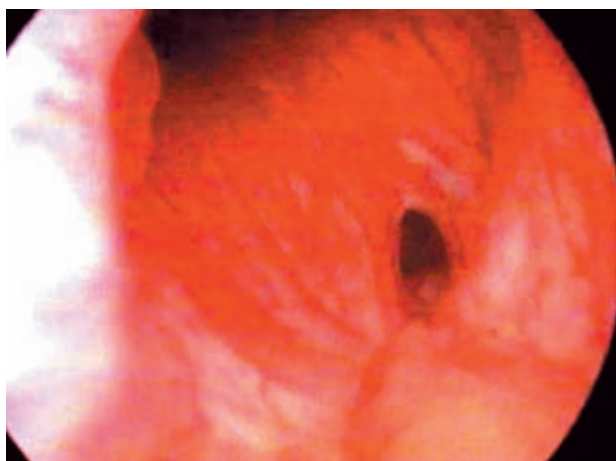


Figure 2. Ectopic orifice of the ureter is shown in the posterior urethra above the verumontanum.

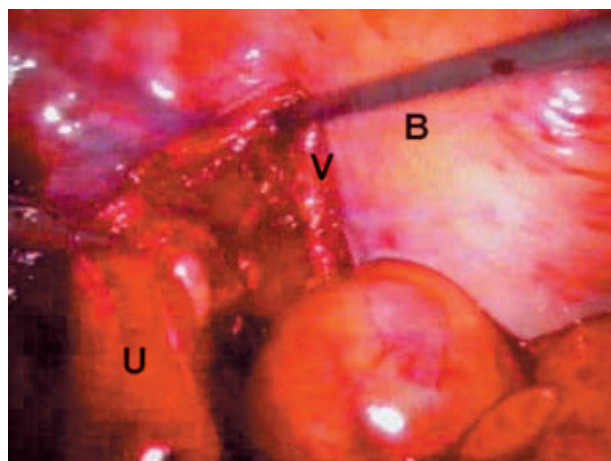


Figure 3. The ureter was released behind the bladder below the left vas deferens. V indicates vas deferens; U, ureter; and B, bladder.

On Technetium Tc 99m dimercaptosuccinic acid scan, function of the left kidney was acceptable. Diagnostic cystourethroscopy was performed. The bladder and the right ureteral orifice were normal, but on the left side, the ureteral orifice was not seen in its normal position in the trigone. After a more careful evaluation, the left ureteral orifice was seen in the prostatic urethra about 3 mm above the verumontanum (Figure 2). Retrograde ureteral catheterization was then performed which confirmed the same findings (a single urinary tract system). No other abnormality was seen. The place of the ectopic ureter was confirmed to be in the posterior urethra. Reflux into the vas deferens and seminal vesicle was observed during voiding cystourethrography. The patient underwent intraperitoneal ureteral reimplantation with the diagnosis of left ectopic ureter.

The patient was secured in the left flank position. One port was inserted through the umbilicus for the camera (10 mm), another was inserted through the left lateral rectus muscle at the level of the umbilicus (5 mm), and the last port was inserted through the midline suprapubic space 6 cm below the umbilicus for the instruments (5 mm). First, the terminal colon was mobilized and the distal part of the ureter was released, clamped, and cut, 2 cm below the vas deferens (Figure 3). Regarding the dilatation of the ureter, ureteral spatulation was not necessary. Catheterization was performed using a 10-F stent (Figure 4). To perform extravesical Lich-Gregoir ureterovesical anastomosis, the bladder tunnel was created using a hook cautery with the semifull bladder

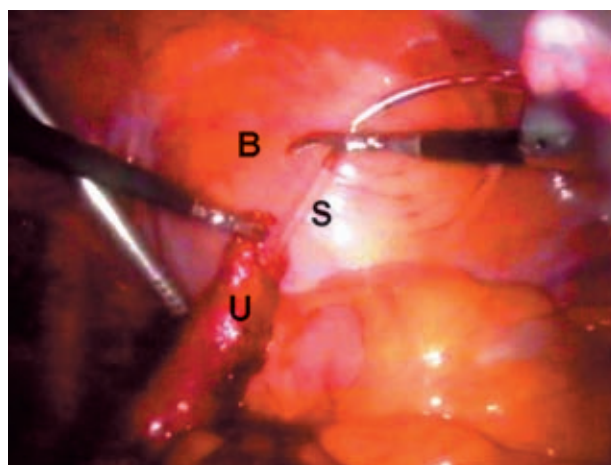


Figure 4. The ureter was cut and a ureteral stent was inserted for anastomosis to the bladder. S indicates stent; U, ureter; and B, bladder.

in the lateral and anterior aspects. On the distal part, mucosa of the bladder was opened, ureter-bladder anastomosis was performed separately with vicryl 4-0, and a catheter was placed.

The operative time was 150 minutes and no complication occurred intraoperatively or postoperatively. Oral feeding was started the day after the operation and 5 days later, the patient was discharged. One month postoperatively, the stent was removed and 6 months later, intravenous urography and voiding cystourethrography revealed no obstruction or reflux (Figure 1).

DISCUSSION

The prevalence of ectopic ureter is not well determined. Campbell reported 10 cases among 19046 autopsies in children.⁽²⁾ Ectopic ureters appear

2 to 12 times more frequently in women.⁽¹⁾ Of all ectopic ureteral orifices, 80% are associated with a duplicated collecting system. In women, more than 80% of the collecting systems are duplicated, but in men, most ectopic ureters drain single systems.⁽³⁾ In men, the most prevalent site of ectopic ureter is the posterior urethra (47%).⁽²⁾

Patients with ectopic ureters draining into the posterior urethra often suffer from urgency and frequency and may have severe obstruction. Another prevalent complication is UTI. Drainage into the genital tract involves the seminal vesicles 3 times more frequent than the ejaculatory duct and the vas deferens together.^(4,5) Most of the ectopic ureters including the upper pole ureters and single systems are accompanied by the least functional kidneys; therefore, upper pole nephrectomy or nephrectomy for single collecting systems is indicated.⁽¹⁾

Kidney function is one of the most important factors in selection of the treatment choice. In some patients, especially with single systems, kidney preservation is important. In such patients, ureteropyelostomy and common sheath reimplantation (in double systems) or solitary reimplantation (in single systems) is helpful in the treatment of obstruction. Laparoscopic techniques have been performed in nephrectomy or heminephrectomy of nonfunctional kidneys; however, laparoscopic reimplantation has not been reported in single systems so far. Modified Lich-Gregoir technique has been successfully used for laparoscopic ureteral reimplantation in the treatment of vesicoureteral reflux.⁽⁶⁾ Ureteral reimplantation has also been reported in the treatment of ureterovaginal fistula.⁽⁶⁾ We performed laparoscopic reimplantation of the ectopic ureter which is, to our knowledge,

the first report worldwide. Laparoscopic techniques are accompanied by less morbidity due to less pain, earlier return of gastrointestinal function, earlier discharge of the hospital and return to work, adequate view during the surgery, excellent cosmetic results, and minimal abdominal incision. These are of the most important reasons for choosing laparoscopic approach in the treatment of these patients. Since this is the first report of laparoscopic reimplantation of an ectopic ureter, undoubtedly long-term follow-up and study of more cases are needed to consider it as the procedure of choice for surgical reimplantation of ectopic ureter.

CONFLICT OF INTEREST

None declared.

REFERENCES

1. Richard N, Schlüssel RN, Retik AB. Ectopic ureter, ureterocele and other anomalies of the ureter. In: Walsh PC, Retik AB, Vaughan ED Jr, et al, editors. *Campbell's urology*. 8th ed. Philadelphia: WB Saunders; 2002. p. 2007-2013.
2. Campbell MF. Anomalies of the ureter. In: Campbell MF, Harrison JH, editors. *Urology*. 3rd ed. Philadelphia: WB Saunders; 1970. p. 1512.
3. Schulman CC. The single ectopic ureter. *Eur Urol*. 1976;2:64-9.
4. Sullivan M, Halpert L, Hodges CV. Extravesical ureteral ectopia. *Urology*. 1978;11:577-80.
5. Squadrito JF, Rifkin MD, Mulholland SG. Ureteral ectopia presenting as epididymitis and infertility. *Urology*. 1987;30:67-9.
6. Ramalingam M, Senthil K, Venkatesh V. Laparoscopic repair of ureterovaginal fistula: successful outcome by laparoscopic ureteral reimplantation. *J Endourol*. 2005;19:1174-6.