

Unusual Migration of Intrauterine Device into Bladder and Calculus Formation

Mohammad Rajaie Esfahani,¹ Ahmadreza Abdar²

Keywords: bladder calculus, foreign body, intrauterine device, bladder perforation

Urol J (Tehran). 2007;4:49-51.
www.uj.unrc.ir

INTRODUCTION

Foreign bodies in the bladder can result in recurrent urinary tract infection (UTI), hematuria, calculus formation, and pelvic pain.⁽¹⁾ Instruments used for surgical and endoscopic procedures or masturbation may migrate into the bladder. Intrauterine device (IUD) is a safe and cost-effective means of contraception.⁽²⁾ However, since its application, many complications including dysmenorrhea, hypermenorrhea, pelvic infections, pregnancy, spontaneous abortion, uterine rupture, and migration into the neighboring organs have been reported.^(3,4) Migration of the IUD into the bladder has been rarely reported in the literature. We report a case of IUD migration into the bladder and calculus formation.

CASE REPORT

A 28-year-old woman with a history of 4 deliveries presented to our urology clinic of Fatima-Zahra Hospital in Najafabad, Iran, with dysuria, frequency, hematuria, and disseminated pelvic pain especially during the menstruation period since 4 years earlier. She had a history of cystocele and rectocele repairs, and experienced recurrent UTI after the surgery without fever and chills not sufficiently responding to antibiotic therapy. Intrauterine device had been inserted 8 years earlier. Four years

after the insertion of the IUD, the string of the device had not been detected by the gynecologist and it was assumed that the IUD had been exploded spontaneously. Thereafter, oral contraceptive had been started.

On physical examination, tenderness was noted in the suprapubic area and with movements of the cervix and the anterior wall of the vagina. Urinalysis was indicative of pyuria and hematuria, and urine culture was positive for *Escherichia coli*. On ultrasonography, a large bladder calculus and severe inflammation of the bladder mucosa were reported. The bladder calculus was also detected by abdominal radiography and an IUD was seen in the pelvis, as well (Figure 1). Cystoscopy was performed twice and revealed local inflammation and severe swelling in the left side of the bladder, but the bladder calculus was not seen beyond the inflammation. The patient refused computed tomography; therefore, a second ultrasonography was done and the IUD was seen in an abnormal position adjacent to the calculus. According to the findings of the abdominal radiography and ultrasonography, suprapubic cystolithotomy was performed. A 2-cm bladder calculus was detected in the upper left side of the bladder. An IUD which was stuck to the calculus was also removed intact (Figure 2), but it resulted in a rupture

¹Department of Urology, Kashani Hospital, Shahrekord University of Medical Sciences, Shahrekord, Iran
²Department of Urology, Fatima-Zahra Hospital, Najafabad, Iran

Corresponding Author:
Mohammad Rajaie Esfahani, MD
Department of Urology, Kashani Hospital, Shahrekord, Iran
Tel: +98 913 382 0669
E-mail: dr_mrajaei@yahoo.com

Received April 2006
Accepted October 2006

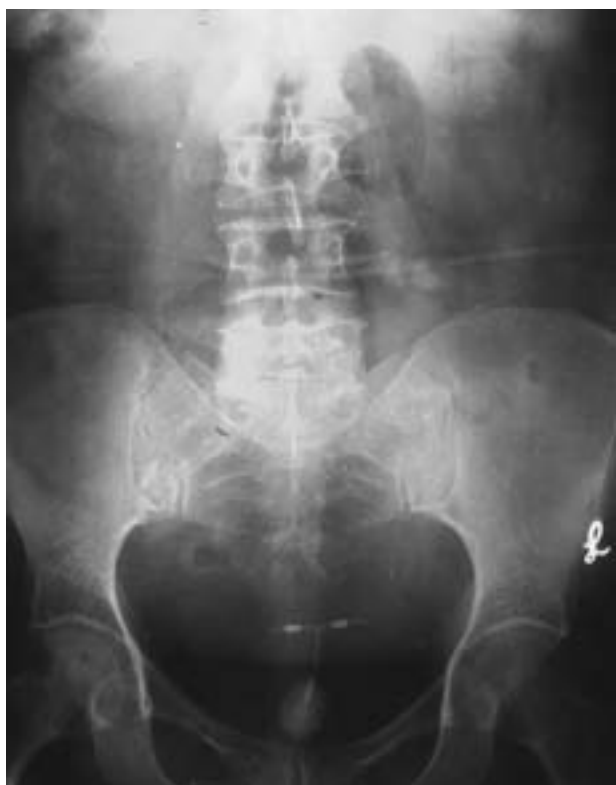

Figure 1. Plain abdominal radiography revealed a large calculus in the bladder and an intrauterine device.

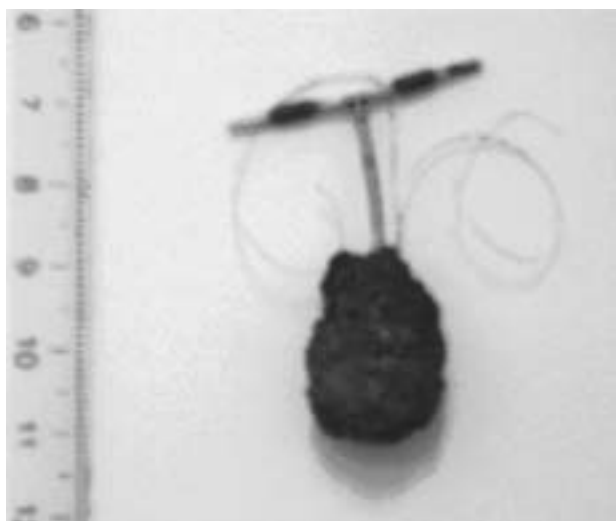


Figure 2. A 2-cm calculus adhered to an intrauterine device was removed by suprapubic cystolithotomy.

in the bladder wall. The rupture was internally repaired in 2 layers by catgut sutures. A urethral catheter was fixed for 2 weeks. The patient had an uneventful postoperative period without any special complication.

DISCUSSION

Intrauterine device is an accepted worldwide contraceptive instrument. However, a very small proportion of sexually active women in the United State use the IUD because of the fear of its complications.⁽⁵⁾ Its complications include UTI, spontaneous abortion, and uterine rupture.⁽⁶⁾ Migration of the IUD into the neighboring organs or the abdominal cavity is a rare complication. In a review of 165 cases, the omentum, rectosigmoid, peritoneum, bladder, appendix, small bowel, adnexa, and iliac vein were the location of migrated IUD, in 45, 44, 41, 23, 8, 2, 1, and 1 patients, respectively.⁽⁷⁾ These patients generally present with the chief complaint of not finding the device string. They may be asymptomatic or have abdominal and pelvic signs and symptoms, based on the severity of the problem and location of the IUD. Copper IUDs result in abundant inflammatory reaction and adhesion.⁽⁸⁾ Uterine rupture has been reported with a frequency of 1:350 to 1:2500 in women with IUD.⁽⁹⁾ Factors raising suspicion of uterine rupture include insertion of the device by inexperienced persons, inappropriate position of the IUD, susceptible uterine wall due to multiparity, and a recent abortion or pregnancy.⁽¹⁰⁾ All IUDs are radio-opaque; therefore, plane abdominal radiography may be used for detection of the IUD as well as ultrasonography and CT scan. Transvaginal ultrasonography provides the best view for locating the IUD, but it restricts the space for its simultaneous removal.⁽⁸⁾ Magnetic resonance imaging is not contraindicated in copper IUDs.⁽⁸⁾

Even if the IUD migration is asymptomatic, it should be removed for prevention from the complications such as pelvic abscess, bladder or intestinal rupture, and adhesion. Migration of the IUD into the bladder and formation of a secondary calculus is an uncommon complication.⁽¹¹⁾ Only 31 cases of complete or incomplete migration of IUD into the bladder and calculus formation have been reported in the literature by 2006.^(11,12) Although the process of IUD migration into the bladder is gradual and accompanies with complications such as cystitis, hematuria, and pelvic pain, most of the perforations occur at the time of insertion.⁽⁵⁻¹³⁾

In summary, the IUD should be correctly inserted by an experienced person. A proper selection of patient and a thorough history and physical

examination is crucial. If uterine rupture is suspected, ultrasonography should be performed to determine the probable location of the rupture. Women should be informed of the potential complications and be suggested to check the device string regularly. If the string is not found, abdominal radiography is required even in asymptomatic patients. In women with IUD who presents with lower urinary tract symptoms, migration of the IUD into the bladder, although very uncommon, should not be neglected.

CONFLICT OF INTEREST

None declared.

REFERENCES

1. Tan LB, Chiang CP, Huang CH, Chou YH, Wang CJ. [Foreign body in the urinary bladder]. *Gaoxiong Yi Xue Ke Xue Za Zhi*. 1993;9:604-9. Chinese.
2. Cheng D. The intrauterine device: still misunderstood after all these years. *South Med J*. 2000;93:859-64.
3. Yalcin V, Demirkesen O, Alici B, Onol B, Solok V. An unusual presentation of a foreign body in the urinary bladder: a migrant intrauterine device. *Urol Int*. 1998;61:240-2.
4. Sehgal A, Gupta B, Malhotra S. Intravesical migration of copper-T. *Int J Gynaecol Obstet*. 2000;68:265-6.
5. Stubblefield PG. Family planning. In: Berek JS, editor. *Novak's gynecology*. 13th ed. Philadelphia: Lippincott Williams & Wilkins; 2002. p. 231-93.
6. Dietrick DD, Issa MM, Kabalin JN, Bassett JB. Intravesical migration of intrauterine device. *J Urol*. 1992;147:132-4.
7. Kassab B, Audra P. [The migrating intrauterine device. Case report and review of the literature]. *Contracept Fertil Sex*. 1999;27:696-700. French.
8. Speroff L, Fritz MA. Intrauterine contraception. The IUD. In: Speroff L, Fritz MA, editors. *Clinical gynecologic endocrinology and infertility*. 17th ed. Philadelphia: Lippincott Williams & Wilkins; 2005. p. 975-95.
9. Ohana E, Sheiner E, Leron E, Mazor M. Appendix perforation by an intrauterine contraceptive device. *Eur J Obstet Gynecol Reprod Biol*. 2000;88:129-31.
10. Junceda Avello E, Gonzalez Torga L, Lasheras Villanueva J, De Quiros A GB. Uterine perforation and vesical migration of an intrauterine device. Case observation. *Acta Ginecol (Madr)*. 1977;30:79-86.
11. Demirci D, Ekmekcioglu O, Demirtas A, Gulmez I. Big bladder stones around an intravesical migrated intrauterine device. *Int Urol Nephrol*. 2003;35:495-6.
12. Gonzalvo Perez V, Lopez Garcia LM, Aznar Serra G, et al. [Uterine perforation and vesical migration of intrauterine device]. *Actas Urol Esp*. 2001;25:458-61. Spanish.
13. Woods M, Wise HM Jr. An unusual cause of cystolithiasis: a migrant intrauterine device. *J Urol*. 1980;124:720-1.