

# Erratum

## Laparoscopic Adrenalectomy: A Report of the First Experience in Iran

SIMFOROOSH N\*, AHMADNIA H, ZIAEE AM, MORADI M

*Urology/Nephrology Research Center, Shaheed Labbafinejad Medical Center, Shaheed Beheshti University of Medical Sciences, Tehran, Iran*

*Volume 1, Number 2, pages 77-81: Some technical errors mainly due to Persian to English translation were unnoticed and the published version was not the edited one. The correct version of the article follows. The publisher regrets this error.*

### ABSTRACT

**Purpose:** To report the first experience in laparoscopic adrenalectomy and to study its efficacy and safety in the treatment of different adrenal diseases.

**Materials and Methods:** From March 1997 to July 2001, 11 patients underwent laparoscopic adrenalectomy through transperitoneal approach, five of whom were males and 6 were females. Their mean age was 35.5 (range 28 to 52) years. Lesion was located on the left side in 6 patients and on the right side in 5. All necessary evaluations were done preoperatively including CT scan, MRI, MIBG scan, and endocrine tests such as ACTH, cortisol, mineralocorticoid, 17-hydroxyprogesterone, and urinary VMA. Three (5, 10, and 12 mm) trocars were used in left laparoscopic adrenalectomy and three or four (12, 10, 5, and 5 mm) trocars were applied in right laparoscopic adrenalectomy. All the patients were followed up for three months with physical examination and paraclinical tests.

**Results:** Mean operative time (including anesthesia and surgery) was  $205 \pm 65.95$  (range 130 to 310) minutes. No significant difference was seen between the operative time in the left side and the right side adrenalectomy ( $p=0.5$ ). Mean hospitalization was  $5.54 \pm 3.4$  (range 3 to 15) days. Mean size of mass was  $5.45 \pm 1.7$  (range 2 to 8) cm. Blood transfusion was performed in 2 patients and open surgery was conducted for one because of extensive adhesions. No mortality was reported. During a 3-month follow-up, hormonal tests and blood pressure were normal for all the patients, with no medical treatment being required.

**Conclusion:** Our study demonstrated that transperitoneal laparoscopic adrenalectomy is an effective and safe approach in the treatment of adrenal masses with the least morbidity.

**KEY WORDS:** adrenal neoplasm, laparoscopy, adrenalectomy

### Introduction

The first laparoscopic adrenalectomy was performed in 1992 by Ganger.<sup>(1-3)</sup> This approach was

quickly developed because of less hemorrhage during operation, shorter hospitalization, and faster postoperative improvement.<sup>(4-6)</sup> Laparoscopic adrenalectomy may be conducted either transperitoneally or retroperitoneally.<sup>(4, 5, 7, 8)</sup> In this study, transperitoneal approach was the preferable method, which is the first report of laparoscopic adrenalectomy in Iran and to our

*Accepted for publication in August 2003*

*\*Corresponding author: Department of Kidney Transplantation, Shaheed Labbafinejad Medical Center, Boustan 9, Pasdaran, Tehran, Iran.  
email: simforoosh@iurc.org.ir*

knowledge the first one in a renal transplanted patient worldwide.

### Materials and Methods

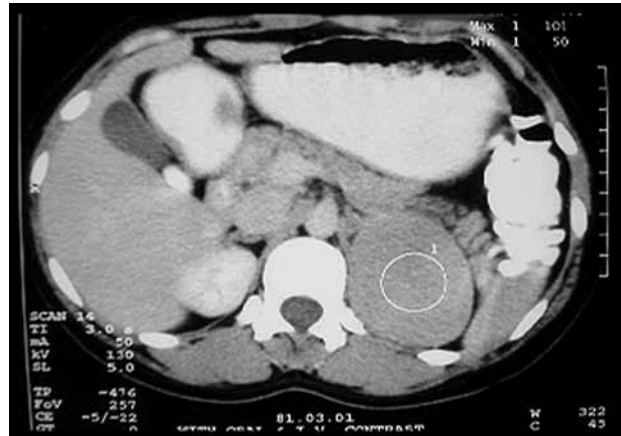From March 1997 to July 2001, 11 patients underwent laparoscopic adrenalectomy through transperitoneal method, five of whom were males and 6 were females. Their mean age was 35.5 (range 28 to 52) years. Table 1 indicates clinical and pathological details.

Ultrasonography and abdominal CT scan was preoperatively performed for all patients (fig. 1). MRI was conducted if CT scan was unclear. MIBG scan would be performed if pheochromocytoma was suspected and if MRI or CT scan were not helpful. Routine biochemical tests such as serum potassium and sodium levels, fasting blood sugar, and endocrine analyses such as serum ACTH, cortisol, mineralocorticoids, and 17-hydroxyprogesterone, and 24-hour urinary VMA were conducted too. Details of the procedure, its complications, and the probability of conversion to open surgery were explained for all of the patients. Bowel preparation was performed 24 hours before the procedure. NG tube and urethral catheter were inserted under general anesthesia. Then patients were secured in flank position with an angle of approximately 60 degrees. The bed was flexed 30 degrees and was reversed to Trendelenburg 10 degrees to retract intestine from the field of surgery. After the preparation of patient Veress needle was used through an umbilical incision and pneumoperitoneum was induced using CO<sub>2</sub>. Trocars were placed when the pressure reached 19 to 20 mmHg and then it was reduced to 14 to 15 mmHg.

Three 12, 10, and 5 mm trocars were applied in left adrenalectomy (for 6 patients). A 12 mm tro-

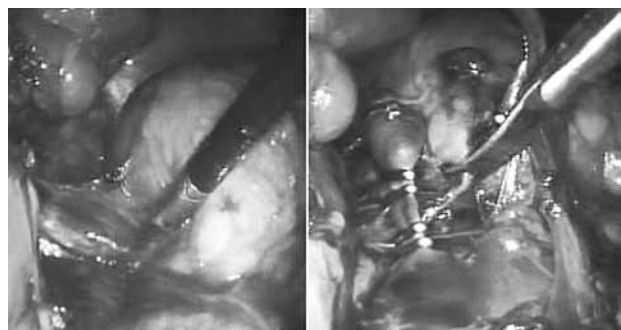
**TABLE 1.** Patients' clinical and pathological characteristics

| No. | Age | Gender | Adrenal Pathology             | Side of Operation |
|-----|-----|--------|-------------------------------|-------------------|
| 1   | 43  | Male   | Conn's syndrome               | Right             |
| 2   | 40  | Female | Conn's syndrome               | Left              |
| 3   | 52  | Male   | Pheocromocytoma               | Right             |
| 4   | 32  | Male   | Pheocromocytoma               | Right             |
| 5   | 35  | Male   | Pheocromocytoma               | Left              |
| 6   | 34  | Female | Pheocromocytoma               | Left              |
| 7   | 39  | Female | Adrenal Medullary Hyperplasia | Left              |
| 8   | 28  | Male   | Pheocromocytoma               | Left              |
| 9   | 29  | Female | Pheocromocytoma               | Left              |
| 10  | 31  | Female | Conn's syndrome               | Right             |
| 11  | 28  | Female | Myelolipoma                   | Right             |



**FIG. 1.** A 35-year-old woman with dysuria. A 7 cm tumor in left adrenal gland was revealed.

car was applied through umbilical incision and used for telescope. A 10 mm trocar was applied on breast line parallel to umbilicus and a 5 mm trocar was applied on midline between xiphoid and umbilicus. Then peritoneum was opened from the colonic spleen curve to sigmoid on Toltd line and colon was pushed inside. Then Gerota fascia was opened on renal vein, so that adrenal gland and vein were seen. Adrenal vein was cut after clipping bilaterally. Then fat tissue and the rest of the vessels were cut by Mets or electrocautery after clipping bilaterally, so that adrenal gland was totally freed. Three to four (12, 10, 5, and 5 mm) trocars were used in right adrenalectomy (for 5 patients). Similar trocars were applied in left. The second 5 mm trocar was inserted on the breast line at the rib margin to retract the liver if needed. Adrenal gland was seen at the right side behind peritoneum after retracting the liver upward. Hepatocolic and peritoneal ligaments were cut; thus, anterior surface of adrenal gland was revealed. After freeing the gland at inferior, lateral, posterior, and finally medial surfaces and cutting adrenal vein, following bilateral clipping, adrenal gland was removed through an umbilical incision made for 12 mm trocar, after enlarging it (depending on the size of gland) (fig. 2). As a drain, an 18 F Nelaton



**FIG. 2.** laparoscopic surgical operation and the tumor

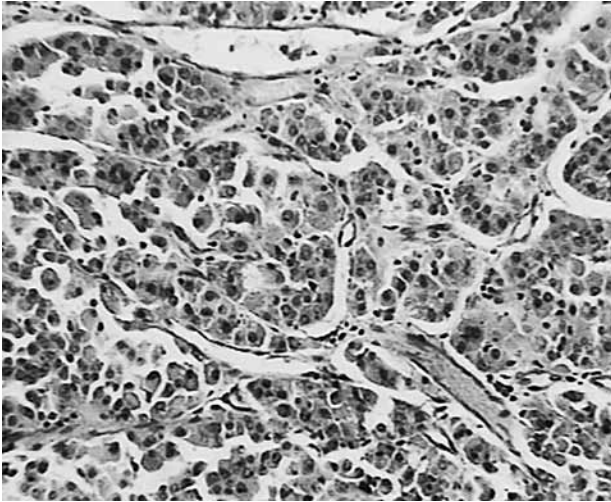


FIG. 3. Pathology: adrenaladenoma

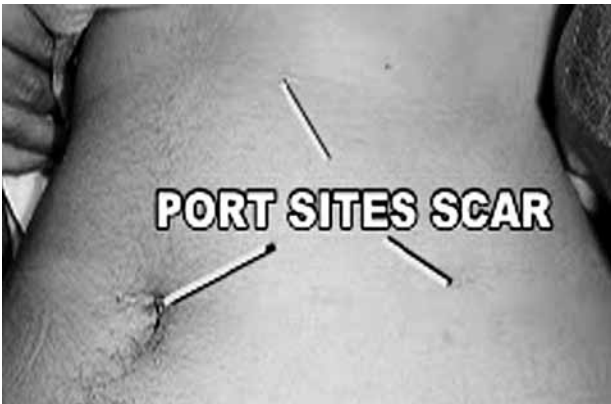

FIG. 4. Unrecognizable port site scars

catheter was applied through 10 mm trocar for two or three days for all the patients. They were followed up with paraclinical tests and physical examination for three months (fig. 3,4). Student's t test was used for comparison of the size of mass and time of the procedure.

### Results

The mean time of the procedure (including anesthesia and surgery) was  $205 \pm 64.95$  (range 130 to 310) minutes. Mean time for left side was  $227.5 \pm 53.1$  (range 145 to 305) minutes. There was no significant difference in the time of procedure between left and right sides ( $p=0.5$ ). Mean hospitalization was  $5.54 \pm 3.4$  (range 3 to 15) days.

The mean size of mass was  $5.45 \pm 1.7$  (range 2 to 8) cm. No significant difference was seen between the size of left sided masses and right sided ones ( $p=0.6$ ).

A 28-year female with a history of a 15-year renal transplantation was among the patients. She underwent laparoscopic adrenalectomy because of an adrenal mass, pathologic report of which was myelolipoma.

Blood transfusion was performed in 2 cases. Normal diet was started for 9 patients at the first postoperative day.

Open surgery due to severe adhesion was conducted for one patient (9%), who underwent laparoscopic adrenalectomy because of pheochromocytoma. Hypertensive crisis occurred during the procedure in one pheochromocytoma case, which was properly managed without any problem by the anesthesiologist. Postoperative complications were reported in only one patient with left adrenalectomy. This patient underwent open surgery due to postoperative hemorrhage. No hernia or infection was seen at the site of trocars and no mortality was reported. Blood pressure and hormonal tests were normal with no medical treatment during eight-month follow-up period.

### Discussion

Surgical intervention is regarded as the main approach in several adrenal disorders. Familiarity with adrenal gland anatomy and its pathophysiology is important for a successful procedure. Open surgical incisions for adrenal mass removal consist of thoracoabdominal, flank, anterior, and posterior (lumbar). Selecting the appropriate method depends on adrenal pathology, patient's physical structure, history of surgical operation, and surgeon's experience.<sup>(9)</sup>

Laparoscopic adrenalectomy is an effective and safe method to treat various endocrine and neoplastic adrenal diseases,<sup>(4,6,10,12)</sup> as it was shown in this study. Several studies reported that the morbidity rate in laparoscopic adrenalectomy is less than that in open surgery.<sup>(4,5,7,13-15)</sup> Previously, laparoscopic surgery needed a longer time than open surgery; however, the progress of technology and more laparoscopic experience have led to similar operative times.<sup>(14)</sup> Patients in laparoscopic surgeries would be hospitalized shorter and would return to their normal activities sooner. Younger patients could return to their sport activities sooner with no limitation. Regarding cosmetic point of view, short incisions at trocar sites instead of long incisions would be more considerable particularly for females.<sup>(14)</sup> Magnification by laparoscope would lead to easier detection of small vessels around adrenal mass which causes a distinguishable decrease of hemorrhage comparing to open adrenalectomy.<sup>(16)</sup> It also brings about a more accurate view of surgical anatomy of adrenal gland and helps differential diagnosis between adenoma and normal tissue of gland. Elective

removal of adrenal lesion without total removal of the gland, which is problematic in open surgery, is more practical in laparoscopic surgery. Guazzo et al reported successful removal of 2 adrenal cysts without adrenal removal after which adrenal function was normal.<sup>(14)</sup> Most authors agree on the effectiveness of laparoscopic therapy for Conn's and Cushing's syndromes.<sup>(4)</sup> Because of hypertensive crisis during surgery, pheochromocytoma surgery differs from other adrenal tumoral surgeries.<sup>(4,5,17)</sup> It was believed that laparoscopic methods are contraindicated in pheochromocytoma, for the produced pneumoperitoneum with CO<sub>2</sub> and the increase of abdominal pressure would lead to hemodynamic changes and the release of catecholamines as well.<sup>(18)</sup> Furthermore, CO<sub>2</sub> could cause hypercapnia and respiratory acidosis that would lead to hypertension during laparoscopy.<sup>(17,19)</sup> Sprung et al have recently shown that laparoscopic hemodynamic changes are comparable with those of open surgery methods. The number of hypertension episodes and the highest level of hypertension during surgery were equal in both methods, while hypotension severity was lower in laparoscopic methods than open surgery.<sup>(20)</sup> Consequently, pheochromocytoma could be treated by laparoscopic surgery, although large lesions could increase the chance of hemorrhage, hypertension and postoperative complications due to increased number of vessels.<sup>(21)</sup> In this study hypertension occurred only in one patient (out of 6) with pheochromocytoma, which was controlled with no complication. Since Ganger has indicated that lesions larger than 13 cm could be treated by laparoscopic adrenalectomy, the size of adrenal mass was no more considered as a limiting factor in laparoscopic surgery.<sup>(4,12)</sup> Thus, larger masses which could mostly be malignant, would be removed by laparoscopic surgery, though, enlarging the incision of umbilicus would be essential.<sup>(14)</sup> Dissection would be more difficult and the surgery would last in a way that could be beyond patient's tolerance.<sup>(21)</sup> Moreover, large masses have many abnormal vessels which could increase hemorrhage.<sup>(22)</sup> Bilateral adrenalectomy for Cushing's syndrome after unsuccessful treatment of hypophysis adenoma (surgery or radiotherapy) or for secondary Cushing's syndrome could lead to improper discharge of ACTH.<sup>(23,24)</sup> In our study, the decrease of wound infection risk, better postoperative respiratory capacity and short-

er hospitalization would be main advantages of laparoscopy.<sup>(21)</sup> Laparoscopy is used in the treatment of nonfunctional adrenal masses too, especially when their malignant nature is proved.<sup>(25)</sup> This is a common case as 20-22% of laparoscopic adrenalectomies are because of incidentaloma removal.<sup>(4,6)</sup> Porpiglia et al reported that the incidence of incidentaloma was 30% of the whole laparoscopic adrenalectomies.<sup>(21)</sup> Several factors such as a mass larger than 6 cm (in CT Scan or sonography), non-homogenized mass in CT scan and an increase of DHEA or estradiol are used to distinguish malignant adrenal masses from benign.<sup>(26)</sup>

In spite of these factors, adrenalectomy may be performed for an incidentaloma where cortical carcinoma may be detected by the analysis of pathologic sample. Porpiglia et al reported such a carcinoma after laparoscopic removal of the mass. No sign of recurrence was reported after 40 months follow-up.<sup>(21)</sup> It is commonly believed that this treatment would be sufficient for proved malignant adrenal masses provided that the neoplasm is limited to the gland and a perfect and accurate laparoscopy is performed.<sup>(4,5)</sup>

Laparoscopic transperitoneal removal of adrenal glands includes anterior and lateral transperitoneal methods. In anterior transperitoneal method, adrenal anterior margin is usually freed at the end that occasionally leads to upward movement of adrenal, which makes it difficult to pull downward.<sup>(16)</sup> However, in this study anterior margin of adrenal gland was easily freed at the beginning after the retraction of the liver or spleen toward midline through lateral transperitoneal approach. Thus, it seems that lateral transperitoneal approach would be better than anterior transperitoneal, particularly for large tumors.

### Conclusion

This study indicated that transperitoneal laparoscopic adrenalectomy is an effective and safe approach, which should be performed by a skilled laparoscopic surgeon to minimize potential intraoperative and postoperative complications such as infection and to avoid open incision.

Clinical outcomes of laparoscopic surgery in such circumstances would be much better than open surgery and its morbidity would be much lesser.

## References

1. Ganger M, Lacroix A, Bolte E. Laparoscopic adrenalectomy in Cushing's syndrome and pheochromocytoma. *N Engl J Med* 1992; 327: 1003.
2. Ganger M, Lacroix A, Printz RA, et al. Early experience with laparoscopic approach for adrenalectomy. *Surgery* 1993; 114: 1120.
3. Ganger M, Lacroix A, Bolte E. Laparoscopic adrenalectomy. *Surg Endosc* 1993; 7: 122.
4. Ganger M, Pomp A, Heniford BT, et al. Laparoscopic adrenalectomy: lessons learned from 100 consecutive procedures. *Ann Surg* 1997; 226: 238.
5. Janetschek G, Altarac S, Finkenstedt G, et al. Technique and results of laparoscopic adrenalectomy. *Eur Urol* 1996; 30: 475.
6. Terachi T, Matsuda T, Terai A, et al. Transperitoneal laparoscopic adrenalectomy: Experience in 100 patients. *J Endourol* 1997; 11: 361.
7. Gasman D, Droupy S, Koutani A, et al. Laparoscopic adrenalectomy: the retroperitoneal approach. *J Urol* 1998; 159: 1816.
8. Walz MK, Peitgen K, Hoermann R, et al. Posterior retroperitoneoscopy as a new minimally invasive approach for adrenalectomy: results of 30 adrenalectomies in 27 patients. *World J Surg* 1996; 20: 769.
9. Guz BV, Straffon RA, Novick AC. Operative approaches to the adrenal gland. *Urol Clin N Amer* 1989; 16: 527.
10. Guazzoni G, Montorsi F, Bergamaschi F, et al. Effectiveness and safety of laparoscopic adrenalectomy. *J Urol* 1994; 152: 1375.
11. Thompson GB, Grant CS, Van Heerden JA, et al. laparoscopic versus open posterior adrenalectomy: A case control study of 100 patients. *Surgery* 1997; 122: 1132.
12. Vargas HI, Kavoussi LR, Bartlett DL, et al. laparoscopic adrenalectomy: A new standard of care. *Urology* 1997; 49: 673.
13. Bonjer HJ, Van der Harst E, Steyerberg EW, et al. Retroperitoneal adrenalectomy: open or endoscopic? *World J Surg* 1998; 22: 1246.
14. Guazzoin G, Montorsi F, Bocciardi A, et al. Transperitoneal laparoscopic versus open adrenalectomy for benign hyperfunctioning adrenal tumors: a comparative Study. *J Urol* 1995; 153: 1597.
15. Winfield HN, Hamilton BD, Bravo EL, et al. Laparoscopic adrenalectomy: the preferred choice? A comparison to open adrenalectomy. *J Urol* 1998; 160: 325.
16. Terachi T, Matsuda T, Terai A, et al. Transperitoneal laparoscopic adrenalectomy: experience in 100 patients. *J Endourol* 1997; 11: 361.
17. Mobius E, Nies C, Rothmund M. Surgical treatment of pheochromocytomas: laparoscopic or conventional? *Surg Endosc* 1999; 13: 35.
18. Joris J, hamoir E, Hartstein GM, et al. Hemodynamic changes and catecholamine release during laparoscopic adrenalectomy for pheochromocytoma. *Anesth Analg* 1999; 88: 16.
19. Fernandez-Cruz L, Taura P, Saenz A, et al. Laparoscopic approach to pheochromocytoma: hemodynamic changes and catecholamine secretion *World J Surg* 1996; 20: 762.
20. Sprung J, O Hara JF Jr, Gill IS, et al. Anesthetic aspects of laparoscopic and open adrenalectomy for pheochromocytoma. *Urology* 2000; 55: 339.
21. Porpiglia F, Garrone C, Giraudo G, et al. Transperitoneal laparoscopic adrenalectomy: Experience in 72 procedures. *J Endourol* 2001; 15: 275.
22. Ganger M. Laparoscopic adrenalectomy. *Surg Clin North Am* 1996; 76: 523.
23. Ferrer FA, MacGillivray DC, Malchoff CD, et al. Bilateral laparoscopic adrenalectomy for adrenocorticotropic dependent Cushing's syndrome. *J Urol* 1997; 157: 16.
24. Lanzi R, Montorsi F, Losa M, et al. Laparoscopic bilateral adrenalectomy for persistent Cushing's disease after transsphenoidal surgery. *Surgery* 1998; 123: 144.
25. Mugiya S, Suzuki K, Masada H, et al. laparoscopic adrenalectomy for nonfunctioning adrenal tumor. *J Endourol* 1996; 10: 539.
26. Wells SA, Merke DP, Cutler GB, et al. Therapeutic controversy: The role of laparoscopic surgery in adrenal disease. *J Clin Endocrinol Metab* 1998; 83: 3041.