

Pattern of Compensatory Hypertrophy in Contralateral Testis After Unilateral Orchiectomy in Immature Rabbits

Kamyar Tavakkoli Tabassi,¹ Sakineh Amoueian,² Elena Saremi³

Introduction: Our aim was to evaluate effects of hemicastration in immature rabbits on the histology of the contralateral testis after puberty.

Materials and Methods: Eighteen immature male rabbits were randomly divided into two groups. The first group underwent right or left hemicastration and the second, sham operation. After their puberty, the rabbits underwent the second operation. In the former group the contralateral testis and in the latter, the right or left testis was removed and sent for pathologic examination. The two groups were compared in terms of Leydig cell count, testis volume, and seminiferous tubule count and diameter.

Results: The mature rabbits' mean weight at the orchiectomy time, seminiferous tubule count, and seminiferous tubules diameter did not show significant differences between two groups. However, testis volumes and Leydig cell count were significantly higher in the first group with hemicastration prior to puberty. The mean testis volume was 3.24 ± 2.06 mL in the first group and 1.4689 ± 0.85701 mL in the second group ($P = .03$), and the mean Leydig cell count in every 5 microscopic high-power fields was 86.22 ± 54.96 and 42.00 ± 18.09 , respectively ($P = .04$).

Conclusion: Our research demonstrated that prepubertal hemicastration in rabbits led to the compensatory hypertrophy in the contralateral testis after puberty and an increase in the number of the Leydig cells.

Keywords: orchiectomy, rabbits, testis, Leydig cells, seminiferous tubules

Urol J. 2009;6:199-203.
www.uj.unrc.ir

INTRODUCTION

The testicular volume consists mainly of seminiferous tubules, where spermatogenesis completes, and the Leydig cells (5% to 12%), which have the role of originating the testosterone.^(1,2) Different circumstances such as trauma, testicular torsion, tumors, undescended testis, and congenital anorchia may result in testicular vanishing at different years of age. The effects of a vanished testis on the morphologic and functional factors of the other one,

in proportionate to its vanishing age, has been the point of concern. However, respecting the ethics of human rights, studies on this issue has been done on animals. Functional compensation of the remnant testis after hemicastration has been investigated in rats, rabbits, sheep, pigs, and cattle.⁽³⁻¹⁰⁾ In rats, sheep, pigs, and cattle, it has been reported that hemicastration in prepubertal period causes hypertrophy of the contralateral testis.^(3,8-10) Hemicastration in mature rats does not cause

¹Department of Urology, Imam-Reza Hospital, Mashhad University of Medical Sciences, Mashhad, Iran

²Department of Pathology, Imam-Reza Hospital, Mashhad University of Medical Sciences, Mashhad, Iran

³Department of Surgery, Imam-Reza Hospital, Mashhad University of Medical Sciences, Mashhad, Iran

Corresponding Author:
Kamyar Tavakkoli Tabassi, MD
Department of Urology, Imam-Reza Hospital, Mashhad, Iran
Tel: +98 915 311 6149
E-mail: kamiartt@yahoo.com

Received March 2009
Accepted July 2009

hypertrophy of the remnant testis,⁽³⁾ but it does in sheep.⁽⁷⁾

According to Mombeini and colleagues, hemicastration in mature rabbits does not cause hypertrophy of the contralateral testis.⁽¹¹⁾ In two other studies on prepubertal rabbits, there are different results about hemicastration effects on the contralateral testis, one eventuates in hypertrophy of the contralateral testis,⁽¹²⁾ whereas the other one does not.⁽⁵⁾ Based on the aforementioned facts, we decided to evaluate the hemicastration effects on the histology of the contralateral testis in immature rabbits.

MATERIAL AND METHODS

Animals and Castration

This study was supplied with 18 immature male Albino rabbits (20 to 25 days old) by Razi Institution. The study protocol was approved by the ethical committee of Mashhad University of Medical Sciences. The immaturity of the rabbits was confirmed by one veteran based on the examination of the undescended testes. The rabbits were randomly divided into 2 groups of case and control. In the case group, right or left hemicastration was performed randomly and the specimens were sent for pathologic examination. Immature testicular pattern was confirmed on the examinations. General anesthesia was done with xylazine, 5 mg/kg, and ketamine, 44 mg/kg, and complemented with local anesthesia using lidocaine. Unilateral castration was performed through a scrotal incision with an abdominal extension on the covert testis. In the control group, sham operation was performed, consisting of a scrotal incision and its simple repair.

All of the rabbits were hospitalized after the operations in the same environmental situation. The rabbits' room temperature was kept between 13°C and 19°C. They were fed by their routine nourishments in the animal house center. Then, the rabbits underwent the second operation after their onset of puberty, 4 months after the first operation. The remnant testis in the case group and the right or the left testis in the control group was hemicastrated. The specimens were embedded in paraffin, fixed immediately by immersion in

10% Boan, and sent for pathology examination. At the end of the study, all of the animals were scarified by administration of high doses of anesthetic drugs.

Pathology Examination

First, testis length and width were measured using a laboratory clippers and testis volume was calculated using the formula for a prolate sphere ($4.19 \times a \times b^2$, where a is the longest radius and b , the shortest radius). For enumeration of the seminiferous tubules on the tissue sections, 2 serial sections were cut with microtome from each of the paraffin blocks per testis (thickness, 3 μ m to 4 μ m). They were stained with periodic acid-Schiff reagent and counterstained with Harris hematoxylin. The fields for microscopic examination were selected randomly. The Leydig cells and the seminiferous tubules were counted in 20 and 10 random high-power field of microscope, respectively, and then, the average values were determined. For measuring the diameters of the tubules, a micrometer was used located on the objective lens of microscope.

Statistical Analyses

Statistical analyses were performed using the SPSS software (Statistical Package for the Social Sciences, version 16.0, SPSS Inc, Chicago, Illinois, USA). The data were expressed as mean \pm standard deviation. According to the Kolmogorov-Smirnov test our variables had normal distribution. The two groups were compared in terms of Leydig cell count, mean diameter, seminiferous tubules count, testis volume, and rabbit's weight, using independent sample t test for continuous variables and the chi-square test for categorical variables. A P value of less than .05 was considered significant.

RESULTS

The pathological assessments of the immature rabbits' testes showed no spermatogenesis in all the 9 specimens and thereby immature patterns of the testes obtained from the case group (Figure 1). Four months after the first operation, the body weight of the mature rabbits at the orchidectomy time was 1731.22 ± 77.79 mg and 1705.56 ± 124.81

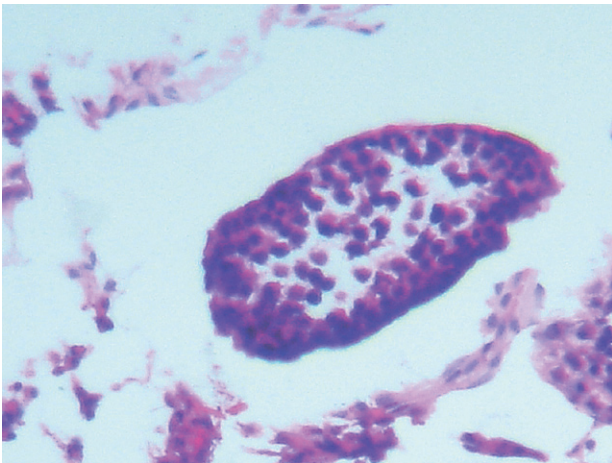


Figure 1. Testis of an immature rabbit (Harris hematoxylin, × 100).

mg in the case and the control groups, respectively ($P = .61$).

Changes in the testes parameters after hemicastration in comparison with those in the control group were as follows: the mean testis volume was 3.24 ± 2.06 mL in the case group and 1.4689 ± 0.85701 mL in the control group ($P = .03$). The mean Leydig cell count in every 5 microscopic high-power fields was 86.22 ± 54.96 and 42.00 ± 18.09 , respectively in the case and the control group ($P = .04$; Figures 2 and 3). The mean seminiferous tubules count in the case group was 22.56 ± 6.37 and 28.11 ± 8.02 in the control group ($P = .12$; Figures 2 and 3). The mean seminiferous tubules diameter in the case group was 160.00 ± 46.90 μm and 150.00 ± 7.817 μm in the control group ($P = .58$).

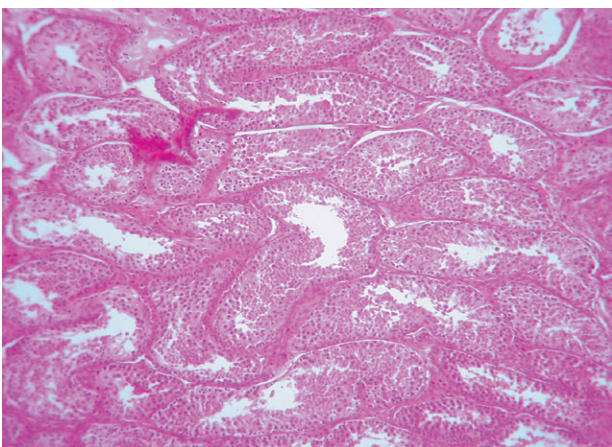


Figure 2. Testis of a rabbit 4 months after hemicastration of the contralateral testis (Harris hematoxylin, × 40).

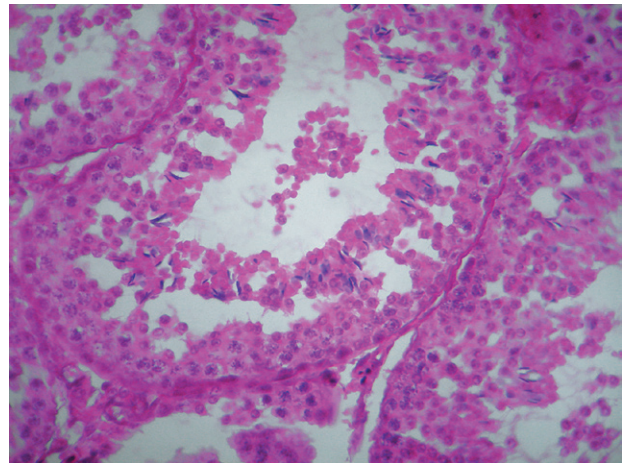


Figure 3. Testis of a mature rabbit in the control group (Harris hematoxylin, × 100).

DISCUSSION

The effects of unilateral castration on the histological factors of the contralateral testis and also the hormonal changes in men have drawn researchers' attention. They have tried to find the answer by considering various ages of hemicastration in different animal species. After puberty in the majority of the studied species, hemicastration resulted in compensatory hypertrophy of the contralateral testis. This fact was fully demonstrated in those studies performed on dogs and rabbits.^(11,12) In the study by Mombeini and colleagues, 10 mature rabbits were unilaterally castrated, and after puberty, the contralateral testis was castrated. Testes weight and histological parameters were compared to the formerly castrated ones. Owing to the fact that there were not any significant differences in Leydig cell count and size of the seminiferous tubules, it was concluded that a testis did not have evidently the potential ability of compensatory hypertrophy after puberty.⁽¹¹⁾

Hemicastration effects before maturity presented different consequents. Various investigations on rats, lambs, pigs, cattle, and dogs have demonstrated that unilateral castration before puberty leads up to the compensatory hypertrophy in the contralateral testis after puberty.^(3,10,13-22) However, it has not been always the same in those studies performed on rabbits. Sanefuji reported a double increase in seminiferous tubules count and testis

weight of the contralateral testis 4 weeks after hemicastration in immature rabbits.⁽¹²⁾ In contrast, Berger and coworkers' study showed no hypertrophy in the contralateral testis of 1- to 50-day-old rabbits after hemicastration; however, the authors did not give the contralateral testes enough time, ie, 10 days, for any probable hypertrophy.⁽⁶⁾ Similarly in another investigation, 30 male rabbits were divided into 5 separate groups, whereby no operation was performed on one of the groups, and the rest were hemicastrated at the ages of 35, 49, 77, and 105 days. In all the rabbits the contralateral testis was castrated at the age of 8 months to be evaluated.⁽⁵⁾ This investigation, as well, did not show any significant differences between the testis parameters; eg, mean testis weight of 3.53 in hemicastrated rabbits at the age of 35 days compared to 2.52 in those in the control group. Hence, the compensated hypertrophy was doubtful. Sham operation, however, was not done on the first group and each of groups consisted of only 6 rabbits. Therefore, we decided to give the testes more time for any possible changes. Thus, the results were significant in our study, similar to other animal-based studies, demonstrating compensatory hypertrophy of the contralateral testis in hemicastrated immature rabbits.

During prepubertal development in most animal species, normal testicular growth is associated with dramatic proliferation of the Leydig cells in the interstitium and an increased number of the Sertoli and germ cells within the seminiferous epithelium.^(1,23-25) In most species, compensatory hypertrophy has been associated with increased diameter and length of the seminiferous tubes and increased number of the germ cells and Sertoli cells.^(9, 26-30) Thus, the proliferation response to prepubertal unilateral castration is often used as a model for studying those factors influencing testicular development. Although neither the number nor the diameter of the seminiferous tubes had a significant change in our study, the enlargement of the seminiferous length is possible due to an increase of the remaining testis volume.

Changes in the Leydig cells are less discussed in compensatory hypertrophied testis of hemicastrated rabbits. In a study performed on

boars, increased number of Leydig cell and total Leydig cell mass in compensatory hypertrophied testes was demonstrated; the younger the age at hemicastration, the more obvious increase in the number of Leydig cells.⁽³¹⁾ In our study, increase in Leydig cell count in every 5 light microscopic high-power field of testis samples, and therefore, in the total testis mass was an integral part of hypertrophied rabbit's testis. However, we could not measure the hormonal levels and also the Insulin-like growth factor, which would help us better interpret our findings.

CONCLUSION

Our research demonstrated that prepubertal hemicastration in rabbits led to the compensatory hypertrophy in the contralateral testis after puberty. This process includes at least the increase in Leydig cell count and testis volume.

CONFLICT OF INTEREST

None declared.

REFERENCES

1. Christensen AK. Leydig cells. In: Hamilton DW, Greep RO, editors. Handbook of physiology. Baltimore: American Physiological Society, William & Wilkins; 1975. p. 57-94.
2. Kaler LW, Neaves WB. Attrition of the human Leydig cell population with advancing age. *Anat Rec.* 1978;192:513-8.
3. Cunningham GR, Tindall DJ, Huckins C, Means AR. Mechanisms for the testicular hypertrophy which follows hemicastration. *Endocrinology.* 1978;102:16-23.
4. Furuya T. Onset of compensatory hypertrophy of interstitial tissue and Leydig cells in rats hemicastrated around the time of puberty. *Biol Reprod.* 1990;42:491-8.
5. Thompson TL, Berndtson WE. Testicular weight, Sertoli cell number, daily sperm production, and sperm output of sexually mature rabbits after neonatal or prepubertal hemicastration. *Biol Reprod.* 1993;48:952-7.
6. Berger M, Jean-Faucher C, De Turckheim M, Veyssiere G, Jean C. The effect of unilateral castration on plasma and testicular testosterone in rabbits from birth to 60 days. *Arch Int Physiol Biochim.* 1978;86:799-808.
7. Hochereau-de Reviere MT, Loir M, Pelletier J. Seasonal variations in the response of the testis and LH levels to hemicastration of adult rams. *J Reprod Fertil.* 1976;46:203-9.

8. Waites GM, Wenstrom JC, Crabo BG, Hamilton DW. Rapid compensatory hypertrophy of the lamb testis after neonatal hemiorchidectomy: endocrine and light microscopical morphometric analyses. *Endocrinology*. 1983;112:2159-67.
9. Kittok RJ, Kinder JE, Johnson RK. Effect of castration on plasma luteinizing hormone concentrations in prepubertal boars. *J Anim Sci*. 1984;58:1271-7.
10. Schanbacher BD, Fletcher PW, Reichert LE, Jr. Testicular compensatory hypertrophy in the hemicastrated calf: effects of exogenous estradiol. *Biol Reprod*. 1987;36:1142-8.
11. Mombeini H, Mosapour S, Aghaee A. [The evaluation of hormonal and histologic changes in contralateral testis after unilateral orchidectomy in white rabbits]. *Iran J Urol*. 2001;29:29-33. Persian.
12. Sanefuji T. [Tissue culture studies on compensatory testicular hypertrophy of the young rabbit after hemicastration]. *Hinyokika Kiyo*. 1988;34:585-91. Japanese.
13. Orth JM, Higginbotham CA, Salisbury RL. Hemicastration causes and testosterone prevents enhanced uptake of [3H] thymidine by Sertoli cells in testes of immature rats. *Biol Reprod*. 1984;30:263-70.
14. Brown JL, Dahl KD, Chakraborty PK. Effects of follicular fluid administration on serum bioactive and immunoactive FSH concentrations and compensatory testicular hypertrophy in hemicastrated prepubertal rats. *J Endocrinol*. 1991;130:207-12.
15. Brown JL, Chakraborty PK. Comparison of compensatory pituitary and testicular responses to hemicastration between prepubertal and mature rats. *J Androl*. 1991;12:119-25.
16. Brown JL, Schoenemann HM, Chakraborty PK. Follicular fluid administration delayed, but did not prevent, the hemicastration-induced increase in follicle-stimulating hormone secretion and compensatory testicular hypertrophy in ram lambs. *Biol Reprod*. 1994;50:44-8.
17. Walton JS, Evins JD, Hillard MA, Waites GM. Follicle-stimulating hormone release in hemicastrated prepubertal rams and its relationship to testicular development. *J Endocrinol*. 1980;84:141-52.
18. Walton JS, Evins JD, Waites GM. Feedback control of follicle-stimulating hormone in pre-and postpubertal rams as revealed by hemicastration. *J Endocrinol*. 1978;77:75-84.
19. Hochereau-de Reviers MT, Blanc MR, Courot M, Gamier DH, Pelletier J, Poirier JC. Hormonal profiles and testicular parameters in the lamb. In: Steinberger A, Steinberger E, editors. *Testicular development, structure, and function*. New York: Raven Press; 1980. p. 237-47.
20. Brown JL, Stuart LD, Chakraborty PK. Endocrine profiles, testicular gonadotropin receptors and sperm production in hemi-castrated ram lambs. *J Anim Sci*. 1987;65:1563-70.
21. Miranda MA, Hoagland TA, Woody CO, Jr., Riesen JW. The influence of unilateral castration on testicular morphology and function in adult rams. *Biol Reprod*. 1989;41:798-806.
22. Tsutsui T, Kurita A, Kirihara N, Hori T, Kawakami E. Testicular compensatory hypertrophy related to hemicastration in prepubertal dogs. *J Vet Med Sci*. 2004;66:1021-5.
23. Sharpe RM, Walker M, Millar MR, et al. Effect of neonatal gonadotropin-releasing hormone antagonist administration on sertoli cell number and testicular development in the marmoset: comparison with the rat. *Biol Reprod*. 2000;62:1685-93.
24. McCoard SA, Lunstra DD, Wise TH, Ford JJ. Specific staining of Sertoli cell nuclei and evaluation of Sertoli cell number and proliferative activity in Meishan and White Composite boars during the neonatal period. *Biol Reprod*. 2001;64:689-95.
25. Johnson L. Increased daily sperm production in the breeding season of stallions is explained by an elevated population of spermatogonia. *Biol Reprod*. 1985;32:1181-90.
26. Voglmayr JK, Mattner PE. Compensatory hypertrophy in the remaining tests following unilateral orchidectomy in the adult ram. *J Reprod Fertil*. 1968;17:179-81.
27. Boockfor FR, Barnes MA, Kazmer GW, Halman RD, Bierley ST, Dickey JF. Effects of unilateral castration and unilateral cryptorchidism of the Holstein bull on plasma gonadotropins, testosterone and testis anatomy. *J Anim Sci*. 1983;56:1376-85.
28. Kosco MS, Loseth KJ, Crabo BG. Development of the seminiferous tubules after neonatal hemicastration in the boar. *J Reprod Fertil*. 1989;87:1-11.
29. Orth JM. The role of follicle-stimulating hormone in controlling Sertoli cell proliferation in testes of fetal rats. *Endocrinology*. 1984;115:1248-55.
30. Hochereau-de Reviers MT, Land RB, Perreau C, Thompson R. Effect of season of birth and of hemicastration on the histology of the testis of 6-month-old lambs. *J Reprod Fertil*. 1984;70:157-63.
31. Lunstra DD, Wise TH, Ford JJ. Sertoli cells in the boar testis: changes during development and compensatory hypertrophy after hemicastration at different ages. *Biol Reprod*. 2003;68:140-50.