

Concurrent Repair of Inguinal Hernias with Mesh Application During Transperitoneal Robotic-assisted Radical Prostatectomy: Is it Safe?

Ali Fuat Atmaca^{1#}, Nurullah Hamidi^{2*#}, Abdullah Erdem Canda³, Murat Keske², Arslan Ardıcoglu¹

Purpose: To assessment the safety of concurrent repair of inguinal hernia (IH) with mesh application during transperitoneal robotic-assisted radical prostatectomy (RARP).

Materials and Methods: Data of 20 patients (totally 25 procedures) who performed concurrent IH repair with mesh application during RARP were retrospectively enrolled in this study. Preoperative patient characteristics, intra and postoperative parameters (pathological Gleason grade, prostate volume at surgical specimen, operative time, herniorrhaphy time, estimated blood loss, complications, time of hospitalization, catheterization, and drainage) were evaluated. Standard PSA control and postoperative complications of mesh application such as hernia recurrence, mesh infection, seroma formation and groin pain were evaluated at every follow-up visits (every three in the first year, then every 6 months in years 2 to 5 and annually thereafter).

Result: The mean age was 66 ± 8 years in our population. Fifteen (60 %) patients had a unilateral hernia and 5 (40 %) patients had bilateral hernias. The mean operative time was 139 ± 21 minutes and estimated mean blood loss was 108 ± 76 mL. The mean duration of IH repair in patients which was 27 ± 5 (range: 17- 40) minutes. The mean time of drainage, hospitalization, and catheterization were 2.5 ± 0.8 days (range: 2-6), 4 ± 0.9 days (range: 2-7) and 8.2 ± 1.9 days (range: 7-14), respectively. We did not observe any intra-operative complication due to RARP or IH repair. Wound evisceration at camera port site developed in only a patient on postoperative day 20. Our median follow-up time was 13 months and we did not observe mesh infection or hernia recurrence during follow-up.

Conclusion: Concurrent IH repair with RARP procedure seem to be easy to perform, effective and safe procedure.

Keywords: robotic surgery; inguinal hernia; mesh application; radical prostatectomy

INTRODUCTION

Prostate cancer (PCa) and inguinal hernia (IH) are usually diagnosed at advanced age and these diseases can be detected concomitantly. Inguinal hernia is detected approximately in one-third of the patients undergoing radical prostatectomy (RP) with preoperative imaging studies or incidentally.^(1,2) The incidence rate of asymptomatic IH approached up to 33 %.⁽²⁾ On the other hand, IH is considered a manifest of RP by many authors and the incidence of IHs is higher in men undergoing RP when compared with non-operated men.⁽³⁻⁴⁾ Concurrent IH repair at the time of prostatectomy was first described by McDonald and Huggins in 1949.⁽⁵⁾ They performed concurrent IH repair during open prostatectomy through two incisions. Then, several studies reported the safety and feasibility of concurrent IH repair with laparoscopic radical prostatectomy.^(2,6) Nowadays, concurrent IH repair is increasingly being performed safely with Robotic-assisted radical prostatectomy (RARP).⁽⁷⁻¹⁰⁾

The main rationale of concurrent IH repair is that subsequent IH repair might be more difficult and there might be potential complications such as vascular or

bladder injury because of adhesions in surgical area following previous RP surgery. Moreover, concurrent IH repair at the time of RP has also advantage on surgery time. Repair at the time of minimal invasive RP adds an additional 10 to 30 minutes of operative time whereas subsequent IH repair, either laparoscopic or open, may take 45 to 111 minutes.⁽⁷⁻¹¹⁾ However, there are some concerns in terms of concurrent IH repair due to risk of mesh infection, postoperative groin pain and postoperative adhesions of intraperitoneal structures.⁽¹²⁾ Another, controversial concern is the risk of bowel adhesions when prosthetic mesh is used during IH repair. To reduce these risks, surgeons recommend reperitonealization after mesh stabilization and/or using coated mesh which is resistant to adhesion formation.^(7,12) The theoretical risk of infection arises from the possibility that the mesh may contact with urine in the presence of a vesico-urethral anastomotic leakage. Contrary, recent previous studies have showed that concomitant IH repair with mesh during RP is safe and there were no instances of mesh infection or groin pain reported.⁽⁷⁻¹⁰⁾ There are mainly two tension-free minimal invasive IH repair techniques: totally extraperitoneal (TEP) and transabdominal preperitoneal (TAPP). Otherwise, her-

¹Department of Urology, Ankara Yildirim Beyazit University Faculty of Medicine, Ankara Atatürk Training and Research Hospital, Cankaya, Ankara 06430, Turkey.

²Department of Urology, Ankara Atatürk Training and Research Hospital, Cankaya, Ankara 06430, Turkey.

³Department of Urology, Koc University School of Medicine, Maltepe, Istanbul 34010, Turkey

*Correspondence: Department of Urology, Ankara Atatürk Training and Research Hospital, Cankaya, Ankara 06430, Turkey.

Tel: +90 553 205 0307, Fax: +90 312 508 2147, e-mail: dr.nhamidi86@gmail.com.

These authors contributed equally to this work

Received September 2017 & Accepted February 2018

Table 1. Demographic and pathological data of all patients.

Parameter	25 procedures in 20 patients
Age, year; Mean \pm Std (range)	66 \pm 8 (49-79)
PSA, ng/mL; Mean \pm SD (range)	8.2 \pm 3.2 (3.9-17.2)
Prostate volume, mL; Mean \pm SD (range)	64 \pm 17 (20-140)
Pathological Gleason grade, number of patients (%)	
3+3	9 (45)
3+4	7 (35)
4+3	3 (15)
4+4	1 (5)
Hernia laterality	
Unilateral (Left/Right)	15 (9/6)
Bilateral	5
Hernia type, number of procedure (%)	
Direct	15 (60)
Indirect	10 (40)
Mesh types, number of procedures (%)	
Ventralight TM ST mesh	10 (40)
Sepramesh TM IP mesh	13 (52)
3DMax TM (Polypropylene) mesh	2 (8)
Total operative time, min; Mean \pm SD (range)	139 \pm 21 (100-195)
Estimated blood loss, mL; Mean \pm SD (range)	108 \pm 76 (10-300)
Drainage time, day; Mean \pm SD (range)	2.5 \pm 0.8 (2-6)
Hospitalization time, day; Mean \pm SD (range)	4 \pm 0.9 (2-7)
Catheterization time, day; Mean \pm SD (range)	8.2 \pm 1.9 (7-14)

Abbreviations: PSA, Prostate specific antigen

nia can be repaired with suture alone. Concurrent IH repair during RARP is novel technique and it is increasingly being performed for recent years. Our department is one of the referral robotic surgery center in our country and herein, we aimed to present our initial experiences with concurrent IH repair during RARP with TAPP technique.

MATERIALS AND METHODS

This retrospective study was approved by the institutional review board (IRB decision no: 76, Decision date: 14/04/2017). Patients were informed and written

informed consent was obtained from all patients. Study Population, inclusion and exclusion criteria: We retrospectively evaluated the data of 414 consecutive RARPs between June 2015-May 2017. We included the patients who underwent IH repair with mesh during RARP to this study. We excluded the patients who have previous IH repair surgery history, bleeding diastasis and untreated urinary tract infection.

A total of 25 concurrent herniorrhaphies were performed in 20 patients. Nine (45 %) patients had incidentally detected IHs during RARP whereas 11 (55 %) patients had IHs detected before RARP during physi-

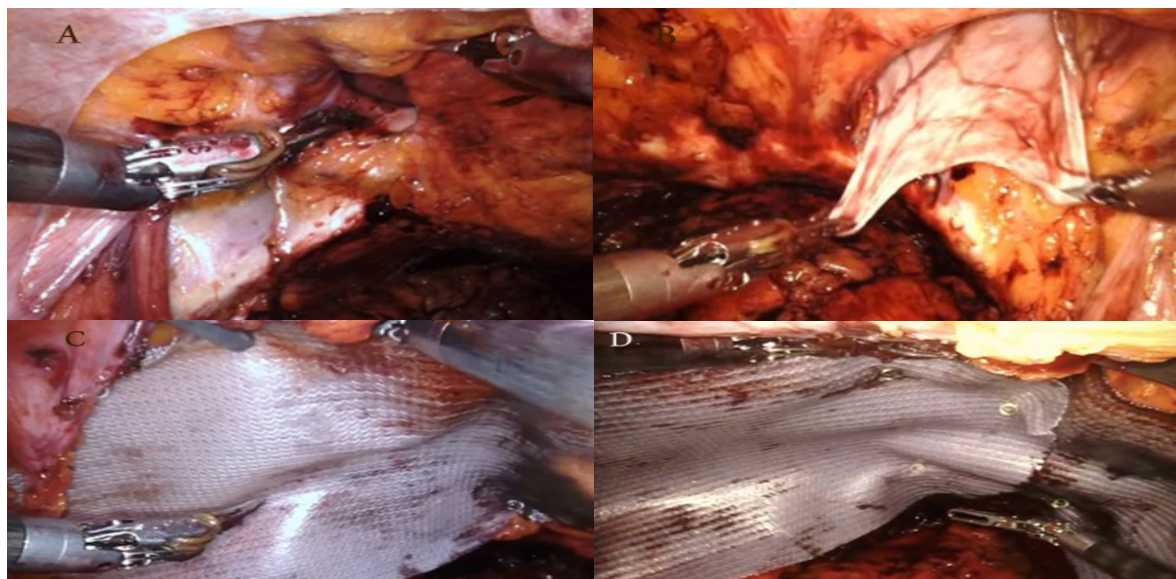


Figure 1. Bilateral direct inguinal hernia repair during robotic-assisted radical prostatectomy.

Before applying the mesh over the hernia defect, the hernia sac is dissected (A). The hernia wall is retracted and it is fixed to the pubic bone (B). A proper size of the mesh was chosen according to the defect size (C). A laparoscopic tack was used to fix the mesh material around the hernia defect (D).

Table 2. Previous articles in literature on concurrent inguinal hernia repair during robotic assisted radical prostatectomy

Author	Year	Number of patient (number of total procedure)	Herniorrhaphy technique	Mesh type	Reperitonealization	Total herniorrhaphy duration	Follow-up duration	Mesh infection rate	Mean estimated blood loss	Hernia recurrence rate	Complication
Finley et al. ⁷	2008	80 (104)	Modified stoppa technique	Marlex, Polypropylene, Ultrapro, Proceed coated, 3D-Max, Combination of both umbrella and Xat mesh, Suture alone	In initial cases (36/80)	15 min	Mean 12 months	None	-	%1.3	None
Joshi et al. ⁸	2010	4 (6)	TAPP	Polypropylene mesh, Polyester mesh, Parietex mesh	Yes	24 min	Median 33 months	None	-	None	-
Do et al. ⁹	2011	93 (109)	TEP	Primalene mesh	No	-	-	None	240 ml	None	Lymphocele (required drainage) in three patients
Qazi et al. ¹⁷	2015	2	TEP	Primalene mesh	No	12 min	Mean 12 months	None	250ml	None	None
Ludwig et al. ¹⁰	2016	11 (11)	TEP	Max, Parietex anatomic mesh, Multifilament polyester mesh	No	30 min	Mean 33 months	None	210 ml	None	Seroma in a patient, Lymphocele (required drainage) in a patient
Mourmouris et al. ¹⁶	2016	29/37	Darning suture technique	Suture alone	-	6 min	Mean 32 months	-	175ml	None	None
Our series	-	20/25	TAPP	Ventralight mesh, Sepramesh mesh and 3DMax (Polypropylene) mesh	Only in one patient which polypropylene mesh applicated	27 min 13 months	Median	None	108 ml	None	Wound evisceration at in a patient

cal examination. All patients had sterile urinalysis and urine culture. Preoperative patient characteristics (age, body mass index) prostate specific antigen(PSA), intra and postoperative parameters (pathological Gleason grade, prostate volume at RP specimen, operative time, estimated blood loss, complications, lymph node dissection, time of hospitalization, catheterization and drainage) were entered into prospective database.

Inguinal hernia repairing technique: We have started IH repair with mesh application since (June 2015) after our two robotic urologic surgeons (AFA and AEC) attending a hands-on training course organized by general surgeons who are experienced on laparoscopic IH repair. All RARP procedures were performed by two experienced surgeons (AFA, AEC) by applying the surgical technique as previously described in the literature.⁽¹³⁾

All hernias were repaired robotically after completing pelvic lymph node dissection when indicated, and ensuring a watertight vesico-urethral anastomosis and good hemostasis. Before applying the mesh over the hernia defect, the hernia sac was dissected and fixed to the pubic bone (**fig 1a and fig 1b**). Ventralight™ ST (Bard, Davol Inc., Warwick, RI, UK), Sepramesh™ IP (Bard, Davol Inc., Warwick, RI, UK), and 3DMax™ (Bard, Davol Inc., Warwick, RI, UK) meshes were used for 10, 13 and 2 procedures, respectively. Before opening sterile mesh, the bedside assistant and nurse change gloves in order to decrease the risk of contamination. A proper size of the mesh was chosen according to the defect size (**fig 1c**). A laparoscopic tacker was used applied to fix the mesh material around the hernia defect (abdominal wall and upper side of the pubic bone) (**Figure 1d**). Addition to tacker, we fixed the mesh with

running absorbable sutures. After the procedure drain was inserted. Reperitonealization was performed only in one patient (bilateral procedure) which was 3DMax™ mesh (polypropylene) applied. All mesh application procedures were performed by two same experienced surgeons (AFA, AEC). Postoperative cystogram was performed on postoperative day 7 in all patients who underwent RARP. If no extravasation is observed, the catheter is removed.

Evaluations: Standard PSA control and postoperative complications of mesh application such as hernia recurrence, mesh infection, seroma formation and groin pain were evaluated at every follow-up visits (every 3 months in the first year, then every 6 months in years 2 to 5 and annually thereafter). Hernia recurrence was evaluated according to surgeon physical examination. Presence of symptoms including fever, hyperemia, swelling and pain on the groin localization considered as mesh infection. The presence of groin pain was evaluated according to patient's statement.

RESULTS

In 20 patients, totally 25 concurrent IH repair procedures were performed at the time of RARP. The mean age and mean PSA value of the patients were 66 ± 8 years (range: 49-79 years) and 8.2 ± 3.2 ng/mL (range: 3.9-17.2), respectively. Fifteen (60 %) patients had unilateral hernia and 5 (40 %) patients had bilateral hernias. Four (20 %) patients had previous abdominal surgery (appendectomy in 3 patients, laparoscopic cholecystectomy in 1 patients) history. The mean total operative time was 139 ± 21 minutes (range: 100-195 minutes) and estimated mean blood loss was 108 ± 76 mL (range: 10-300). Perioperative blood transfusion was never deemed necessary. The mean duration of IH repair in patients which was 27 ± 5 (range: 17-40) min. No conversion to open surgery was necessary. Eleven (55 %) patients underwent bilateral extended pelvic lymph node dissection during RARP. The mean time of drainage, hospitalization and catheterization were 2.5 ± 0.8 days (range: 2-6), 4 ± 0.9 days (range: 2-7) and 8.2 ± 1.9 days (range: 7-14), respectively. The demographic and pathological data were detailed in **Table 1**.

We did not observe any intra-operative complication due to RARP or IH repair. At post-operative period, wound evisceration at camera port place which was lengthened and used and for specimen extraction over the umbilicus requiring primary closure under general anesthesia developed in a patient on postoperative day 20. Groin pain, wound infection or seroma were not developed in our population. Our median follow-up duration was 13 months and we did not observe mesh infection or hernia recurrence during the follow-up.

DISCUSSION

The IH is seen in 25% of the general male population during lifetime.⁽¹⁴⁾ The IH can occur at any age, however, the peak incidence is during early childhood (0-5 age) and over 75 ages.⁽¹⁴⁾ The PCa is also seen in older age. Thus, PCa and IH are can be detected concomitantly.

The incidence rate of asymptomatic IH which is detected during prostatectomy approached up to 33%.² In a retrospective study, asymptomatic IH was detected in 20.4% of the patients who underwent RP by preoperative computed tomography.⁽¹⁾ On the other hand, IH is

considered a manifest of RP by many authors and the incidence of IHs is higher in men undergoing RP when compared with non-operated men.⁽³⁻⁴⁾ First, Regan et al. reported that significantly higher incidence of IH is developed after RP (12%) when compared with the general population (5%).⁽³⁾ More recently, National Prostate Cancer Register of Sweden reported that the incidence of IH repair were 14% and 10% in men who were treated with retropubic RP and with minimal invasive RP, respectively whereas 4% in control population.⁽⁴⁾ Therefore, PCa surgery either minimal invasive or open seem to be a risk factor postoperative IH development. In the light of technological developments, the trend of RP gradually shifted towards RARP since reporting similar oncological and functional outcomes.⁽¹⁵⁾ Nowadays, especially in developed countries, majority of RPs are performed with robotic assistance. Concordantly, a few articles have been published on concurrent IH repair with RARP with different hernia repairing technique.^(7-10,16,17) These publications are summarized in **Table 2**. Our outcomes were consistent with previous studies.

Concurrent repair of IH during RARP has several advantages. First, operation time for concurrent repair is shorter when compared both surgeries are performed separately.^(7,12,16) Additionally, this would be an additional morbidity due to second surgical procedure on the patient with additional anesthesia exposure. Second, if the IH is not repaired concurrently during RARP procedure, it might be more difficult to repair it via laparoscopic or robotic surgery due to scarring in the preperitoneal space in the following months after the previous RARP procedure.^(12,16)

Concerns might be present related with concurrent IH repair with mesh during RP due to the possible risk of mesh infection, postoperative inguinal pain, postoperative bowel adhesions, seroma formation and other complications. The theoretical risk of infection arises from the possibility that the mesh may contact with urine in the presence of vesico-urethral anastomosis. However, there is no evidence about that concurrent IH repair during RP increases risk of mesh infection based on previous studies.⁽⁷⁻¹⁰⁾ Mesh is a foreign body and there is a risk for adhesions to intraperitoneal structures. Reducing this risk can be achieved with two methods. First, reperitonealization may be safely achieved after the completion of prostatectomy to avoid contact of mesh with intraperitoneal structures. Second, using adhesion-resistant, coated mesh is another solution that reduces risk of adhesion formation while avoiding related postoperative complications. Finley et al. did not experience mesh-related complications in patients undergoing simultaneous RARP and IH repair.⁽⁷⁾ We used adhesion-resistant coated mesh (Dual meshes) in 19 patients. Polypropylene mesh was used only in a patient. In this case, we closed the anterior peritoneum for reducing bowel adhesion risk.

Seroma formation is a frequent complication after hernia repair especially in incisional hernia patients.^(18,19) However, the incidence of seroma development ranged between 1.9 to 22.9% after laparoscopic IH repair.^(19,20) Bansal et al. evaluated the rate of seroma formation after laparoscopic TAPP and TEP procedures.⁽²¹⁾ They reported their seroma formation rates as 32.5% and 16.2% after postoperative day 7 for TEP and TAPP groups, respectively, while these rates were 3.7% and 1.9% after

1 month.⁽²¹⁾ This rate is very low in series of concurrent IH repair with RARP. Seroma formation was reported in one patient only by Ludwig et al.⁽¹⁰⁾ There were no seroma formation in other concurrent IH repair with RARP series.^(7-9,16,17) The etiology of seroma formation remains unknown, but it seems to be due to a local inflammatory response to a mechanical injury by tissue aggression during surgery and the presence of foreign bodies such as mesh.⁽¹⁹⁾ Most seromas are asymptomatic and resolve spontaneously without any intervention. However, seroma persistence over 6 weeks can become a major problem for patients, impairing their quality of life due to discomfort sense, pain, and cosmetic reasons.^(18,19) Infected seromas can also lead mesh removal or hernia recurrence.⁽²²⁾ Preventing of seroma formation can be achieved with good hemostasis, drainage of subcutaneous tissue, compression to surgery side, and fixing the mesh with running absorbable sutures to prevent the formation of dead space.⁽²²⁾ We did not observe seroma formation in our patients. This outcome may depend on that our patients have non-complex IHS and our patients have no previous unsuccessful hernia surgery. Moreover, we fixed the mesh to aponeurosis with tacks and running absorbable sutures combination in majority of our patients.

Another concern related with RARP and concurrent IH repair might be prolonged lymphatic drainage in patients with extended pelvic lymph node dissection. In our series 11 patients had extended pelvic lymph node dissection. The main drainage catheter removal time was 2.4 ± 0.8 days in these patients and we did not have any patient with prolonged lymphatic drainage. Stolzenburg et al.⁽⁶⁾ observed prolonged lymphatic drainage in 5 of 10 patients who underwent laparoscopic radical prostatectomy and concurrent IH repair, however no lymphocele or additional problems were observed. In current literature, the rate of symptomatic lymphocele (which required drainage) development during minimal invasive RP and concurrent IH repair is up to 5%.^(9,10) Lymphocele which was asymptomatic and did not require intervention was developed in one of our patients. The main concern in lymphocele development is probability of mesh infection. In order to prevent prolonged lymphatic drainage, it might be important to apply endoclips during performing extended pelvic lymph node dissection rather than applying only cautery that could be expected to prevent postoperative prolonged lymphatic drainage particularly in patients who underwent robotic TAPP repair with RARP procedure.

Our surgeons (AFA, AEC) are experienced (each performing more than one hundred cases per a year) in RARP surgery. They participated in hands on training course on laparoscopic IH repair which was organized by general surgeons before starting to TAPP operations. Our surgeons performed the initial TAPP procedures under supervision of a general surgeon which experienced in laparoscopic hernia repair surgery.

Our study has several limitations. First, the nature of the study is retrospective despite all data were recorded prospectively. Second, this study is limited by the small numbers of patients which may affect the reliability of the statistical analysis. Third, although same RARP technique was used, IH repairs were performed by two surgeons performed which may add variability to our results. Fourth, none of the patients had previous hernia repairs, so we cannot draw conclusions for cases with

previous herniorrhaphy. Finally, our follow up time is short and we cannot present definitive conclusions such as long term hernia recurrence rate.

CONCLUSIONS

Due to our experience, concurrent IH repair with mesh during RARP procedure seem to be easy to perform, effective and safe following taking specific precaution such as having a proper initial training, obtaining a preoperative sterile urine culture, intraoperative good hemostasis, a watertight vesico-urethral anastomosis and sufficient endoclip application for extended pelvic lymph node dissection.

CONFLICT OF INTEREST

None declared.

REFERENCES

1. Fukuta F, Hisasue S, Yanase M, et al. Preoperative computed tomography finding predicts for postoperative inguinal hernia: New perspective for radical prostatectomy-related inguinal hernia. *Urology*. 2006; 68: 267-71.
2. Nielsen ME and Walsh PC. Systematic detection and repair of subclinical inguinal hernias at radical retropubic prostatectomy. *Urology*. 2005; 66: 1034-7.
3. Regan TC, Mordkin RM, Constantinople NL, Spence IJ, Dejter SW Jr. Incidence of inguinal hernias following radical retropubic prostatectomy. *Urology*. 1996; 47: 536-7.
4. Nilsson H, Stranne J, Stattin P, Nordin P. Incidence of Groin Hernia Repair After Radical Prostatectomy A Population-Based Nationwide Study. *Ann Surg*. 2014; 259: 1223-7.
5. McDonald DF and Higgins C. Simultaneous prostatectomy and inguinal herniorrhaphy. *Surg Gynecol Obstet*. 1949; 89: 621-3.
6. Stolzenburg JU, Rabenalt R, Dietel A, et al. Hernia repair during endoscopic (laparoscopic) radical prostatectomy. *J Laparoendosc Adv Surg Tech*. 2003; 13:27.
7. Finley DS, Savatta D, Rodriguez E, Kopelan A, Ahlering TE. Transperitoneal robotic-assisted laparoscopic radical prostatectomy and inguinal herniorrhaphy. *J Robot Surg*. 2008; 1: 269-72.
8. Joshi AR, Spivak J, Rubach E, Goldberg G, DeNoto G. Concurrent robotic trans-abdominal pre-peritoneal (TAP) herniorrhaphy during robotic-assisted radical prostatectomy. *Int J Med Robot*. 2010; 6: 311-4.
9. Do M, Liatsikos EN, Kallidonis P, et al. Hernia repair during endoscopic extraperitoneal radical prostatectomy: outcome after 93 cases. *J Endourol*. 2011; 25: 625-9.
10. Ludwig WW, Sopko NA, Azoury SC, et al. Inguinal Hernia Repair During Extraperitoneal Robot-Assisted Laparoscopic Radical Prostatectomy. *J Endourol*. 2016; 30: 208-11.

11. Forbes SS, Eskicioglu C, McLeod RS, Okrainec A. Meta- analysis of randomized controlled trials comparing open and laparoscopic ventral and incisional hernia repair with mesh. *Br J Surg.* 2009; 96: 851-8.
12. Kaler K, Vernez SL, Dolich M. Minimally Invasive Hernia Repair in Robot-Assisted Radical Prostatectomy. *J Endourol.* 2016; 30: 1036-40.
13. Canda AE, Atmaca AF, Akbulut Z, et al. Results of robotic radical prostatectomy in the hands of surgeons without previous laparoscopic radical prostatectomy experience. *Turk J Med Sci.* 2012; 42: 1338-46.
14. Jenkins JT and O'Dwyer PJ. Inguinal hernias. *BMJ.* 2008; 336: 269-72.
15. Mustafa M, Davis JW, Gorgel SN, Pisters L. Robotic or Open Radical Prostatectomy in Men with Previous Transurethral Resection of Prostate. *Urol J.* 2017; 14: 2955-60.
16. Mourmouris P, Argun OB, Tufek I, et al. Nonprosthetic Direct Inguinal Hernia Repair During Robotic Radical Prostatectomy. *J Endourol.* 2016; 30: 218-22.
17. Qazi HA, Rai BP, Do M, et al. Robot-assisted laparoscopic total extraperitoneal hernia repair during prostatectomy: technique and initial experience. *Cent European J Urol.* 2015; 68: 240-4.
18. Morales-Conde S. A new classification for seroma after laparoscopic ventral hernia repair. *Hernia.* 2012; 16: 261-7.
19. Cihan A, Ozdemir H, Ucan BH, et al. Fate or fate. Seroma in laparoscopic inguinal hernia repair. *Surg Endosc.* 2006 20: 325-8.
20. Lau H and Lee F. Seroma following endoscopic extraperitoneal inguinal hernioplasty. *Surg Endosc.* 2003; 17: 1773-7.
21. Bansal VK, Misra MC, Babu D, et al. A prospective, randomized comparison of long-term outcomes: chronic groin pain and quality of life following totally extraperitoneal (TEP) and transabdominal preperitoneal (TAPP) laparoscopic inguinal hernia repair. *Surg Endosc.* 2013; 27: 2373-82.
22. Birolini C, de Miranda JS, Utiyama EM, Rasslan S. A retrospective review and observations over a 16-year clinical experience on the surgical treatment of chronic mesh infection. What about replacing a synthetic mesh on the infected surgical field? *Hernia.* 2015; 19: 239-46.