

## Comparison of Incision Types Used for Kidney Extraction in Laparoscopic Donor Nephrectomy: A Retrospective Study

Selçuk Şahin<sup>1</sup>, Osman Özdemir<sup>1</sup>, Mithat Ekşi<sup>2</sup>, İsmail Evren<sup>1</sup>, Serdar Karadağ<sup>1</sup>,  
Deniz Noyan Özlü<sup>1\*</sup>, Ali İhsan Taşçı<sup>1</sup>

**Purpose:** Laparoscopic donor nephrectomy (LDN) is the most commonly used method for kidney removal in kidney transplantation and, various incisions are used for kidney extraction. In this study, we aimed to compare the results of LDN operations using iliac fossa incision and Pfannenstiel incision.

**Material and Method:** LDN cases performed in our institute between June 2016 and February 2020 were retrospectively analyzed. Patients with previous abdominal surgery, bleeding coagulation disorders, ectopic kidneys, and patients who were converted to perioperative open surgery were excluded. Demographic data of the patients, operation times, warm ischemia times, complications were recorded and the patients were divided into two groups according to incision types.

**Results:** After the inclusion and exclusion criteria, 203 patients were included in the study. Iliac fossa incision was used in 65% of the patients and the Pfannenstiel incision was used in 35% of the patients to remove the donor's kidney. There were no difference in age, body mass index, gender, and Charlson Comorbidity Index (CCI) scores between the two groups. Operation time and warm ischemia time were significantly longer in the Pfannenstiel group ( $p = 0.001$  and  $p = 0.016$  respectively). There was no significant difference between the two groups in terms of bleeding amount, length of hospital stay, need for narcotic analgesic, visual analog scale scores, and postoperative complications.

**Conclusion:** Both types of incisions can be used successfully and safely for the extraction of the kidney in LDN. Although WIT and operation time has been observed to be longer when a Pfannenstiel incision is made, complications and analgesic use are not different between Pfannenstiel incisions and iliac fossa incisions.

**Keywords:** Laparoscopic donor nephrectomy; kidney transplantation; pfannenstiel incision; iliac fossa incision

## INTRODUCTION

The gold standard treatment for end-stage renal disease (ESRD) is renal transplantation<sup>(1)</sup>. In this procedure, donor nephrectomy can be performed through open, laparoscopic, or robot-assisted surgery. As minimally invasive surgical approaches have gained widespread use, laparoscopic donor nephrectomy (LDN) has become the standard approach in many transplantation centers because of its advantages including a short recovery time and minimal postoperative pain<sup>(1,2)</sup>.

In LDN, time from clamping of the aorta or renal artery to cold perfusion is defined as the warm ischemia time (WIT) and is reported to be associated with postoperative early graft function<sup>(3,4)</sup>. Therefore, it is important to extract the kidney through a healthful and fast approach. To perform LDN; the Pfannenstiel incision, vertical midline incisions, and iliac fossa incisions are frequently used for the extraction of the harvested kidney<sup>(5-9)</sup>.

In the literature, there are studies comparing different incision types in kidney extraction in laparoscopic donor nephrectomy<sup>(10-13)</sup>. In this study, we have aimed to

compare the results of two routinely performed incisions for LDN in our clinic, namely iliac fossa incisions and the Pfannenstiel incision. To the best of our knowledge, our study is one of the largest series of single surgeons comparing these two incisions.

## MATERIAL AND METHODS

### Study Design and Patient Selection

LDN cases, performed in the period between June 2016 and May 2021 in Bakırköy Dr. Sadi Konuk Research and Training Hospital, were reviewed retrospectively. To eliminate learning curve effects, the first 35 cases for both techniques were excluded from the study<sup>(14)</sup>. Other exclusion criteria were patients with severe intraperitoneal adhesions due to previous abdominal surgery, conversion of the laparoscopic procedure to open surgery perioperatively, presence of bleeding-clotting disorders, and presence of an ectopic kidney. Patients undergoing iliac fossa incisions were assigned to Group 1 and patients undergoing a Pfannenstiel incision were

<sup>1</sup>Bakirkoy Dr. Sadi Konuk Training and Research Hospital, Department of Urology, Istanbul, Turkey.

<sup>2</sup>Arnavutköy State Hospital, Department of Urology. Istanbul, Turkey.

\*Correspondence: University of Health Sciences Bakirkoy Dr. Sadi Konuk Training and Research Hospital, Department of Urology, Istanbul, Turkey . Zuhuratbaba Mah, Dr. Tevfik Sağlam Cd No:11, 34147 Bakırköy/İstanbul

Phone: +90 535 233 6440 Fax: +90 212 414 7280. noyanozlu@hotmail.com.

Received March 2022 & Accepted October 2022

**Table 1.** Comparison of parameters according to incision types.

Parameters (mean ± SD)	Total (n=203)	Group 1 n=132 (65)	Group 2 n=71 (35)	p
Age (years)	48.6 ± 12.4	49 ± 12.3	47.2 ± 12.9	0.437*
Gender (n ; %) Male	95 (46.7)	60 (45.4)	35 (49.2)	0.709**
BMI (kg/m <sup>2</sup> )	25.2 ± 2.1	25.3 ± 3.9	26 ± 3.2	0.450*
Side (n ; %) Left	196 (96.6)	127 (96.2)	69 (97.2)	0.593!
Incision length (cm)	5.4 ± 0.6	5.2 ± 0.5	6 ± 0.6	0.0001*
No. of Ports	3.2 ± 0.4	3 ± 0.1	4 ± 0.1	0.0001*
No. of Renal Arteries	1.1 ± 0.4	1.1 ± 0.4	1.2 ± 0.4	0.571*
Operation time (mn)+	90 (12.5)	90 (15)	95 (15)	0.000&
Warm ischemia time (sc)	92.4 ± 5.4	91.9 ± 5.4	94.2 ± 5	0.016*
EBL (cc) +	50 (20)	50 (20)	50 (15)	0.568&
Length of Stay (days)	2.2 ± 0.6	2.2 ± 0.6	2.2 ± 0.5	0.787*

**Table 1:** \*Independent T test    \*\*Chi-Square Test    ! Fisher Exact Test    & Mann-Whitney U Test  
+ Presented as Median (IQR) BMI: Body Mass Index    EBL: Estimated Blood Loss

assigned to Group 2. Approval for this retrospective study was obtained from the same hospital (Approval no: 2020-352).

### Preoperative evaluation

Standard laboratory tests, immunological tests, urinary ultrasound examinations, and Doppler ultrasound tests to assess the condition of the iliac artery of the transplant candidate were performed. Computed tomography angiography (CTA) was performed to evaluate the vascular structure of the candidate donor. Renal scintigraphy was performed to evaluate the function of separate donor kidneys.

All donor nephrectomy operations were performed laparoscopically by a single surgeon (S.Ş). After the nephrectomy was completed, the kidney was extracted through an iliac fossa incision or a Pfannenstiel incision. The length of incisions, the number of ports, the number of arteries, operative times, WIT, bleeding volume, and perioperative complications were recorded in order to analyze perioperative data by the incision type. WIT was defined as the period from the time of clamping the artery of the graft until the time of immersion of the graft into ice water. In order to evaluate postoperative data; the length of hospital stay, the need for narcotic analgesics, wound site infections, and the development of incisional hernia were recorded. The visual analog scale (VAS) was used for assessing postoperative 24th hour pain. On this scale, the score of 10 described severe pain, while the score of 0 described benign completely painless. Postoperative complications were recorded according to the Clavien-Dindo classification<sup>(15)</sup>.

### Surgical Technique

#### Iliac Fossa Incision

In the lateral decubitus position, a 5-6 cm oblique incision was made in the transverse line parallel to the inguinal ligament, starting from a distance of 5 cm to

the superior iliac spine and after the dissection of the fascia and the peritoneum and opening of the surgical site, the GelPort (Applied Medical, Rancho Santa Margarita, CA, USA) was placed into this area (**Figure 1**). Using the GelPort system, CO<sub>2</sub> insufflation was performed and the intra-abdominal pressure was increased to 15 mmHg. A 5-mm-port was placed approximately 4 cm lateral to the umbilicus and another 5-mm-port was placed approximately 3 cm inferior to the intersection point of the costal margin and the lateral rectus muscle. Then, the intra-abdominal pressure was adjusted to 12 mmHg. The colon was dissected along the line of Toldt and medialized. Then, the ureter was found on the psoas muscle. The ureter and the surrounding tissues were retracted. To retract the ureter, another 5-mm-port was inserted through the intersection point of the anterior axillary line and a transverse line at the level of the umbilicus. Tracing the ureter, the hilus of the kidney was reached. The renal artery and the renal vein were dissected and completely liberated from the surrounding tissue. After processing the renal pedicle, the kidney was liberated from the surrounding tissue and mobilized. The ureter was clamped and transected. A Multifire Endo-TA Stapler (Covidien, Walpole, Massachusetts, ABD) was used to ligate and transect the renal artery. A Hem-o-Lock® Clip (Teleflex Medical, Research Triangle Park, North Carolina, USA) was used to ligate and transect the renal vein. The kidney was extracted through the GelPort under direct vision manually. The purpose of Gelport in our procedures is not a hand-assisted laparoscopy technique, but to be used for kidney extraction at this stage. A draining catheter was placed and the operation was terminated.

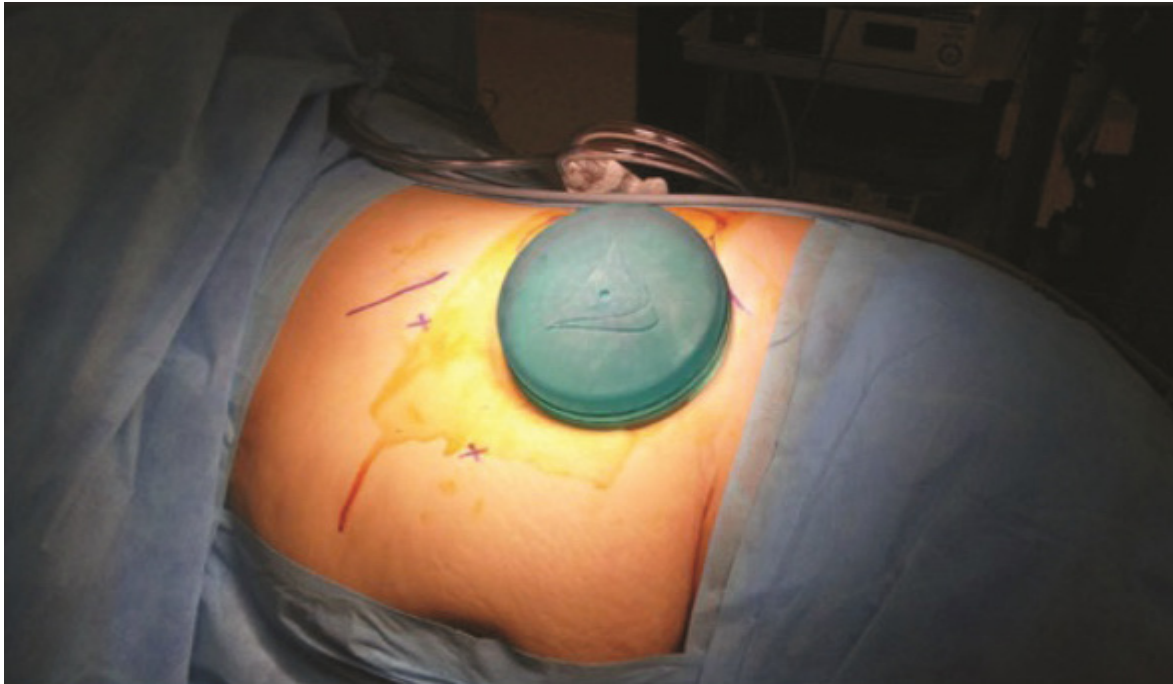
#### Pfannenstiel Incision

In the supine position, a Pfannenstiel incision of approximately 6 cm was made in the suprapubic region. Tissue layers were passed through to reach the peritoneum.

**Table 2.** Perioperative complications and visual analog scale scores.

Narcotic Analgesic Requirement (n ; %)	8 (4.6)	8 (6)	2 (2.8)	0.201!
VAS	3.7 ± 0.9	3.9 ± 1.1	3.4 ± 0.8	0.611**
Perioperative Complication (n ; %)				
1	8 (3.5)	5 (3.7)	3 (4.2)	0.569!
2	9 (3.9)	7 (5.3)	2 (2.8)	
3	5 (2.5)	3 (2.2)	2 (2.8)	
Wound site infection (n ; %)	6 (3)	4 (3)	2 (2.8)	0.844**
Incisional Hernia	0 (0)	0 (0)	0 (0)	-

\*\*Chi-Square Test    ! Fisher Exact Test    + Presented as Median (IQR)  
VAS: Visual analog scale



**Figure 1:** Port placement in the iliac fossa incision group

The peritoneum was not dissected. Subsequently, only the skin layer of the incision was sutured continuously with a 3/0 polypropylene suture, leaving the most lateral 1.5 cm of the donor kidney side open. (Figure 2a) Then, the site was closed with a sterile bandage. Then, the patient was placed in the lateral decubitus position (Figure 2b). To perform a right donor nephrectomy, an incision was made at the level of the umbilicus along with the line corresponding to the margin of the lateral rectus muscle. Passing through the skin and subcutaneous tissue, the fascia was reached. CO<sub>2</sub> insufflation was initiated after entering the intraperitoneal area with the Verres needle. For the left side, a Veress needle was introduced through Palmer's point. The intra-abdominal pressure was increased to 15 mmHg. Through the same point, a 10-mm-port was placed. Subsequently, a 5-mm-port was placed approximately 3 cm inferior to the intersection point of the costal margin and the lateral rectus muscle and a 10-mm-port were placed approximately at a distance of 6 cm inferiorly and laterally to the camera port. From this stage until clipping the renal pedicle, the procedures were performed in the same way using the same technique as we described in the iliac fossa incision. Then, another port was inserted under direct vision through the abovementioned 1.5-cm-opening at the most lateral part of the Pfannenstiel incision. Through this port, a Multifire Endo-TA Stapler (Covidien, Walpole, Massachusetts, ABD) was placed on the renal artery and a Hem-o-Lock® Clip (Teleflex Medical, Research Triangle Park, North Carolina, USA) clip was applied to the renal vein. Subsequently, the renal artery and the renal vein were ligated and transected. The sutures at the Pfannenstiel incision were removed and the kidney was extracted manually. A draining catheter was placed and the operation was terminated. The study was approved by the University of Health Sciences, Dr. Sadi Konuk Training and Research Hospital Ethical Committee, Bakirkoy, Istanbul, Turkey

(Decision No: 2020-352). Informed consent was obtained from all the patients.

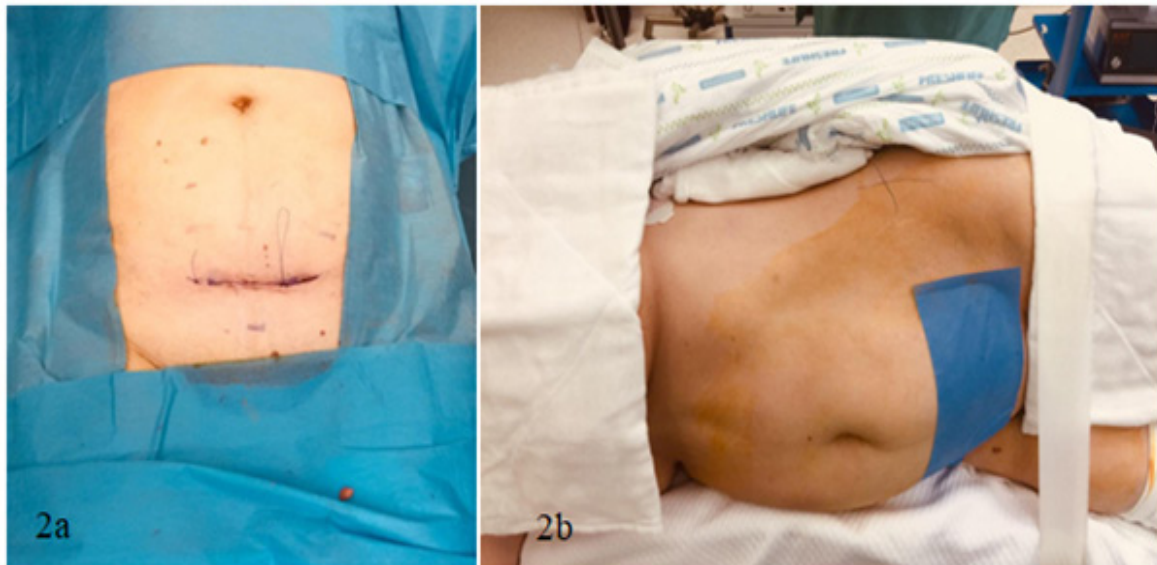
#### Statistical Analysis

For statistical analyses, the NCSS (Number Cruncher Statistical System) 2007 (Kaysville, Utah, USA) software was used. The continuous variables were given as means  $\pm$  standard deviations. The nonnormally distributed variables were presented as medians and interquartile ranges. Categorical data were presented as numbers and percentages. The normality of quantitative data was tested by the Shapiro-Wilk test and graphical plots such as Q-Q plot. The student's t-test was used to compare two groups conforming to a normal distribution. The Levene's test used to assess the equality of the variances. The Mann-Whitney U test was used to compare two groups that did not conform to a normal distribution. To compare qualitative data, the Pearson's Chi-Square test were used if  $\leq 20\%$  of expected cell counts are less than 5, the Fisher's exact test were used if  $>20\%$  of expected cell counts are less than 5. Statistical significance was assessed according to a  $p$ -value of  $< 0,05$ .

#### RESULTS

Of the 203 patients included in the study, an iliac fossa incision was used in 65% ( $n = 132$ ; Group 1) and a Pfannenstiel incision was used in 35% ( $n = 71$ ; Group 2) to extract the donor's kidney. Between two groups, age, body mass index (BMI), gender, and Charlson Comorbidity Index (CCI) scores were similar. A comparison of parameters according to incision types can be seen in **Table 1**.

The median operative time was 90<sup>(15)</sup> minutes in Group 1 and 95<sup>(15)</sup> minutes in Group 2. The operative time was statistically longer in Group 2 ( $p = 0.001$ ). WIT was  $91.9 \pm 5.4$  seconds in Group 1 and  $94.2 \pm 5$  seconds in Group 2, which was statistically significantly longer in



**Figure 2. a:** Pfannenstiel incision made in the supine position and the opening left for port insertion at the most lateral of the incision. **b:** Providing the lateral decubitus position after the Pfannenstiel incision is made and covered.

Group 2 ( $p = 0.016$ ). The mean length of hospital stay of the patients was found to be  $2.2 \pm 0.6$  days. The length of hospital stays and the bleeding volumes was not significantly different between the groups ( $p = 0.787$ ,  $p = 0.568$ , respectively).

Perioperative complications and VAS scores are observed in Table 2. In the postoperative period, 8 (6%) patients in Group 1 and 2 (2.8%) patients in Group 2 required narcotic analgesics. When evaluated in terms of VAS scores at the postoperative 24th hour, the mean VAS score was  $3.9 \pm 1.1$  in Group 1, while it was  $3.4 \pm 0.8$  in Group 2. There was no significant difference between the two groups in terms of narcotic analgesic need and VAS scores. ( $p = 0.201$  and  $0.611$ , respectively).

Complications developed in a total of 22 (10.8%) patients (Table 2). Of these patients; 8 had grade I, 9 had grade II, and 5 had grade III complications according to the Clavien-Dindo system. Wound site infections developed in 6 patients (3%) in the postoperative period. There was no significant difference between the two groups in terms of complications and wound site infections. An incisional hernia was not observed in any of the patients in the long term after the operation.

## DISCUSSION

LDN is used as the gold standard approach in many transplantation centers(2). Several types of incisions including midline incisions, Pfannenstiel incisions, or iliac fossa incisions are used to perform graft extraction in LDN. Each of them has advantages and disadvantages compared to other types of incisions<sup>(16,10)</sup>.

In the studies by Gupta et al, Adiyat et al, and Iemsupakkul et al; no differences in operative times were reported between operations using a Pfannenstiel incision or an iliac fossa incision<sup>(10-12)</sup>. However, a prospective randomized study has recently reported a shorter operative time in operations where a Pfannenstiel incision was used<sup>(13)</sup>. In contrast to similar studies in the literature, we have found the operative time longer in the Pfann-

enstiel incision group compared to the iliac fossa incision group in our study, and the difference between the two groups was found to be significant ( $p < 0.05$ ). This finding can be explained by the fact that; in contrast to the start of the operation after positioning the patient in the iliac fossa incision group, the operation started with the patient in the supine position in the Pfannenstiel incision group and the position of the patient was later changed to the lateral decubitus position after making the incision.

As for WIT; no differences in WIT were reported in the study performed by Gupta et al. but the study by Iemsupakkul et al. reported a longer WIT in operations, where a Pfannenstiel incision was used<sup>(11,12)</sup>. Contrary to those studies, another study comparing midline incisions with iliac fossa incisions have reported a statistically significantly shorter WIT in the group undergoing a Pfannenstiel incision<sup>(10)</sup>. In our study, WIT was longer in the Pfannenstiel incision group ( $p = 0.016$ ). The common point of Iemsupakkul et al.'s study and our study are not only the significant prolongation of the WIT in the Pfannenstiel group but also the preference for a completely laparoscopic technique, not using the hand-assisted technique<sup>(12)</sup>. They attributed the lengthening of the WIT to the length of the distance between the position of the incision and the kidney. As can be seen, the results of studies related to WIT are controversial in the literature. We suggest that such different results may be associated with the experience levels of teams. Surgeons may be achieving better results when they use the technique with which they are more experienced. Moreover, we think that the use of the GelPort in the iliac fossa incision group but not in the Pfannenstiel incision group in our study played a role in obtaining different WIT values between the groups. On the other hand, statistically significant differences in WIT values should be investigated further by examining graft functioning in recipients in order to be able to evaluate potential clinical implications.

It is reported that bleeding volumes were not significantly different by the incision type across the groups<sup>(10-12)</sup>.

Similarly, in our study, there was no statistically significant difference in bleeding volumes between the two groups.

Results of comparisons of incision lengths are variable in the literature. Incisions were reported to be significantly longer in the Pfannenstiel incision group in the study by Gupta et al.; however, Adiyat et al. reported that lengths of midline incisions were shorter compared to the lengths of iliac fossa incisions and Pfannenstiel incisions<sup>(10,11)</sup>. In a meta-analysis; which included both of those studies, it was reported that the groups were significantly heterogeneous but there were no significant differences in incision lengths<sup>(16)</sup>. In our study, we have found that incision lengths were significantly longer in the Pfannenstiel group ( $p = 0.0001$ ). There was an extra incision because of the use of an extra port in patients in the Pfannenstiel incision group.

Studies in the literature reported a similar length of hospital stays according to incision type,<sup>(10,11,13)</sup> and there was no statistical difference between the groups in our study.

In the literature, it has been reported that the need for analgesic use is less in the patient group who underwent Pfannenstiel incision compared to the iliac fossa group<sup>(11)</sup>. Also, in the same study, VAS scores were compared between the two groups. While no significant difference was observed in both groups in the first 4 hours postoperatively, the Pfannenstiel incision group reported less pain at the postoperative 24th hour. In our study, it was observed that the patients in the Pfannenstiel incision group required less narcotic analgesics in the postoperative period and reported a lower VAS score, but no significant difference was found. We think that retracting the muscles instead of making the incision in patients with Pfannenstiel incision may lead to less analgesic requirement in the postoperative period. A meta-analysis study in the literature reported that wound site complications were not significantly different across groups<sup>(16)</sup>. Gupta et al. reported that two patients developed wound site infections in the iliac fossa incision group, whereas, two patients developed wound dehiscence and 6 patients developed wound site infections in the Pfannenstiel incision group. On the contrary; in the study by Adiyat et al., no wound site infections were reported in the Pfannenstiel incision group, but wound site complications occurred in 7 patients in the iliac fossa incision group<sup>(10,11)</sup>. In our study, we observed a wound site infection in only two patients in the Pfannenstiel incision group but wound site infections developed in four patients in the iliac fossa incision group.

It has been reported that bladder and bowel injuries may occur during the extraction of the kidney through a Pfannenstiel incision. Performing a Pfannenstiel incision in the lateral decubitus position might be more difficult and lead to small intestine injuries in patients<sup>(11)</sup>. In our study, no bladder or bowel injury was observed in the Pfannenstiel group. We think that our surgical technique did not lead to any bladder and bowel injuries in the Pfannenstiel incision group because the incision was made with the patient in the supine position and, then the position of the patient was changed to the lateral decubitus position after the preparation of the incision site. At the last stage of the operation, while placing the trocar and other working tools through the incision, the procedures should be performed under direct vision and

incisions should be made attentively to prevent bowel injuries during the extraction of the kidney.

The GelPort was used to perform LDN with an iliac fossa incision. After making the incision just enough to extract the kidney and entering into the peritoneal cavity, placing the GelPort prevents gas leakage and allows extracting the kidney in a short time. Another advantage of the GelPort is that it allows hand-assisted surgery in case of the development of any perioperative complications. However, as we mentioned before, we do not routinely use the hand-assisted laparoscopy technique in standard donor nephrectomy procedures. Therefore, we think that the GelPort should be used especially at the beginning of the learning curve. The major disadvantage of the GelPort can be the high cost. In our clinic, we have used the GelPort and performed iliac fossa incisions in LDN cases since 2019 but, since then, we have started performing Pfannenstiel incisions to reduce costs.

In the study of Iemsupakkul et al., cosmetic results were worse in the Pfannenstiel group, but statistical significance could not be obtained<sup>(12)</sup>. However, on the contrary, there are studies in the literature in which Pfannenstiel incision gives more satisfactory cosmetic results<sup>(11,13)</sup>. In a randomized study comparing standard laparoscopic live donor nephrectomy and mini-laparoscopic donor nephrectomy<sup>(17)</sup>, better cosmetic results were observed in the mini-laparoscopic donor nephrectomy group, although peri and postoperative findings were the same. The authors explained this situation as pubic hair covering the wound site<sup>(17,18)</sup>. We did not examine the cosmetic results between both incisions in our study, and this can be considered as one of the limitations of our study.

The strengths of our study are that the procedures were performed by a single surgeon experienced in laparoscopy, the cases with both techniques performed at the time of the learning curve were not included in the study, and the two commonly preferred methods were compared. The limitations of our study are the retrospective design, the unequal distribution of the number of patients between the two groups, and the use of the GelPort in only one arm of the study. When the Pfannenstiel incision is used, we think that the staples are placed at a steeper angle to the renal vessels during the closure of the renal pedicle, thus, the safety of the procedure will be promoted and longer segments of renal vessels can be harvested. However, our study design was not suitable to evaluate this suggestion and this may be another limitation.

## CONCLUSIONS

Both types of incisions can be used successfully and safely for the extraction of the kidney in LDN. Although WIT and operation time have been observed to be longer when a Pfannenstiel incision is made, complications and analgesic use are not different between Pfannenstiel incisions and iliac fossa incisions.

## CONFLICT OF INTEREST

The authors declare that they have no conflict of interest

## REFERENCES

1. Ratner LE, Ciseck LJ, Moore RG, Cigarroa FG, Kaufman HS, Kavoussi LR. Laparoscopic live donor nephrectomy. Transplantation.

- 1995;60:1047-9
2. Ng ZQ, He B. A proposed classification system and therapeutic strategy for chyle leak after laparoscopic living-donor nephrectomy: A single-center experience and review of the literature. *Exp Clin Transplant*. 2018;16:143-9
  3. Hellegering J, Visser J, Kloke HJ, D'Ancona FC, Hoitsma AJ, van der Vliet JA, et al. Deleterious influence of prolonged warm ischemia in living donor kidney transplantation. *Transplant Proc*. 2012;44:1222-6.
  4. Marzouk K, Lawen J, Alwayn I, Kiberd BA. The impact of vascular anastomosis time on early kidney transplant outcomes. *Transplant Res*. 2013;2:8-12
  5. Su LM, Ratner LE, Montgomery RA, Jarrett TW, Trock BJ, Sinkov V, et al. Laparoscopic live donor nephrectomy: Trends in donor and recipient morbidity following 381 consecutive cases. *Ann Surg*. 2004;240:358-63.
  6. Øyen O, Andersen M, Mathisen L, Kvarstein G, Edwin B, Line PD, et al. Laparoscopic versus open living donor nephrectomy: experiences from a prospective, randomized, single center study focusing on donor safety. *Transplantation* 2005;79:1236-40.
  7. Dubey D, Shrinivas RP, Srikanth G. Transumbilical laparoendoscopic single-site donor nephrectomy: Without the use of a single port access device. *Indian J Urol*. 2011;27:180-4.
  8. Allaf ME, Singer A, Shen W, Green I, Womer K, Segev DL, et al. Laparoscopic live donor nephrectomy with vaginal extraction: Initial report. *Am J Transplant* 2010;10:1473-7
  9. Silva ANS, Georgiades F, Bath MF, Hosgood SA, Nicholson ML. Iliac fossa muscle splitting incision in laparoscopic donor nephrectomy: a comparison with the suprapubic approach. *Urology*. 2020;143:142-6.
  10. Adiyat KT, Tharun BK, Shetty A, Samavedi S. Comparison of three different techniques of extraction in laparoscopic donor nephrectomy. *Indian J Urol*. 2013;29:184-7.
  11. Gupta M, Singh P, Dubey D, Srivastava A, Kapoor R, Kumar A. A comparison of kidney retrieval incisions in laparoscopic transperitoneal donor nephrectomy. *Urol Int*. 2008;81:296-300
  12. Iemsupakkul P, Kongchareonsombat W, Kijvikai K. Comparison of Pfannenstiel or extended iliac port site kidney extraction in laparoscopic donor nephrectomy: Do we have consensus? *Exp Clin Transplant*. 2017;15:138-42.
  13. Deshmukh CS, Ganpule AP, Sudharsan SB, Singh AG, Sabnis RB, Desai MR. Iliac fossa vs Pfannenstiel retrieval incision in laparoscopic donor nephrectomy: A critical analysis. *Arab J Urol*. 2019;17:318-25.
  14. Serrano OK, Bangdiwala AS, Vock DM, Berglund D, Dunn TB, Finger EB, et al. Defining the tipping point in surgical performance for laparoscopic donor nephrectomy among transplant surgery fellows: A risk-adjusted cumulative summation learning curve analysis. *Am J Transplant*. 2017;17:1868-78.
  15. Dindo D, Demartines N, Clavien PA. Classification of surgical complications: a new proposal with evaluation in a cohort of 6336 patients and results of a survey. *Ann Surg*. 2004;240:205-13
  16. Amer T, Biju RD, Hutton R, Alsawi M, Aboumarzouk O, Hasan R, et al. Laparoscopic nephrectomy – Pfannenstiel or expanded port site specimen extraction: a systematic review and meta-analysis. *Cent European J Urol*. 2015;68:322-9
  17. Simforoosh N, Hosseini Sharifi SH, Valipour R, Narouie B, Kamranmanesh MR, Soltani MH. Minilaparoscopy vs. standard laparoscopic donor nephrectomy: comparison of safety, efficacy and cosmetic outcomes in a randomized clinical trial. *Urol J*. 2015;12:2223-7.
  18. Simforoosh N, Basiri A, Tabibi A, Javanmard B, Kashi AH, Soltani MH, Obeid K. Living Unrelated Versus Related Kidney Transplantation: A 25-Year Experience with 3716 Cases. *Urol J*. 2016;13:2546-51.