

Dorsal Versus Ventral Anterior Urethral Spatulation in Posterior Urethroplasty

Jalil Hosseini, Mohammad Jabbari, Ali Kaviani, Mohammad Mohsen Mazloomfard, Hooman Mokhtarpour

Purpose: To compare dorsal versus ventral anterior urethral spatulation in posterior urethroplasty.

Materials and Methods: In a retrospective study, we evaluated the records of 320 posterior urethroplasties which have been done in our center over a 7-year period from January 2000 to December 2006. The results of dorsal and ventral anterior urethral spatulations were compared.

Results: The studied subjects consisted of 264 men and 54 prepubescent boys (≤ 15 years) with the mean age of 23 years (range, 5 to 84 years). The mean follow-up was 52 months (range, 27 to 107 months). Six o'clock (group A) and 12 o'clock (group B) anterior urethral spatulations were performed in 101 (32%) and 219 (68%) of the patients, respectively. The success rates were 96% and 87.6% in groups A and B, respectively ($P = .025$). There were no urethro-rectal fistula and perineal wound infection during the follow-up period.

Conclusion: Our data suggest that the dorsal anterior urethral spatulation in urethroplasty is more efficient than ventral anterior urethral spatulation in terms of treatment success outcome.

Keywords: urethra, urethral stricture, pelvic bones, retrospective study, complications

Urol J. 2010;7:258-61.
www.uj.unrc.ir

INTRODUCTION

Posterior urethral injury occurs in 10% of pelvic fractures.⁽¹⁾ The surgical management of pelvic fracture urethral distraction defects (PFUDD) has evolved significantly in the last 50 years. During 1970's, Turner-Warwick popularized a delayed one-stage perineal urethroplasty with urethral mobilization and anastomosis.⁽²⁾

The site of the injury is approached transperineally. Repair is affected by a series of steps starting with a full mobilization of the bulbar urethra (to capitalize on its elasticity) and progressing to corporal separation and inferior pubectomy. This would entail

rerouting of the urethra around the cruras of the penis when it is necessary to straighten out the natural curve of the bulbar urethra. It results in bridging the gap between the two ends of the urethra to allow an overlapping spatulated end-to-end anastomosis without tension.⁽³⁻⁴⁾ To achieve better mucus-to-mucus anastomosis with at least 32F lumen, the proximal and distal parts of the urethra should be spatulated in opposite directions.

Some urologists believe that spatulation of the distal urethra at 6 o'clock provides more blood supply to the surrounding

Infertility and Reproductive Health
Research Center, Department of
Reconstructive Urology, Shohada-
e-Tajrish Hospital, Shahid Beheshti
University, MC, Tehran, Iran

Corresponding Author:
Jalil Hosseini, MD
Infertility and Reproductive Health
Research Center, Shohada-e-
Tajrish Hospital, Department of
Reconstructive Urology, Shahid
Beheshti University, MC, Tehran, Iran
Tel: +98 21 2243 2558
Fax: +98 21 2203 8462
E-mail: jhosseinee@gmail.com

Received June 2009
Accepted May 2010

tissues;⁽⁵⁻⁸⁾ however, many spatulate the distal urethra in opposite directions.⁽⁹⁾ Although both techniques have been reported to be successful, no published paper has yet compared their efficiency and outcomes. The aim of this study was to compare the efficacy and safety of dorsal and ventral anterior urethral spatulation in posterior urethroplasty.

MATERIALS AND METHODS

We retrospectively evaluated the records of 320 posterior urethroplasties over a 7-year period from January 2000 to December 2006. The data of 101 patients who underwent dorsal spatulation (group A) were compared with 219 patients treated by ventral spatulation technique (group B). All of the patients had exactly the same history of PFUDD.

Pre-operative evaluations included taking medical and surgical history, physical examination as well as simultaneous retrograde urethrography and voiding cystourethrography. Thereafter, urethroscopy and flexible suprapubic cystoscopy were performed to assess the anterior and posterior urethral anatomy and determine the length of the defects.⁽¹⁰⁾ Posterior urethroplasty was scheduled at least 3 to 6 months after the pelvic fracture.

Surgical Technique

The patient was placed in the lithotomy position and under general anesthesia, an incision was made on the median raphe. Anterior urethra was dissected from the surrounding tissue, and the continuity of the urethra through obliterated scar tissue was cut. After removal of the scar and fibrotic tissue from posterior urethra, the end point of the urethra was opened by using flexible cystoscope. For spatulation of the urethral end, two protocols have been followed:

Protocol 'A' (Dorsal spatulation): Spatulating of anterior and proximal end of the urethra at 6 o'clock position (Figure 1).

Protocol 'B' (Ventral spatulation): Spatulating of anterior and proximal end of the urethra at 12 o'clock position (Figure 2).

Mucus-to-mucus anastomosis of the two urethral ends was performed using 6 absorbable 3-0 vicryl sutures. Urethral catheter was removed 3 weeks after the operation if there was no contrast extravasation in pericatheter urethrography. All the patients were followed up at 2, 3, 5, 7, 9, 15, 21, and 27 months postoperatively. They also underwent retrograde urethrography and urethrocystoscopy at 6 and 12 months after urethroplasty. If patients had new voiding problems or abnormal retrograde urethrography,

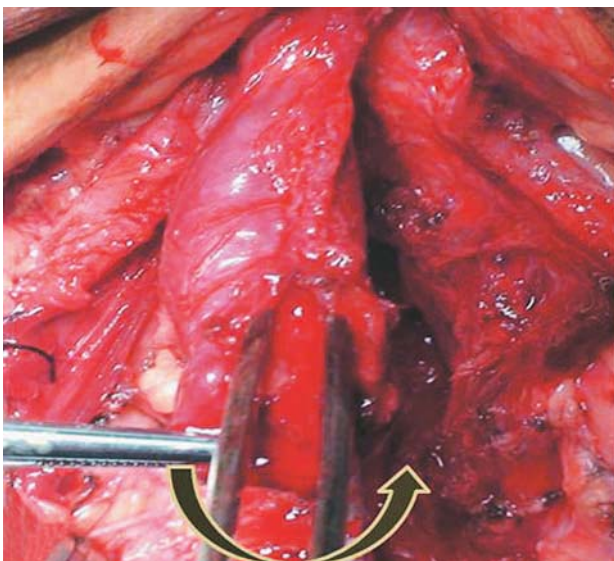


Figure 1. Spatulating anterior urethra at 6 o'clock position (Dorsal spatulation). Black arrow shows counter clockwise rotation of the urethra.

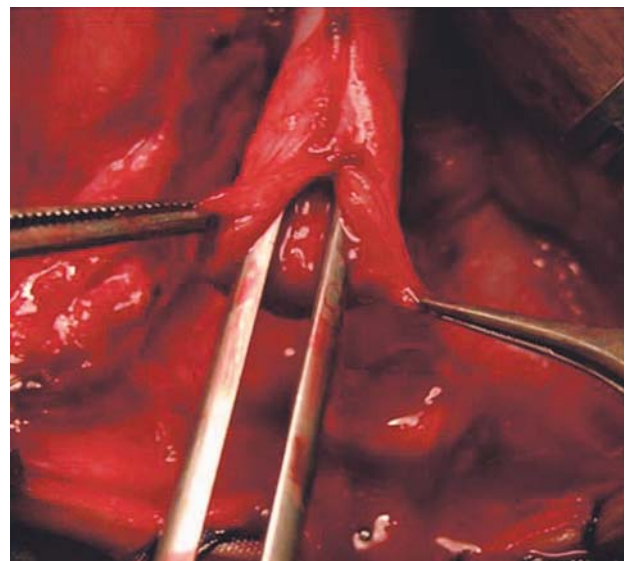


Figure 2. Spatulating anterior urethra at 12 o'clock position (Ventral spatulation).

they were evaluated by urethrocystoscopy. Successful operation was defined as the lack of stricture recurrence or defect after one internal urethrotomy.

Demographic characteristics, stricture length, mechanism of PFUDD (cause of pelvic fracture), past surgical history (previous urethrotomy or urethroplasty), type of procedure done (bulbomembranous or bulboprostatic anastomosis), maneuvers during urethroplasty (crural separation and inferior pubectomy), and success rate were compared between two groups. The ethical aspect of this study was approved by the ethics committee of Infertility and Reproductive Health Research Center. Statistical analysis was performed using Chi-square and Fisher's exact tests as appropriate with significance considered at *P* values less than .05.

RESULTS

The studied subjects consisted of 264 men and 54 prepubescent boys (≤ 15 years) with the mean age of 23 years (range, 5 to 84 years). The mean follow-up was 52 months (range, 27 to 107 months). Total success rate of posterior urethroplasty was 90%. There were no urethrorectal fistula and perineal wound infection during the follow-up period.

Six o'clock (group A) and 12 o'clock (group B) anterior urethral spatulations were performed in 101 (32%) and 219 (68%) of the patients,

respectively. Baseline demographic and clinical characteristics did not differ significantly between two groups (Table). Posterior urethroplasty success rates were 96% and 87.6% in groups A and B, respectively (*P* = .025).

DISCUSSION

The most common etiologies of strictures or defects of the posterior urethra in Iran are motor vehicle crashes (63%) and falling (10%).⁽¹¹⁾ In pelvic fracture urethral injury, the site of the injury is dependent on the mechanism of fracture, but generally it is at the bulbo-membranous junction.⁽¹²⁾ The gold standard for treatment of pelvic fracture urethral injuries is a bulbo-prostatic anastomotic urethroplasty.⁽³⁾ In our series, flexible cystoscopy was performed to open the true end point of the urethra and for better guidance of scar tissue removal.⁽¹⁰⁾

The principal complication of urethroplasty is recurrence of stricture. In Mundy's study, the rate of recurrence during the first postoperative year was 7% which increased to 12% after 5-year follow-up and remained constant during 10 years.⁽⁵⁾ Spatulation of both ends of the urethra is a procedure to achieve a tension-free mucus-to-mucus anastomosis of at least 32 F lumen and a better successful result. In classic urethroplasty, spatulation site of the distal urethra is located at 6 o'clock position. This technique is generally used by many reconstructive urologists,⁽⁵⁻⁷⁾ however, others spatulate the distal urethra at 12

Demographic and operative data of both 6 o'clock and 12 o'clock urethral spatulations

	Spatulated at 6 o'clock	Spatulated at 12 o'clock	<i>P</i>
Mean age (years)	29.3 ± 14.8	27.9 ± 14	.413
Stricture Length (cm)	3.3 ± 1	3.4 ± 1.3	.488
Cause of Pelvic fracture, n (%)			
Car accident	83 (82.2)	159 (72.6)	.087
Falling down	12 (11.9)	39 (17.8)	.237
Crush injury	6 (5.9)	21 (9.5)	.382
Past surgical history (%)			
Previous Urethrotomy	22 (21.8)	42 (19.2)	.696
Previous Urethroplasty	27 (26.7)	48 (21.9)	.422
Intra-operative procedure, n (%)			
Bulbomembranous Anastomosis	17 (16.8)	59 (26.9)	.067
Bulboprostatic Anastomosis	84 (83.2)	163 (74.4)	.112
Crural Separation	34 (33.6)	60 (27.4)	.312
Inferior Pubectomy	33 (32.7)	51 (23.3)	.102
Success rate, n (%)	97 (96)	192 (87.6)	.025*

*Statically Significant

o'clock. Both techniques are used for posterior urethroplasty in our reconstructive urology section.

In our study, the success rates for 6 o'clock and 12 o'clock spatulations were 96% and 87.6%, respectively ($P = .025$). Morey and McAninch⁽¹³⁾ and Cooperberg and colleagues⁽⁸⁾ have reported the success rates of 93% to 97% by using 6 o'clock spatulation, while Flynn and associates had success rate of 97% by using 12 o'clock spatulation.⁽⁹⁾ The observed difference could be due to that the bulbar urethra is located more posteriorly than corpus spongiosum. Therefore, 6 o'clock spatulation causes less damage to the corpus spongiosum and urethral blood supply. Furthermore, 6 o'clock spatulation decreases the gap between two ends of the urethra, resulting in less tension at the site of end-to-end anastomosis.

CONCLUSION

Our data suggest that the dorsal anterior urethral spatulation in urethroplasty is more efficient than ventral anterior urethral spatulation in terms of treatment success outcome.

ACKNOWLEDGEMENT

The authors are thankful to Infertility and Reproductive Health Research Center, Shahid Beheshti University, MC, for supporting this study.

CONFLICT OF INTEREST

None declared.

REFERENCES

1. Jordan GH, Schlossberg SM. Surgery of the penis and urethra. In: Walsh PC, Retik AB, Vaughan EDJ, et al., eds. *Campbell's Urology*. Vol 4. 8 ed. Philadelphia WB Saunders; 2002:3886-954.
2. Turner-Warwick R. A personal view of the management of traumatic posterior urethral strictures. *Urol Clin North Am*. 1977;4:111-24.
3. Andrich DE, Mundy AR. What is the best technique for urethroplasty? *Eur Urol*. 2008;54:1031-41.
4. Hosseini SJ, Rezaei A, Mohammadhosseini M, Rezaei I, Javanmard B. Supracrural rerouting as a technique for resolution of posterior urethral disruption defects. *Urol J*. 2009;6:204-7.
5. Mundy AR. Urethroplasty for posterior urethral strictures. *Br J Urol*. 1996;78:243-7.
6. Koraitim MM. The lessons of 145 posttraumatic posterior urethral strictures treated in 17 years. *J Urol*. 1995;153:63-6.
7. Koraitim MM. On the art of anastomotic posterior urethroplasty: a 27-year experience. *J Urol*. 2005;173:135-9.
8. Cooperberg MR, McAninch JW, Alsikafi NF, Elliott SP. Urethral reconstruction for traumatic posterior urethral disruption: outcomes of a 25-year experience. *J Urol*. 2007;178:2006-10; discussion 10.
9. Flynn BJ, Delvecchio FC, Webster GD. Perineal repair of pelvic fracture urethral distraction defects: experience in 120 patients during the last 10 years. *J Urol*. 2003;170:1877-80.
10. Hosseini SJ, Kaviani A, Jabbari M, Hosseini MM, Haji-Mohammadmehdi-Arbab A, Simaei NR. Diagnostic application of flexible cystoscope in pelvic fracture urethral distraction defects. *Urol J*. 2006;3:204-7.
11. Hosseini J, Tavakkoli Tabassi K. Surgical repair of posterior urethral defects: review of literature and presentation of experiences. *Urol J*. 2008;5:215-22.
12. Andrich DE, Day AC, Mundy AR. Proposed mechanisms of lower urinary tract injury in fractures of the pelvic ring. *BJU Int*. 2007;100:567-73.
13. Morey AF, McAninch JW. Reconstruction of posterior urethral disruption injuries: outcome analysis in 82 patients. *J Urol*. 1997;157:506-10.