

Scrotum-like protrusion of lipoma arising from the proximal thigh

– Report of two cases –

Koshi Hattori,¹ Masahito Hatori,¹ Mika Watanabe,² Toshihisa Osanai,³
Shoichi Kokubun¹

*Department of Orthopaedic Surgery, Tohoku University School of Medicine,¹
Department of Pathology, Tohoku University Hospital,² Department of
Orthopaedic Surgery, Yamagata University School of Medicine³*

ABSTRACT

*A free full-text copy of this article can be found at the web page of Upsala J Med Sci:
<http://www.ujms.se>*

We report two cases of large lipomas arising from the proximal thigh with an extremely uncommon shape. The tumors were elastic soft and movable. MRI examination revealed both tumors with high signal intensity as fatty tissue on both T1 and T2-weighted images. Needle biopsy of the specimens revealed lipoma. Marginal excision was carried out for both cases because of the patients' discomfort. No recurrence was found three and five years after surgery, respectively.

INTRODUCTION

Lipoma is a benign tumor composed of mature white adipocytes and is the most common soft tissue mesenchymal neoplasm in adults (1). We report two cases of lipoma arising from the proximal thigh with an extremely uncommon shape, i.e. a scrotum-like protrusion.

[Case 1]

A 45-year-old male presented with a tumor protruding from his proximal thigh. The tumor had been increasing in size and the skin showed erosion from rubbing against the leg and cloth. In 1997, he first noticed a quail-egg-sized subcutaneous tumor. Two years later, it had become pendulous and was covered with intact skin. In 2001, it became as large as a fist, and the erosion appeared. He visited a local clinic and was then referred to our hospital. Needle biopsy specimen revealed lipoma.

Received 11 May 2004
Accepted 3 June 2004

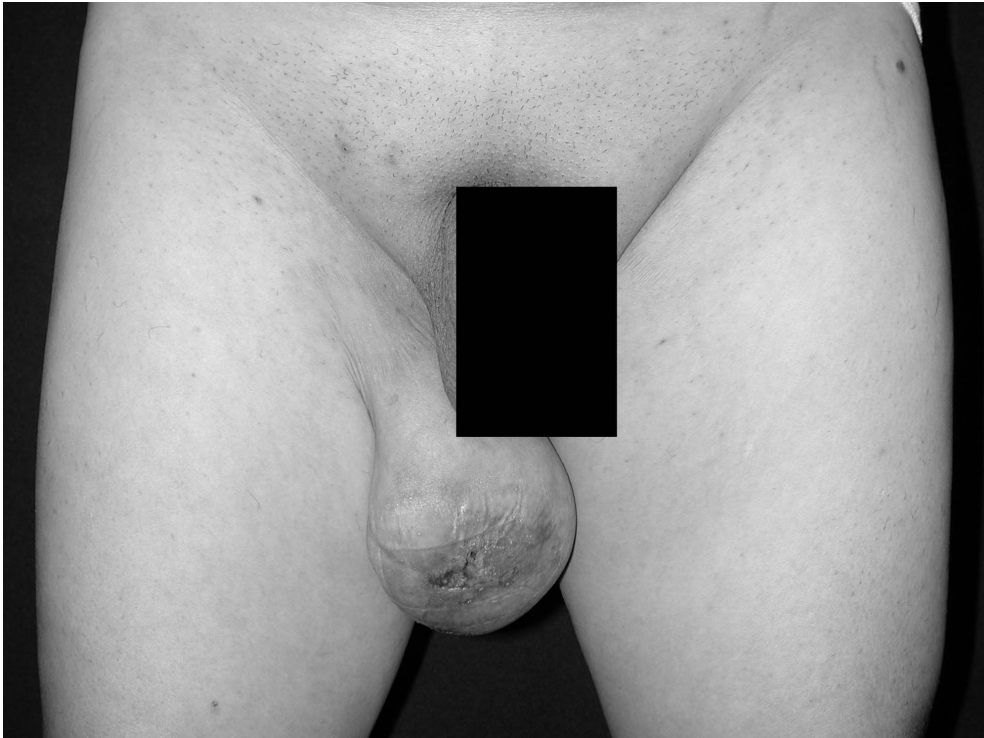


Fig. 1. Macro photograph showing a mass protruding from the medial side of the right proximal thigh.

Physical examination: The tumor was 10×9cm large, protruding from the medial side of the right proximal thigh (Fig.1). It was elastic soft, movable against both the subcutaneous and deep tissue. There was skin erosion on the distal end of the tumor. The elastic hard portion was palpable deep inside. Plain radiographs showed swelling of the soft tissue. The mass showed iso-density to subcutaneous fatty tissue on CT scan. No calcification was seen inside. Some septum-like structure was observed. On MRI, the tumor had high signal intensity as adipose tissue on both T1 and T2-weighted images. An irregular septum was seen in the center and distal part of the mass, showing the effect of fat suppression. The peripheral portion and septum were enhanced with the injection of gadolinium compound (Fig.2). Although the tumor was benign, its growth obviously impaired the patient's quality of life. Marginal excision was performed. Microscopically, the tumor consisted of large, mature adipose cells separated by fibrous tissue. No nuclear deformity nor lipoblasts were found (Fig.3). In the center of the distal half, necrotic adipose tissue was observed. There were no findings suggesting malignancy. The diagnosis was lipoma with degenerative necrosis. The patient had no local recurrence during the three years after surgery.

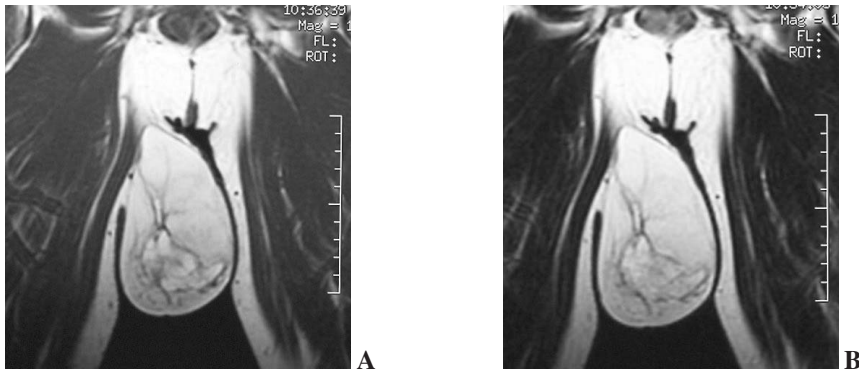


Fig. 2. MRI showing a mass with high signal intensities as adipose tissue and irregular septum in the center and distal part of the mass on both T1 (A) and T2-(B) weighted images.

[Case2]

A 50-year-old male visited our clinic because of a subcutaneous tumor protruding and hanging from his proximal thigh. The patient himself noticed the tumor about 20 years previously. The tumor was rice-grain-sized initially and had enlarged gradually. For two years the enlarged tumor had caused annoyance.

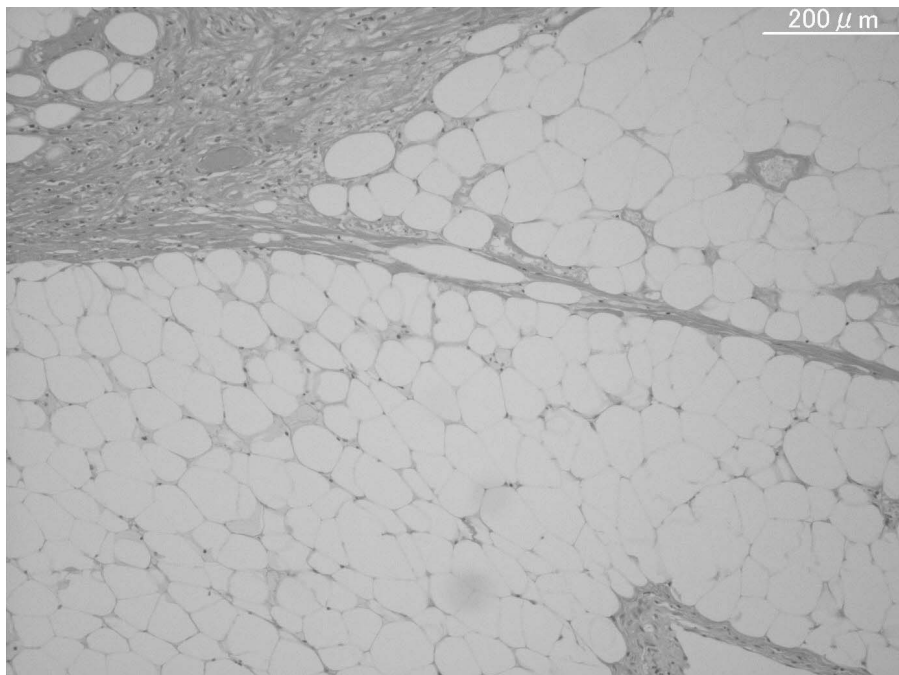


Fig. 3. Microphotograph showing a tumor consisting of large, mature adipose cells separated by fibrous tissues.

Physical examination: The tumor was 12×8cm large, protruding from the medial side of the right proximal thigh. It was elastic soft, and movable against both the subcutaneous and deep tissue. Superficial vein dilatation was observed. The tumor revealed neither heat nor tenderness.

Plain radiographs showed soft tissue swelling. The mass showed iso-density to subcutaneous fatty tissue on CT scan. No calcification was seen inside. No septum-like structure was found. MRI examination revealed the tumor with high signal intensity as fatty tissue in the subcutaneous tissues on both T1 and T2-weighted images. The MRI findings were similar to those seen in the first case, although no irregular septum was present. Histological examination of the specimen taken with needle biopsy revealed lipoma. The tumor was removed in April 1999 because of the patient's discomfort. Microscopically, the tumor consisted of large mature adipose cells, mostly non-nucleated. No lipoblast was found. The diagnosis was lipoma with degenerative necrosis. No distinct recurrence was detected during the five years after surgery.

DISCUSSION

Most lipomas arise and grow in the subcutaneous region. To the best of our knowledge, there has been no report of a protruding lipoma like the present cases. Though they were large, and looked heterogeneous in MRI (case 1), pathological examination showed no evidence of malignancy (5, 6, 7, 8, 9). The following diseases should be considered in the differential diagnosis based on the tumor location and/or radiological findings: well-differentiated liposarcoma, accessory scrotum, inguinal herniation. Well-differentiated liposarcoma would show marked variation in the adipocytic size, atypical cells, and a number of lipoblasts (1). In the present cases, the tumor had large, mature adipose cells separated by fibrous tissue. Neither nuclear deformity nor lipoblasts were found. Accessory scrotum is a type of congenital lipoma, found in the perineal region of newborns (2, 3, 4). It was ruled out because of the advanced ages of the patients. Inguinal herniation would occur on the inguinal band, and is easily ruled out by MRI.

There may be two reasons for the very unusual shape of the tumors, i.e. they arose in an area of thin and weak subcutaneous tissue, or, the subcutaneous tissue became weak along with the growth of the tumor. Central necrosis usually suggests malignancy. In the present case, malnutrition due to overgrowth and stalk torsion could account for the necrotic change in the center of distal part of the tumor (case 1) and the non-nucleated cells (case 2). No recurrence was seen after marginal resection.

REFERENCES

1. Fletcher CDM, Unni KK, Mertens F (Eds); (2002). World Health Organization Classification of Tumours. Pathology and Genetics of Tumours of Soft Tissue and Bone. IARC Press: Lyon
2. Morita T. (1991). Congenital Perineal Lipoma with Accessory Scrotum: a Case Report. *Acta Urol Jpn* 37:647-649.

3. Konya E. (1996). Accessory Scrotum with Lipoma: a Case Report. *Acta Urol Jpn* 42:233–236.
4. Budhiraja S. (1999). Accessory Scrotum. *Urol Int* :63:210–211.
5. Gaskin CM, Helms CA. (2004). Lipomas, lipoma variants, and well-differentiated liposarcomas (atypical lipomas): results of MRI evaluations of 126 consecutive Fatty masses. *AJR Am J Roentgenol* 182:733–9.
6. Ohguri T, Aoki T, Hisaoka M, Watanabe H, Nakamura K, Hashimoto H, Nakamura T, Nakata H. (2003). Differential diagnosis of benign peripheral lipoma from well-differentiated liposarcoma on MR imaging: is comparison of margins and internal characteristics useful? *AJR Am J Roentgenol* 180: 1689–94.
7. Galant J, Marti-Bonmati L, Saez F, Soler R, Alcala-Santaella R, Navarro M. (2003). The value of fat-suppressed T2 or STIR sequences in distinguishing lipoma from well-differentiated liposarcoma. *Eur Radiol* 13: 337–43.
8. Kransdorf MJ, Bancroft LW, Peterson JJ, Murphey MD, Foster WC, Temple HT. (2002). Imaging of fatty tumors: distinction of lipoma and well-differentiated liposarcoma. *Radiology* 224:99–104.
9. Matsumoto K, Takada M, Okabe H, Ishizawa M. (2000). Foci of signal intensities different from fat in well-differentiated liposarcoma and lipoma: correlation between MR and histological findings. *Clin Imaging* 24:38–43.

Corresponding author: Masahito Hatori, M.D.

Department of Orthopaedic Surgery, Tohoku University School of Medicine
1-1 Seiryomachi, Aobaku, Sendai, Japan 980-8574
Tel: +81-22-717-7242, Fax: +81-22-717-7248
mhato@mail.tains.tohoku.ac.jp