

Peripheral Embolization of Separated Angiographic Catheter

B. Almgren¹ and A. Hemmingsson²

Departments of Surgery¹ and Diagnostic Radiology², University Hospital, Uppsala, Sweden

ABSTRACT

A complication of separation of an angiographic catheter is described. Contributing factors and preventive measures are discussed.

INTRODUCTION

Catheter separation is an extremely rare complication of angiography. An incidence of 0.0008 per cent has been reported (3), but also a higher of 2 per cent, when angiography has been performed through synthetic vascular grafts (2). In all previously reported cases the broken end of the catheter has remained attached to the vessel or graft wall at the catheter entry site and in no case peripheral embolization has occurred. We here report a case unique in that the separated fragment embolized to the peroneal artery via bypass graft.

CASE REPORT

A 35-year old man had undergone a femorotibial bypass with autogenous saphenous vein graft of the right leg because of arteriosclerosis 21 months before this admission. Angiography was now requested because of recurrent rest pain and ulceration of the great toe.

Angiography was performed using a polyethene catheter, i.d. 1.58 mm, o.d. 2.08 mm (Radicath^R) with 4 sideholes after puncture of the right common femoral artery. No difficulties were encountered during the insertion or the study. During withdrawal following completion of arteriography the catheter became fixed at the puncture site and resisted further removal. A guide wire was reinserted to release the fixation and the catheter was gently pulled. During this manipulation the catheter separated at the level of the first sidehole, leaving approximately 2 cm of the catheter in the common femoral artery. This was confirmed by fluoroscopy. The fragment was then carried by the blood stream along the bypass graft down into the peroneal artery, which was the only patent artery of the lower leg. A radiograph demonstrated the fragment in the middle part of the artery just proximal to an occlusion (Fig 1). The artery was surgic-

ally explored and the catheter tip removed. The patient recovered without complication.

DISCUSSION

Our case demonstrates that peripheral embolization of a catheter fragment is a possible complication of catheter separation during angiography. Since embolization did not occur in any of the six described cases of catheter separation (1,2,4,5,6), some preventive factors must exist. In those cases the broken segments were 5 cm up to 28 cm in length, compared to 2 cm in our case, and remained fixed at the catheter entry site.

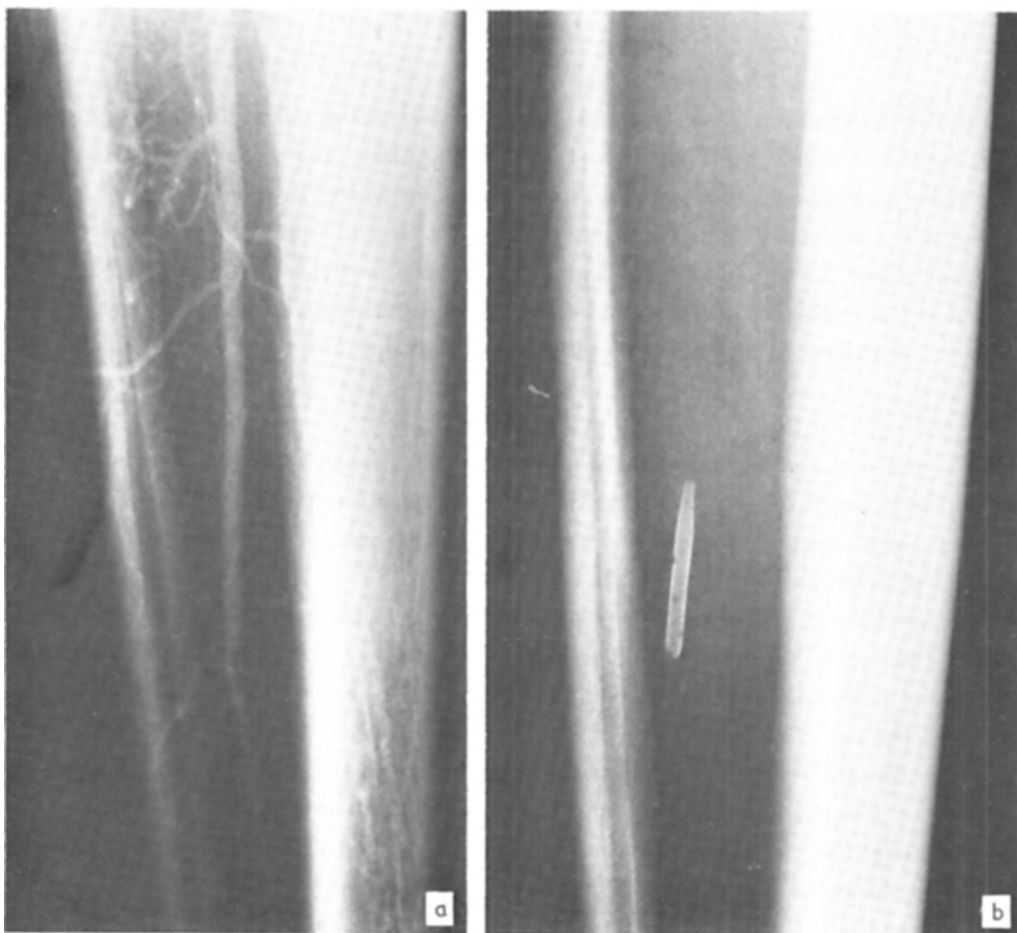


Fig. 1. Arteriography of right lower leg (a). Separated catheter tip in the peroneal artery just proximal to an occlusion (b).

Surgical removal of the separated fragment was necessary in our case, as in all other cases, but one (4), which indicates that catheter separation is a rather serious complication of angiography.

We will not repeat the adequate discussions of the previous reports of catheter separation, but only point out some salient features, common to all cases. Catheter separation has occurred exclusively during withdrawal, both from synthetic vascular grafts and the patient's native vessel. Regardless of graft or vessel, induration and fibrosis have existed at the catheter entry sites. In most cases polyethylene catheters, which are soft, pliable and easily stretched, have been used. The risk of fixation to a rough edge is greater with a catheter with sideholes than with an endhole.

The awareness of these potentially provoking, but not inevitable factors in addition to recommended precautions during catheter withdrawal should minimize the risk of catheter separation and consequently peripheral embolization of broken fragments.

REFERENCES

1. Feigenbaum, L. & Grollman, J.H.: Catheter separation in aortofemoral grafts despite wire protection. *Am J Roentgenol* 134:581-582, 1980.
2. Mani, R.L. & Costin, B.S.: Catheter angiography through aortofemoral grafts: prevention of catheter separation during withdrawal. *Am J Roentgenol* 128: 328-329, 1977.
3. Ravin, C.E. & Koehler, P.R.: Reuse of disposable catheters and guide wires. *Radiology* 122:577-579, 1977.
4. Soo, C.S., Chuang, V.P. & Wallace, S.: Nonsurgical retrieval of a severed catheter from femoral artery using a mylar sheath. *Am J Roentgenol* 135: 400-401, 1980.
5. Weinshelbaum, A. & Carson, S.N.: Separation of angiographic catheter during arteriography through vascular graft. *Am J Roentgenol* 134:583-584, 1980.
6. Zablow, B.C., Gordon, D.H. & Martin, E.C.: Separation to a femoral artery catheter during withdrawal. *Radiology* 133:244-245, 1979.

Received February 20, 1982

Address for reprints:

Bo Almgren, M.D.
Department of Surgery
University Hospital
S-750 14 Uppsala
Sweden