

Nostril mass caused by *Leishmania* spp. in a dog

Manuela Gizzarelli^{1*}, Valentina Foglia Manzillo¹, Eleonora Fiorentino², Aldo Scalone² and Gaetano Oliva¹

¹ Department of Veterinary Medicine and Animal Production, University of Naples Federico II, 80137 Napoli, Italy.

² Unit of Vector-borne Diseases and International Health, MIPI Department, Istituto Superiore di Sanità, Rome, Italy.

*Corresponding author at: Department of Veterinary Medicine and Animal Production, University of Naples Federico II, 80137 Napoli, Italy. gaetano.oliva@unina.it

Veterinaria Italiana 2018, **54** (3), xxx-xxx. doi: 10.12834/VetIt.1460.7898.1
Accepted: 19.02.2018 | Available on line: 30.09.2018

Keywords

Allopurinol,
Atypical lesion,
Canine leishmaniasis,
Miltefosine,
Mucosal localization,
Nostril.

Summary

Canine leishmaniasis (CanL) is a systemic zoonotic disease caused by the protozoan *Leishmania*, an intracellular macrophage parasite, transmitted by the bite of phlebotomine sandflies. In dogs, the clinical disease is mostly characterised by symptoms associated with viscerocutaneous lesions such as lymphadenopathy, splenomegaly, skin lesions, and renal and ocular disease caused by the deposition of immune complexes. The parasite may provoke mucosal lesions which cause atypical clinical signs. The aim of this study is to describe an atypical nostril mass in a dog infected by *Leishmania*. Clinical examination did not show any systemic clinical signs, while haematological, biochemical, and urinary parameters demonstrated a mild disease stage. Diagnosis was confirmed through the isolation of cultured live parasites by biopsy. The dog was treated with a combination of miltefosine and allopurinol, showing full remission of clinical symptoms after 2 months. The authors outline the importance of considering CanL in the differential diagnosis of mucous and tumour-like lesions.

Lesione atipica nasale causata da *Leishmania* spp. in un cane

Parole chiave

Allopurinolo,
Leishmaniosi canina,
Lesione atipica,
Localizzazione mucosale,
Miltefosina,
Narice.

Riassunto

La leishmaniosi canina è una malattia zoonotica sistemica causata da un parassita intracellulare dei macrofagi, il protozoo *Leishmania*, trasmesso dalla puntura di flebotomi vettori. Nei cani l'infezione è caratterizzata dalla diffusione viscerale e cutanea del parassita; essa causa linfadenopatia, splenomegalia, lesioni cutanee, danni renali, oculari ed articolari, determinati dalla deposizione di immunocomplessi. Il parassita può essere riscontrato raramente in sedi atipiche, con coinvolgimento delle mucose. L'obiettivo del presente lavoro è descrivere un caso atipico di leishmaniosi, caratterizzato dalla presenza di una massa nasale non associata ad evidente coinvolgimento sistemico. La diagnosi definitiva è stata confermata isolando dalla lesione promastigosti con esame colturale del tessuto biotico. Il cane, trattato con un'associazione di miltefosina e allopurinolo, ha presentato piena remissione della sintomatologia a due mesi. Si sottolinea l'importanza di considerare la leishmaniosi canina nella diagnosi differenziale di lesioni mucosali e simil-tumorali.

Introduction

Leishmania is an intracellular parasite found in mammalian macrophages and transmitted by phlebotomine sandflies of the genus *Phlebotomus* (Old World) and *Lutzomyia* (New World). It is a heteroxenous parasite and needs 2 hosts to develop. On the vertebrate side, the principal *Leishmania* hosts are dogs and other members of the *Canidae* family (foxes, jackals, wolves). In Italy, *Phlebotomus perniciosus* is considered the main species

responsible for the spread of the *Leishmania* infection (Bongiorno *et al.* 2003). Canine leishmaniasis (CanL) is endemic in the Mediterranean basin, Asia, and Latin America, but is also reported in a rising number of cases from non-endemic countries due to the travel and import of animals as pets (Gramiccia & Gradoni 2005, Metter *et al.* 2005). In Italy, CanL has been observed for a long time in southern, central, and insular regions (Paradies *et al.* 2006). Recent evidence shows that CanL is expanding into north-western Italy, into areas with a continental

climate, far away from the recognised endemic areas along the Mediterranean coast (Ferroglia *et al.* 2005). Parasite transmission occurs through the bite of an infected phlebotomine sandfly, although secondary modes of transmission (e.g. via blood transfusion and congenital transmission) have also been suggested (Gaskin *et al.* 2002, Owens *et al.* 2001). Clinically, CanL is characterised by chronic viscerocutaneous signs, such as lymphadenopathy, skin lesions (symmetrical alopecia, furfuraceous dermatitis, ulcers, and nodular lesions) (Ciarabella *et al.* 1997), keratoconjunctivitis, epistaxis, and diarrhoea (Longstaffe & Guy 1985). In atypical cases, the parasites can also be found in striated muscle, central nervous system, and endocrine glands or gonads, with or without functional damage (Cortese *et al.* 1999). Mucosal localizations are rarely described in dogs (Aliaga *et al.* 2003, Foglia Manzillo *et al.* 2005, Foglia Manzillo *et al.* 2009, Font *et al.* 1996, Lamothe & Poujade 2002, Pinna Parpaglia *et al.* 2007, Viegas *et al.* 2012).

The aim of this study is to describe an atypical case of *Leishmania* infection in a dog showing a diffuse nostril mucosal involvement, which was successfully treated with miltefosine and allopurinol.

Case report

An English Setter, 7 year old, female, was referred to the Veterinary Hospital of Veterinary Medicine Faculty of Naples for the appearance of unilateral mucous nasal discharge, followed by the evidence of a mass. Lesions didn't respond to antibiotic treatment (amoxicillin/clavulanic acid combination, 15 mg/kg BID x 15 days). Symptoms had been present for 2 previous months.

History revealed that the dog lived outdoor, in Campania Region, South Italy. This area is considered highly endemic to CanL. The dog was fed with commercial food and was submitted

to periodic core vaccinations and anti-parasitic treatments. Two years before the dog resulted positive to an anti-*Leishmania* test (IFAT) with a value of 1:160. No clinical signs or urinary and biochemical alterations were present, therefore the dog was not treated for CanL.

Clinical examination showed no relevant clinical signs. Mild lymphadenomegaly was the only clinical finding.

An examination of the nasal region revealed the presence of ulceration at the nasal muco-cutaneous margin as well as a nostril mucosal hypertrophy that deformed the nasal profile (Figure 1).

Haematological, biochemical, and urinary analysis revealed several clinicopathological alterations: mild non-regenerative anaemia, increasing of urea, alanine aminotransferase (ALT), and total protein values; albumin/globulin ratio inversion, proteinuria and abnormal value of urinary protein-creatinine (UPC) ratio (Table I, Table II). Differential diagnosis included nasal tumor, systemic fungal infection, and foreign bodies. Because of the particular anatomic localization, the previous history of the dog, and the presence of clinicopathological alterations such as proteinuria, CanL was considered in the differential plan along with other possible granulomatous lesions.

The nasal mass was first examined using brushing cytology. This revealed the moderate presence of inflammatory cells, no amastigotes of *Leishmania*, nor fungal hyphae. The dog was submitted to anaesthesia (Methadone 0.2 mg/kg, Propofol 4-6 mg/kg, Isoflurane) in order to perform a tomographic examination of the nasal structures and surgical biopsy of the lesion. An anti-*Leishmania* specific serological test (IFAT) was also performed together with popliteal lymph nodes and sternal bone marrow aspiration. A *Leishmania* culture of bioptic tissue was carried out using a modified Tobie-Evans medium.



Figure 1. Nostril mass (arrow) that deformed the nasal profile.

Table I. Haematological parameters.

Parameter	Value	Normal range
WBC	10.400 mm ³	6.000-12.000 mm ³
PLT	430.000 mm ³	175.000-400.000 mm ³
RBC	5.340.000 mm ³	5.000.000-8.000.000 mm ³
HGB	12.9 g/dL	16-18 g/dL
HCT	33.9 %	35-50%
MCV	64 fL	65-75 fL
MCH	24.2 pg	19-24 pg
MCHC	38.1 g/dL	32.0-38.0 g/dL

WBC= white blood cells; PLT= platelets; RBC = red blood cells; HGB = haemoglobin; HCT = haematocrit; MCV = mean corpuscular value; MCH = mean corpuscular haemoglobin; MCHC = mean corpuscular haemoglobin concentration.

Table II. Biochemical and urinary parameters.

Parameter	Value	Normal range
CREA	1.06 mg/dL	< 1.8 mg/dL
BUN	28.2 mg/dL	7-20 mg/dL
GLU	104 mg/dL	60-100 mg/dL
ALT	136 UI/L	10-47 UI/L
TP	7.9 g/dL	6-7.8 g/dL
A/G ratio	0.5	0.6-1.1
Proteinuria	500 mg/dL	-
UPC ratio	0.9	< 0.5

CREA = creatinine; BUN = blood urea nitrogen; GLU = glucose; ALT = alanine aminotransferase; TP = total protein; A/G ratio = albumin/globulin ratio; UPC ratio = urine protein to creatinine ratio.

IFAT was found positive at 1:2560, while lymph node and bone marrow aspirates were negative to microscopic examination. After 2 weeks, the culture resulted positive for the growth of *Leishmania* promastigotes.

A histopathological examination of the nasal mucosa revealed the presence of diffuse and severe cells proliferation. These had infiltrated the connective bundles, disrupting their architecture, and reached the deeper muscle planes. Cellular proliferation consisted of numerous macrophages, lymphocytes, and plasma cells (Figure 2); very rare *Leishmania* amastigotes were detected at high magnification. Tomography confirmed that there was no involvement of nasal bone structures.

The dog was treated with specific anti-*Leishmania* therapy: miltefosine at a dose of 2 mg/kg of body weight, orally, once a day for 28 days, and allopurinol at 10 mg/kg, orally, twice a day for 6 months. The dog was also treated with enalapril at a dose of 0.5 mg/kg of body weight and specific renal diet. Side-effects of the drugs were limited to 3 episodes of vomiting that

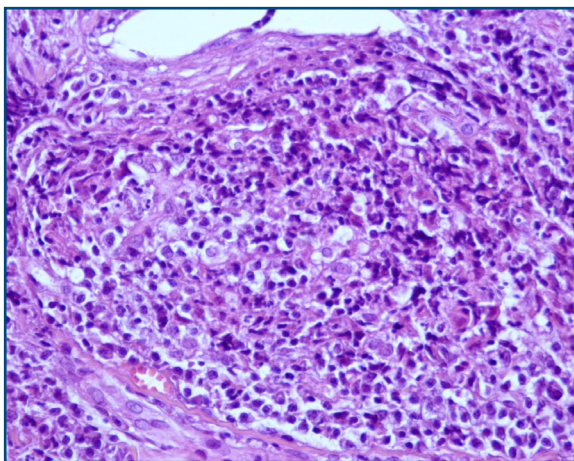


Figure 2. Dog: Nostril mass. Cellular proliferation, due to several macrophages, lymphocytes, and plasma cells (haematoxylin-eosin 40X).

were attributed to the administration of miltefosine.

After 2 months, the nostril lesions were completely resolved. This was confirmed at 1-year follow-up (Figure 3).

Anti-*Leishmania* IFAT titers, evaluated 1 year after treatment, showed a reduction to 1:320.

Discussion

CanL is usually characterized by viscerocutaneous clinical signs; the mucosal localization showed in this case study is rare and mostly described in humans as a result of infection in immune depressed patients (Aliaga et al. 2003). In dogs infected by *Leishmania infantum*, the presence of mucosal lesions is not often described (Aliaga et al. 2003, Foglia Manzillo et al. 2005, Foglia Manzillo et al. 2009, Font et al. 1996, Lamothe & Poujade 2002, Pinna Parpaglia et al. 2007, Viegas et al. 2012), and its pathogenic origin is not fully clear. In this study, we did not identify the *Leishmania* species involved, however we presumed the species was *Leishmania infantum* because it is the only species actually reported in Italy and the dog had no history of travel outside the country. Based on these findings, our main hypotheses are similar to those considered for humans in which the mucosal lesions caused by *L. infantum* have been attributed to the immune suppression of the host or to the parasite tropism associated to an aberrant local tissue response after sand fly inoculation. The dog described in this study didn't show typical




Figure 3. Nasal region examination after treatment.

clinical symptoms associated with CanL, except for a mild enlargement of the popliteal lymph nodes. However haematological, biochemical, and urinary data revealed mild anaemia, and liver and kidney involvement. During *Leishmania* infection these findings are caused by a systemic inflammatory response and immune complexes deposition that is evidenced by the serum total protein increase and A/G ratio inversion. Specific tests for *Leishmania* showed very high antibody titres (IFAT 1:2560), which allowed us to classify the clinical condition of the dog as Stage II (moderate disease) substage b, according to the Leishvet group classification (Solano-Gallego *et al.* 2009). In this particular case however, the visceralization of the parasite was not evident because of the negative results of direct parasitological investigations (lymph nodes and bone marrow aspirates). In addition, the good general condition of the dog seems rule out that the nostril lesion represents the result of an intense immune suppression. Instead, 2 other different

hypotheses could be considered: i) An intense local reaction at the parasite inoculation site due to possible repetitive bites during sandfly season. This hypothesis has also been considered in other studies (Foglia Manzillo *et al.* 2005, Viegas *et al.* 2012); ii) a rapid progression of the first infection assessed 2 years before, with an atypical diffusion of the parasite with mucosal involvement (Foglia Manzillo *et al.* 2005, Foglia Manzillo *et al.* 2009, Lamothe & Poujade 2002, Pinna Parpaglia *et al.* 2007, Viegas *et al.* 2012).

The therapeutic efficacy of the combination of miltefosine with allopurinol, as it has been described previously in other mucosal involvement (Foglia Manzillo *et al.* 2009), confirmed that this protocol could be considered as a first-line approach when mucosal lesions are evident in CanL. Our case re-confirmed that every atypical lesion could be caused by *Leishmania* infection and that this type of infection should always be considered in differential diagnosis of mucosal and tumour-like lesions.

References

- Aliaga L., Cobo F., Mediavilla J.D., Bravo J., Osuna A., Amador J.M., Martin-Sanchez J., Cxorsero E. & Navarro J.M. 2003. Localized mucosal leishmaniasis due to *Leishmania infantum*: clinical and microbiologic findings in 31 patients. *Medicine*, **82**,147-158.
- Bongiorno G., Habluetzel A., Houry C. & Maroli M. 2003. Host reference of phlebotomine sand flies at a hypodermic focus of canine leishmaniosis in central Italy. *Acta Trop*, **88**,109-116.
- Ciaramella P., Oliva G., De Luna R., Gradoni L., Ambrosio R., Cortese L., Scalone A. & Persechino A. 1997. A retrospective clinical study of canine leishmaniasis in 150 dogs naturally infected by *Leishmania infantum*. *Vet Rec*, **141**, 539-543.
- Cortese L., Oliva G., Restucci B., Ciaramella P. & Persechino A. 1999. Primary hypothyroidism associated with leishmaniasis in a dog. *J Am Anim Hosp Assoc*, **35**, 487-492.
- Ferroglio E., Maroli M., Gastaldo S., Mignone W. & Rossi L. 2005. Canine leishmaniasis, Italy. *Emerg Infect Dis*, **11**, 1618-1629.
- Foglia Manzillo V., Pagano A., Paciello O., Di Muccio T., Gradoni L. & Oliva G. 2005. Papular-like glossitis in a dog with leishmaniosis. *Vet Rec*, **156**, 213-215.
- Foglia Manzillo V., Paparcone R., Cappiello S., De Santo R., Bianciardi P. & Oliva G. 2009. Resolution of tongue lesions caused by *Leishmania infantum* in a dog treated with the association miltefosine-allopurinol. *Parasit Vectors*, **2** (Suppl 1), S6.
- Font A., Roura X., Fondevila D., Closa J., Mascort J. & Ferrer L. 1996. Canine mucosal leishmaniasis. *J Am Anim Hosp Assoc*, **32**,131-137.
- Gaskin A.A., Schantz P., Jackson J., Birkenheuer A., Tomlinson L., Gramiccia M., Levy M., Steurer F., Kollmar E., Hegarty B.C., Ahn A. & Breitschwerdt E.B. 2002. Visceral leishmaniasis in a New York foxhound kennel. *J Vet Intern Med*, **16**, 34-44.
- Gramiccia M. & Gradoni L. 2005. The current status of zoonotic leishmaniasis and approaches to disease control. *Int J Parasitol*, **35**, 1169-1180.
- Lamothe J. & Poujade A. 2002. Ulcerative glossitis in a dog with leishmaniasis. *Vet Rec*, **151**, 182-183.
- Longstaffe J.A. & Guy M.W. 1985. Leishmaniasis in dogs. *Vet Ann*, **25**, 358-367.
- Mettler M., Grimm F., Naucke T.J., Maasjost C. & Deplazes P. 2005. Canine leishmaniosis in Central Europe: retrospective survey and serological study of imported and travelling dogs. *Berl Munch Tierarztl Wochenschr*, **118**, 37-44.
- Owens S.D., Oakley D.A., Marrayott K., Hatchett W., Walton R., Nolan T.J., Newton A., Steurer F., Schantz P. & Giger U. 2001. Transmission of visceral leishmaniasis through blood transfusions from infected English foxhounds to anemic dogs. *J Am Vet Med Assoc*, **219**, 912-921.
- Paradies P., Capelli G., Cafarchia C., De Caprariis D., Sasanelli M. & Otranto D. 2006. Incidences of canine leishmaniasis in an endemic area of southern Italy. *J Vet Med B*, **53**, 295-298.
- Pinna Parpaglia M.L., Vercelli A., Cocco R., Zobba R. & Manunta M.L. 2007. Nodular lesions of the tongue in canine leishmaniosis. *J Vet Med A*, **54**, 414-417.
- Solano-Gallego L., Koutinas A., Miró G., Cardoso L., Pennisi M.G., Ferrer L., Bourdeau P., Oliva G. & Baneth G. 2009. Directions for the diagnosis, clinical staging, treatment and prevention of canine leishmaniosis. *Vet Parasitol*, **165**, 1-18.
- Viegas C., Requicha J., Albuquerque C., Sargo T., Machado J., Dias I., Pires M.A., Campino L. & Cardoso L. 2012. Tongue nodules in canine leishmaniosis-a case report. *Parasit Vectors*, **5**, 120.