

Etiology and pathophysiology of varicose vein recurrence at the saphenofemoral or saphenopopliteal junction: an update

Marianne De Maeseneer,^{1,2}
Attilio Cavezzi³

¹Phlebology, Department of Dermatology, Erasmus Medical Centre, Rotterdam, the Netherlands; ²Faculty of Medicine and Health Sciences, University of Antwerp, Antwerp, Belgium; ³Vascular Unit, Clinica Stella Maris and Poliambulatorio Hippocrates, San Benedetto del Tronto, Italy

Abstract

Recurrent varicose veins remain a common problem after varicose vein treatment. With the widespread use of duplex ultrasound and increasing experience in the field of ultrasound-guided procedures, the impact of both tactical and technical failure is likely to diminish. Progression of the disease and neovascularization, in particular after surgery at the level of the saphenofemoral junction (SFJ) or saphenopopliteal junction (SPJ), both have their impact on recurrence, and both factors may be interacting. After high ligation, with or without stripping, neovascularization has been attributed to local angiogenesis, transnodal lymphovenous connections, dilation of vasa vasorum, or disturbed venous drainage of the ligated tributaries of the SFJ. Another typical source of recurrence after surgery is a persistent refluxing residual stump at the SFJ or SPJ. After endovenous thermal ablation new or persistent reflux may be detected sonographically at the SFJ or SPJ residual stump as well. One of the veins often involved in recurrence after great saphenous vein ablation is the anterior accessory saphenous vein. Future studies are needed, including adequate preoperative duplex ultrasound investigation and long-term follow-up, to understand the impact of residual or recurrent reflux at the SFJ or SPJ on the incidence of clinical recurrence after different forms of varicose vein treatment.

Introduction

Recurrent varicose veins, re-appearing in the short- or long-term after previous treatment, are a common problem (Figures 1 and 2). After surgery, according to prospective

studies with 5 years follow-up, the incidence of clinical recurrence is estimated to be between 25% and 50%.^{1,2} After endovenous thermal ablation (EVTA) the majority of studies report about a shorter follow-up time. Often only surrogate outcomes (obliteration of the truncal vein or not, according to duplex ultrasound) have been used without mentioning the incidence of clinical varicose vein recurrence. Long-term clinical follow-up data after EVTA are scarce up to now. After treatment of the great saphenous vein (GSV) with the old radiofrequency system Closure Plus®, Merchant *et al.*³ reported an incidence of 27% of varicose vein recurrence after 5 years. Pröbstle *et al.*⁴ noticed the presence of varicose veins after 3 years in 33% of limbs, treated with radiofrequency powered segmental ablation (Closure Fast®, Covidien plc, Dublin Ireland). Recently, the 5-years results of a randomized controlled trial (RCT), comparing endovenous laser ablation with and without additional high ligation at the saphenofemoral junction (SFJ) in patients with bilateral symptomatic GSV incompetence, have been reported by Disselhof *et al.*⁵ They did not perform additional phlebectomies but ultrasound guided foam sclerotherapy for residual varicose veins at 6 weeks. After five years, recurrent varicose veins were present in 31% of limbs treated with endovenous laser ablation without SFJ ligation and in 49% of those treated with additional high ligation. In a RCT comparing endovenous laser treatment with surgery, with additional phlebectomies in both groups, Rasmussen *et al.*⁶ found an incidence of recurrent varicose veins in respectively 26% and 37% of patients after two years. At the Charing Cross meeting of 2012, Gough reported 33% clinical recurrence in 63 patients at 6.5 years of follow-up after endovenous laser ablation.⁷ The above cited mid- and long-term follow-up data illustrate that not only after high ligation and stripping but also after endovenous treatment of the refluxing trunk the clinical reappearance of varicose veins definitely remains a problem.

Etiology of varicose vein recurrence

Some causes of recurrence of varicose veins after treatment are obvious: insufficient understanding of venous anatomy and haemodynamics, inadequate preoperative assessment (both leading to *tactical failure*), and incorrect or insufficient surgical/endovenous intervention (which means *technical failure*). With the widespread use of duplex ultrasound for evaluation of patients with varicose veins and increasing experience of surgeons and other physicians treating varicose veins, fortu-

Correspondence: Marianne De Maeseneer, Department of Dermatology, Erasmus Medical Centre, PB 2040, 3000 CA Rotterdam, the Netherlands.
E-mail: marianne.demaeseneer@ua.ac.be
m.demaeseneer@erasmusmc.nl

Key words: varicose vein, phenofemoral junction, saphenopopliteal junction.

Acknowledgments: the authors would like to thank Dr Olivier Pichot, Grenoble, France for providing illustrative duplex ultrasound images for Figures 3, 5 and 6.

Received for publication: 18 June 2012.
Revision received: 20 June 2012.
Accepted for publication: 21 June 2012.

This work is licensed under a Creative Commons Attribution 3.0 License (by-nc 3.0).

©Copyright M. De Maeseneer and A. Cavezzi, 2012
Licensee PAGEPress, Italy
Veins and Lymphatics 2012; 1:e4
doi:10.4081/1.2012.e4

nately the impact of both tactical and technical failure is likely to diminish nowadays.

There are two other main causes for varicose vein recurrence left, namely *progression of the disease* and *neovascularization*. Progression of the disease, with new varicose veins appearing over time is somehow *part of the game*, as superficial venous disease is a chronic condition in which hereditary and constitutional risk factors play a role. Over time, new superficial veins may become incompetent, segmental truncal reflux may extend, new incompetence of perforating veins may develop and also pelvic vein insufficiency may play its role in progression of the disease. The term *neovascularization* describes a phenomenon of formation of new, usually tortuous, venous channels between the saphenous stump on the common femoral vein (CFV) and a residual GSV, anterior accessory saphenous vein (AASV) or superficial tributaries (Figure 3).⁸ Although it has mainly been studied at the level of the SFJ (Figure 4A and 4B) the same phenomenon may occur at the level of the saphenopopliteal junction (SPJ) after small saphenous vein (SSV) surgery, or after ligation of incompetent perforating veins or even after phlebectomies. The *Vein Term* Transatlantic Interdisciplinary Faculty recently accepted the term neovascularization defined as the *presence of multiple small tortuous veins in anatomic proximity to a previous intervention*.⁹ The duplex appearance of neovascularization at the junction has also been clearly described in the Union Internationale de Phlébologie (UIP) Consensus Document on duplex ultrasound reporting after varicose veins interven-

tions, published in 2011.¹⁰ According to this document an alternative, more purely sonographic descriptive term may equally be used instead of neovascularization namely *groin varicose network* at the SFJ or *popliteal fossa varicose network* at the SPJ.

Pathophysiology of varicose vein recurrence

Tactical and technical failure

The pathophysiology of varicose vein recurrence due to tactical and technical failure is rather obvious. If the wrong vein has been treated, incompetence may persist in the untreated vein and this may explain why varicose veins recur. Insufficient or incorrect surgery, *e.g.* too low ligation at the junction may result in an obvious cause of recurrence, if a long refluxing SFJ stump has been left.¹¹ Often a residual AASV forms the typical *pathway* of reflux from the incompetent SFJ to the thigh and leg. The same may occur after endovenous ablation, if the tip of the laser fiber or the radiofrequency catheter has not been positioned correctly, leaving too long a distance between the highest point of saphenous ablation and the refluxing SFJ or SPJ. Also in these cases the pathophysiology of recurrence is quite obvious. In some cases duplex ultrasound of the AASV reveals a particular anatomic situation, characterized by merging of the AASV with the GSV exactly at the SFJ (Figure 5). After any endovenous treatment of the GSV in such case, the AASV will be invariably included in the open stump.

Neovascularization and disease progression: interacting mechanisms

The past two decades, most of the research on recurrence after varicose vein treatment has focused on the potential pathophysiological mechanisms of neovascularization, which – together with progression of the disease – is considered to play an important role in recurrence, in particular after a classic surgical intervention.^{8,12} After EVTA, neovascularization at the SFJ or SPJ does not seem to play an important role in recurrence, as it is a very exceptional finding, with an incidence between 0-1%.^{5,13}

The research on neovascularization has mainly focused on the SFJ. After surgery, in particular after a so called *correct flush* SFJ ligation, various mechanisms may be involved inducing neovascularization: angiogenic stimulation in the stump endothelium, transnodal lymphovenous connections, dilation of small adventitial vessels, the vasa vasorum of the femoral vein, or disturbed venous drainage of the ligated tributaries of the SFJ, in particular in case of pelvic vein insufficiency. All of these

occur on a background of the normal wound-healing process, in which angiogenesis is an important component. However the surgical procedure itself cannot be the unique trigger for neovascularization, as this phenomenon does not occur after harvesting of the GSV in the groin in people without varicose veins. It has recently been postulated that venous pressure differences are an important triggering factor for the development of neovascularization and this certainly plays a role after an

intervention on the junction and/or on the main saphenous trunk.¹⁴

Angiogenic stimulation in the free endothelium of the saphenous stump

This has been claimed to be one of the most important triggers for the onset of the neovascularization process after surgical ligation and transection of the GSV in patients with varicose

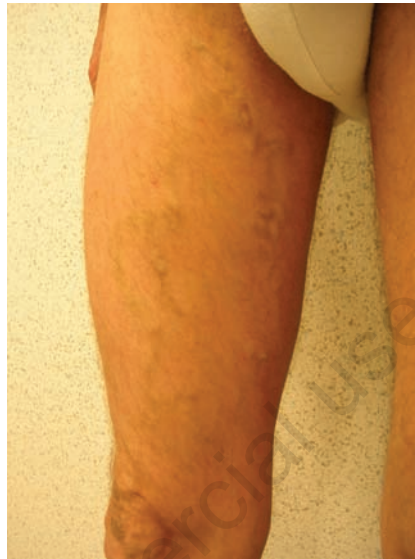

Figure 1. Recurrent varicose veins after high ligation and stripping of the above knee great saphenous vein.

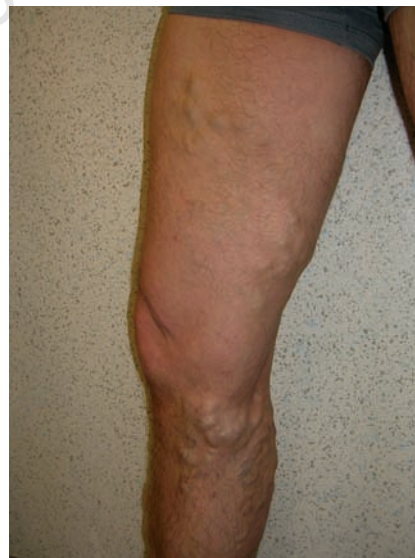

Figure 2. Extensive recurrent varicose veins 12 years after high ligation and stripping of the great saphenous vein; the anterior accessory saphenous vein is typically involved.

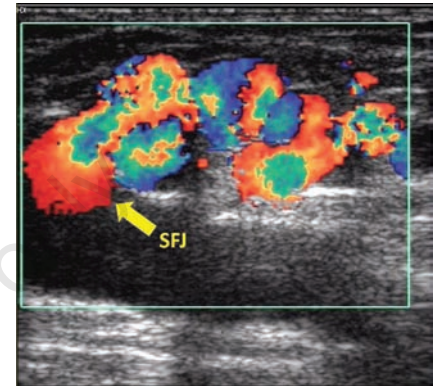


Figure 3. Longitudinal color duplex ultrasound image of the groin: saphenofemoral junction (SFJ) with neovascularization several years after high ligation and stripping.

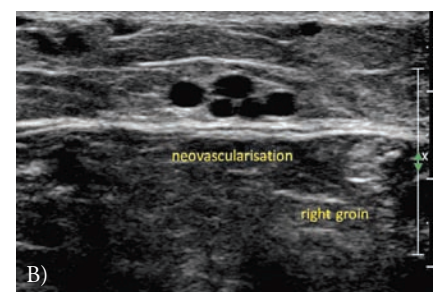
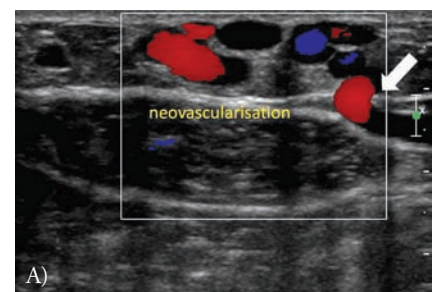


Figure 4. A) Color duplex image of the right groin: superficial tortuous varicose veins in connection with the saphenofemoral junction (not shown) are entering the saphenous compartment (arrow). B) Ultrasound shows tortuous veins, typically with multiple lumina, within the saphenous compartment.

veins. This might originate from hypoxia-induced activation of endothelial cells distal to the stump ligation, which could be mediated by different growth factors. Immunohistochemical staining of the intima with antibodies against vascular endothelial growth factor (VEGF) and its receptor (VEGF-R) showed both VEGF and VEGF-R were present in a higher percentage and had a higher expression in tissue samples of recurrent varicose veins with macroscopic neovascularization, compared to those of primary varicose veins and control veins.¹⁵ Another cause of stump-related neovascularization may be inflammation related to (absorbable) ligation or to the results of surgical dissection in the area around the SFJ or SPJ.

Transnodal lymphovenous connection

Lemasle *et al.*¹⁶ have focused on the important role of the lymph nodes close to the ligated GSV stump. Their hypothesis is that neovascularization is essentially the development of pre-existing venous vessels in these inguinal lymph nodes. This physiological lymph node vein network (LNVN) is normally thin and drains into the GSV and/or in the pelvic veins. Due to mechanical obstruction after crosssectomy, or due to the action of angiogenic factors and when pelvic vein insufficiency subsides, LNVN could become larger and incompetent. This could correspond with the tiny refluxing veins passing through the surrounding lymph nodes, often seen at postoperative duplex ultrasound of the groin (Figure 6A and 6B).¹⁰ Further study of the lymph nodes by means of high definition ultrasound before and after surgery at the SFJ may help to clarify the role of lymph nodes and lymphovenous connections in varicose vein recurrence.

Dilation of the vasa vasorum

Dilation of the vasa vasorum in the adventitia of the femoral vein could theoretically be responsible for new connections between the deep and superficial venous system. It is known that the very tiny veins of the vein wall are draining their blood directly into the lumen of the vein. It has been postulated that these tiny veins might enlarge, and become the *source* of reflux to the superficial veins. Unfortunately this issue has not been extensively studied.

Disturbed venous drainage of ligated tributaries

Disturbed venous drainage of tributaries of the SFJ that have been ligated has also been cited as a potential pathophysiological mechanism to explain recurrence in the groin. This can be even more frequent when the most cranial tributaries are refluxing preoperatively, due to pelvic vein insufficiency, and when these

tributaries are draining into the GSV trunk, in the presence of a competent terminal valve. Chandler *et al.*¹⁷ have suggested that neovascularization might also be driven by localized venous hypertension, or *frustrated venous drainage* secondary to ligation of tributaries as, for instance, the superficial epigastric vein (Figure 7) or pudendal veins. The latter might disturb normal venous drainage of the superficial tissues of the lower abdomen and pudendum. The idea that localized venous hypertension might be a trigger for neovascularization is supported by the finding that after endovenous treatment neovascularization seems to be very exceptional.^{5,13} Indeed, as EVTA usually starts 0.5-1 cm distally from the ostium of the superficial epigastric vein, normal drainage of this vein into the proximal GSV towards the common femoral vein can go on without any problem after endovenous treatment.

Comparable findings were reported in a retrospective study by Pittaluga *et al.*¹⁸ two years after limited surgery in the groin in addition to stripping of the refluxing trunks. Ligation of the GSV at a distance from the SFJ, preserving the proximal (non-refluxing) tributaries of the GSV resulted in a very low rate of postoperative neovascularization (only 1.8%), far lower than after *classic* SFJ ligation. Further prospective studies will be needed to elucidate this pathophysiological issue.

A joint venture?

Probably neovascularization at the SFJ as such cannot be the unique cause for the development of recurrent varicose veins after SFJ surgery including flush ligation. Something has to occur in the periphery as well, where a refluxing vein will try to make a *joint venture* with the neovascular veins at the SFJ and vice versa, by sending out some – not yet clearly understood – chemotactic signs, which will finally result in reconnection between peripheral veins and neovascular veins at the junction. In addition, differences in venous pressure may play a role in establishing these reconnections.¹⁴ In this way recurrence can appear *early* after the operation (sometimes already within the first or second year) if residual varicose veins or a refluxing GSV or AASV trunk have been left in place: prompt reconnection between these pathologic veins and neovascular veins could be quite evident in such situation.¹⁹ Recurrence developing *late* (several years) after the operation is more often primarily due to progression of the varicose disease. At the previous SFJ site neovascularization can play a secondary role in these cases. After a few years little by little new varicose veins develop in the leg and these can connect with neovascular veins in the groin, which at the long term can become larger and refluxing. This leads to the typical clinical picture of thigh or whole leg varicose vein recur-

rence several years after GSV surgery, being an end stage of this development (Figure 2).

At the level of the SPJ the pathophysiology of recurrent reflux has not been studied that extensively as at the level of the SFJ. After surgery, in particular when this has been limited to flush ligation at the SPJ, it is often seen that large tortuous neovascular vessels reconnect the SSV stump with the residual refluxing trunk. This can be typically recognized on duplex ultrasound and, in such case, the refluxing SSV can be easily treated by means of EVTA up to the level of the neovascular veins in the

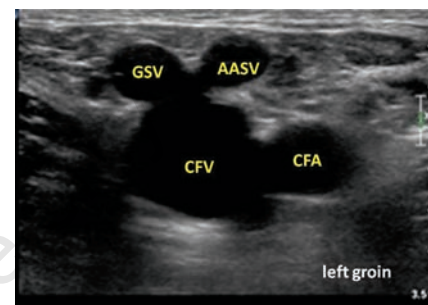


Figure 5. Typical presentation at the saphenofemoral junction in some cases: the anterior accessory saphenous vein (AASV) merges with the great saphenous vein (GSV). Transverse image of the left groin. CFV, common femoral vein; CFA, common femoral artery.

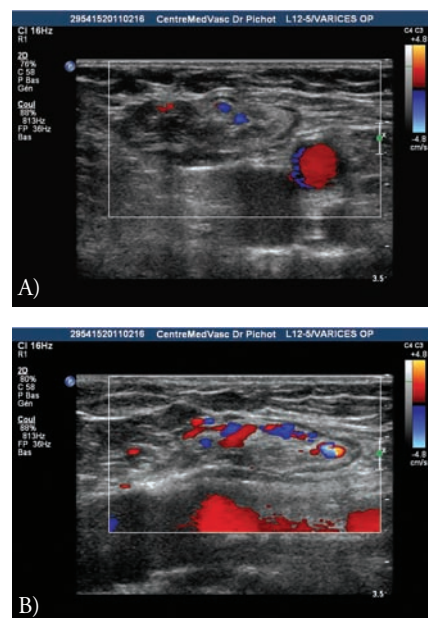


Figure 6. A) Transverse image of large lymph node with refluxing vein in a patient with extensive varicose vein recurrence. B) Longitudinal image of the same lymph node.

popliteal fossa or by means of ultrasound guided foam sclerotherapy. After ligation at the SPJ and stripping of the SSV to mid-calf level, neovascularization at the SPJ may result in formation of new tortuous veins running from the popliteal fossa to the calf (Figure 8). In case of clinical recurrence after SSV surgery or EVTA, another typical feature in the popliteal fossa is the presence of a popliteal fossa perforating vein, which may be related to progression of the disease (Figure 9). On duplex ultrasound it can be recognized from its typical location in front of the lateral condyle of the femur.¹⁰ Also, the preoperative presence of reflux during calf compression (systolic), or compression and release (systolic-diastolic) at the SPJ (found in 6% of cases of SPJ reflux in primary varicose veins)²⁰ has been advocated to play a role in the early recurrence at the popliteal fossa. Such systolic reflux is typically associated with obstructed outflow of the deep vein after previous deep vein thrombosis (DVT). Interestingly, a SPJ systolic reflux has been found in limbs without any sign of DVT. It is usually associated with a diverted flow from the popliteal vein towards a Giacomini vein or towards a thigh extension of the SSV. This hemodynamic abnormality is more likely due to an outflow problem in the popliteal-femoral axis or due to other specific conditions of venous anatomy. Any treatment of the SPJ (crosssectomy, sclerotherapy) may have a negative hemodynamic effect and may lead to early recurrence. Careful duplex ultrasound investigation of the deep venous system is mandatory before considering any intervention in these cases.

The role of the saphenofemoral junction (or saphenopopliteal junction) in recurrence following endovenous thermal ablation

It is remarkable to notice that the fate of the SFJ is not at all mentioned in the majority of studies looking at outcome after EVTA of the GSV. This explains why hard data about this issue are missing until now. Theivacumar *et al.*²¹ specifically studied the fate and clinical significance of persistent SFJ tributaries one year after endovenous laser ablation of the GSV. One or more patent tributaries were visible in 60% of legs. All were competent and they did not appear to have an adverse impact on clinical outcome at short-term after successful GSV ablation.

However, in some cases reflux may persist or reappear at the level of the SFJ after EVTA, even if the GSV trunk has been completely obliterated. This may particularly be the case when an incompetent AASV is involved.^{5,6,22} It represents either new incompetence, or failure of the pre-treatment duplex ultrasound to demonstrate reflux into the AASV, which has been left untreated.²²

Before as well as after EVTA treatment, the possible role of competence or incompetence of the terminal valve and the preterminal valve of the GSV should be studied more carefully. Indeed, it has been shown that the GSV trunk is smaller in presence of a competent terminal valve, and larger when the terminal valve is incompetent.²³ Also, haemodynamics of the SFJ may be different in case of incompetence or absence of the proximal femoral valve (above the SFJ) and this may influence outcome after endovenous treatment of the GSV.²⁴

As already mentioned previously, new reflux at the SFJ due to neovascularization shortly after EVTA is very exceptional and may be the result of vein wall perforation and/or hematoma formation in these rare cases.¹³

Up until now, only a few randomized trials, comparing EVTA with surgery, have investigated the incidence of new reflux at the SFJ. Just very recently the two year results of the

German RELACS-study have been published.²⁵ In this study, duplex-detected reflux at the SFJ appeared to occur significantly more frequently after endovenous laser ablation (17.8%) than after high ligation and stripping under tumescent anesthesia (1.3%). In the surgical group of this study a particular technique was used to mitigate the effect of neovascularization after high ligation at the SFJ, consisting of invagination of the GSV stump with a non-absorbable suture. This might explain somehow the low incidence of postoperative recurrent reflux at the SFJ. Moreover, all procedures were performed under local tumescent anesthesia, which facilitates dissection at the SFJ and minimizes blood loss. It may be hypothesized that both these factors reduced surgical trauma and hematoma formation, and hence the incidence of neovascularization.²⁵

The importance of reporting not only the findings at the level of the ablated trunk but also

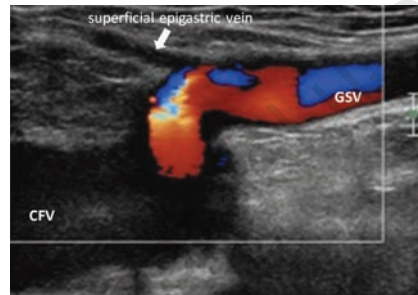


Figure 7. Longitudinal duplex scan of the saphenofemoral junction, clearly showing the superficial epigastric vein. GSV, great saphenous vein; CFV, common femoral vein.

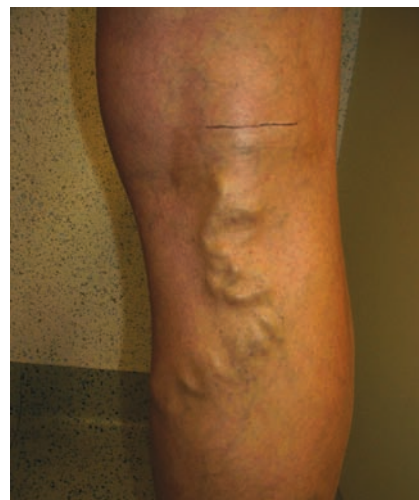

Figure 8. Recurrent varicose veins 10 years after high ligation and stripping of the small saphenous vein – the black line indicates the site of the previous incision in the popliteal fossa.

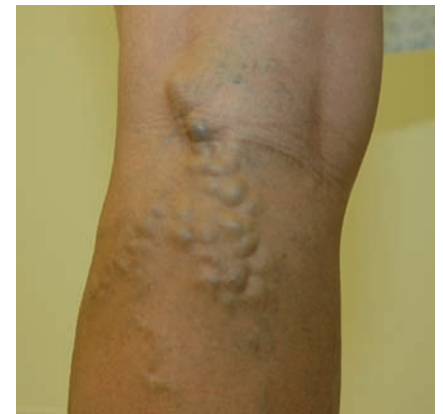

Figure 9. Incompetent popliteal fossa perforating vein.

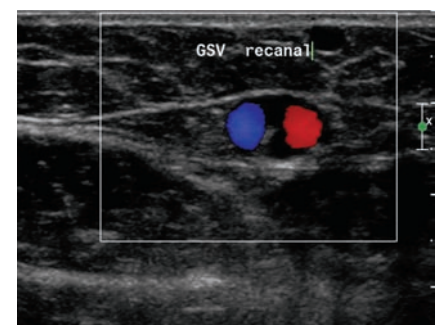


Figure 10. Transverse duplex image at mid thigh: recanalization of the great saphenous (GSV) vein 5 years after endovenous laser ablation; reflux is present at the saphenofemoral junction and continues along the thigh in the recanalized GSV.

at the SFJ or SPJ after endovenous treatment has been extensively highlighted in the recent UIP Consensus Document on duplex evaluation after treatment.¹⁰ Persistence or re-appearance of reflux at the SFJ or SPJ and/or at the level of the saphenous stump after EVTA is always to be considered pathological. During serial follow-up it can be observed how the incompetent most cranial part of the GSV in the groin connects with recurrent thigh varicosities, even if the main trunk is completely obliterated. In case of partial or complete recanalization of the GSV after EVTA, reflux may of course be transmitted from the SFJ directly to the recanalized GSV trunk (Figure 10). The same may occur at the level of the SPJ and SSV. More studies looking at the fate of the SFJ (or SPJ) after different treatment forms are certainly needed to further clarify its role in recurrence at the long-term.

Constitutional risk factors

In addition to all the above-mentioned pathophysiological mechanisms, constitutional risk factors, which could potentially enhance the tendency to recurrence, should also be further examined. The importance of risk factors such as female gender, left sided disease, associated deep vein incompetence, severe chronic venous disease (C4-6 of the CEAP classification), obesity, subsequent pregnancies after surgery, which have all been claimed to promote recurrence, should be prospectively studied.

Conclusions

Our understanding of the etiology and pathophysiology of varicose vein recurrence has grown considerably during the last decades. Continuous education and in particular hands-on training in duplex ultrasound and duplex-guided procedures may further reduce the impact of both tactical and technical failure. However, progression of the disease, with or without associated neovascularization, remains a problem for all physicians involved in varicose vein treatment, as well as for their patients. Properly designed prospective studies, with adequate preoperative duplex investigation and long-term follow-up, carefully studying the fate of the SFJ and SPJ after different forms of varicose vein treatment, are still needed.

References

- van Rij AM, Jiang P, Solomon C, et al. Recurrence after varicose vein surgery: A prospective long-term clinical study with duplex ultrasound scanning and air plethysmography. *J Vasc Surg* 2003;38:935-43
- Kostas T, Ioannou CV, Touloupakis E, et al. Recurrent varicose veins after surgery: a new appraisal of a common and complex problem in vascular surgery. *Eur J Vasc Endovasc Surg* 2004;27:275-82.
- Merchant RF, Pichot O, Closure Study Group. Long-term outcomes of endovenous radiofrequency obliteration of saphenous reflux as a treatment for superficial venous insufficiency. *J Vasc Surg* 2005;42:502-9.
- Proebstle TM, Alm J, Göckeritz O, et al. Three-year European follow-up of endovenous radiofrequency-powered segmental thermal ablation of the great saphenous vein with or without treatment of calf varicosities. *J Vasc Surg* 2011;54:146-52.
- Disselhof BC, der Kinderen DJ, Kelder JC, Moll FL. Five-year results of a randomised clinical trial of endovenous laser ablation of the great saphenous vein with and without ligation of the saphenofemoral junction. *Eur J Vasc Endovasc Surg* 2011;41:685-90.
- Rasmussen LH, Bjoern L, Lawaetz M, et al. Randomised clinical trial comparing endovenous laser ablation with stripping of the great saphenous vein: clinical outcome and recurrence after 2 years. *Eur J Vasc Endovasc Surg* 2010;39:630-5.
- Gough M. Satisfactory results with endovenous laser ablation 6.5 years after treatment. Available from: <http://www.cvascul.com/vn-venous-news>
- De Maeseneer MGR. The role of postoperative neovascularization in recurrence of varicose veins: from historical background to today's evidence. *Acta Chir Belg* 2004;104:283-9.
- Eklöf B, Perrin M, Delis KT, et al. Updated terminology of chronic venous disorders: The VEIN-TERM transatlantic interdisciplinary document. *J Vasc Surg* 2009;49:498-501.
- De Maeseneer M, Pichot O, Cavezzi A, et al. Duplex ultrasound investigation of the veins of the lower limbs after treatment for varicose veins – UIP consensus document. *Eur J Vasc Endovasc Surg* 2011;42:89-102.
- Geier B, Stücker M, Hummel T, et al. Residual stumps associated with inguinal varicose recurrences: a multicenter study. *Eur J Vasc Endovasc Surg* 2008;36:207-10.
- van Rij AM, Jones GT, Hill GB, Jiang P. Neovascularization and recurrent varicose veins: more histologic and ultrasound evidence. *J Vasc Surg* 2004;40:296-302.
- Pichot O, Kabnick LS, Creton D, et al. Duplex ultrasound findings two years after great saphenous vein radiofrequency endovenous obliteration. *J Vasc Surg* 2004;39:189-95.
- Recek C. Venous pressure gradients in the lower extremity and the hemodynamic consequences. *Vasa* 2010;39:292-7.
- Rewerk S, Noppeney T, Winkler M, et al. Pathogenesis of primary and recurrent varicose veins at the sapheno-femoral junction. The role of VEGF and VEGF-receptor. *Phlébologie* 2007;36:137-42. [Article in German].
- Lemasle P, Lefebvre-Vilardebo M, Uhl JF, et al. Postoperative recurrence of varices: what if inguinal neovascularization was nothing more than the development of a pre-existing network? *Phlébologie* 2009;62:42-8. [Article in French].
- Chandler JG, Pichot O, Sessa C, et al. Defining the role of extended saphenofemoral junction ligation: A prospective comparative study. *J Vasc Surg* 2000;32:941-53.
- Pittaluga P, Chastanet S, Guex JJ. Great saphenous vein stripping with preservation of sapheno-femoral confluence: Hemodynamic and clinical results. *J Vasc Surg* 2008;47:1300-5.
- Jones L, Braithwaite ED, Selwyn D, et al. Reprinted article "Neovascularization is the principal cause of varicose vein recurrence: results of a randomised trial of stripping the long saphenous vein". *Eur J Vasc Endovasc Surg* 2011;42 Suppl 1:S57-60.
- Cavezzi A, Tarabini C, Collura M, et al. Hemodynamics of sapheno-popliteal junction: colour-flow duplex investigation. *Phlébologie* 2002;55:309-16. [Article in French].
- Theivacumar NS, Dellagrammaticas D, Beale RJ, et al. Fate and clinical significance of saphenofemoral junction tributaries following endovenous laser ablation of great saphenous vein. *Br J Surg* 2007;94:722-5.
- Theivacumar NS, Darwood R, Gough MJ. Neovascularization and recurrence 2 years after varicose vein treatment for saphenofemoral and great saphenous vein reflux: A comparison of surgery and endovenous laser ablation. *Eur J Vasc Endovasc Surg* 2009;38:203-7.
- Cappelli M, Molino Lova R, Ermini S, Zamboni P. Hemodynamics of the sapheno-femoral junction. Patterns of reflux and their clinical implications. *Int Angiol* 2004;23:25-8.
- Capelli M, Molino Lova R, Ermini S, et al. Hemodynamics of the sapheno-femoral complex: an operational diagnosis of proximal femoral valve function. *Int Angiol* 2006;25:356-60.
- Rass K, Frings N, Glowacki P, et al. Comparable effectiveness of endovenous laser ablation and high ligation with stripping of the great saphenous vein. Two-year results of a randomized clinical trial (RELACS study). *Arch Dermatol* 2012;148:49-58.